



PATIENT

Mistletoe Rothman

PRESENTING CLINICAL SIGNS

History: Vomiting for 4-5 days. Normal appetite, normal BMs No current meds

Abnormal PE/Chem/CBC/UA Results: SDMA 15, CK 539

SPECIES

Feline

ULTRASONOGRAPHIC EXAMINATION OF THE ABDOMEN

Urinary System

The urinary bladder, trigone, and pelvic urethra are normal in thickness and the mucosal surface is smooth. The bladder lumen is mildly distended. Luminal contents are mostly anechoic. No masses, inflammatory changes or calculi are observed. Ureteral papillae and visualized portion of the proximal urethra, visible to a depth of 2 cm, are normal.

BREED

Domestic Shorthair

SEX

Female Spayed

The left kidney is normal size (4.47 cm in length); normal shape and architecture with smooth peripheral margins. The cortex is mildly thickened and there is mild to moderate loss of corticomedullary distinction. There is no evidence of pyelectasia, nephroliths, infarcts or hydroureter. Renal vasculature is normal.

AGE

13 years

The right kidney is normal size (4.41 cm in length); normal shape and architecture with smooth peripheral margins. The cortex is mildly thickened and there is mild to moderate loss of corticomedullary distinction. There is no evidence of pyelectasia, nephroliths, infarcts or hydroureter. Renal vasculature is normal.

WEIGHT

9.1 lbs.

Adrenal Glands

The left adrenal gland is normal size (0.42 cm width). Normal shape and glandular echogenicity. The phrenicoabdominal vein and surrounding vasculature are normal.

INTERPRETED BY

Andrea Nicastro, DVM,
Diplomate ACVIM
(Small Animal Internal
Medicine)

The right adrenal gland is normal size (0.45 cm width). Normal shape and glandular echogenicity. The phrenicoabdominal vein and surrounding vasculature are normal.

IMAGING PERFORMED BY

Jessica Miller

Spleen

The spleen is normal in size (1.00 cm in width at the level of the hilus) with a normal capsular contour. There is appropriate echogenicity and echotexture. No focal lesions are observed. Splenic vasculature is normal.

HOSPITAL NAME

Milburn VH

Liver

The liver is subjectively normal in size with normal contours and structure. There is appropriate echogenicity and echotexture. No overt structural evidence of inflammatory, infiltrative, or regenerative pathology is evident. Vascular and biliary tracts are of normal volume with no evidence of congestion. No pathological hepatic lymphadenopathy observed. The gall bladder lumen is moderately distended. The wall is thin and smooth. Luminal contents are anechoic. The cystic and common bile ducts are normal/not seen.

REFERRING VET

Dr. Turowsky

Gastrointestinal

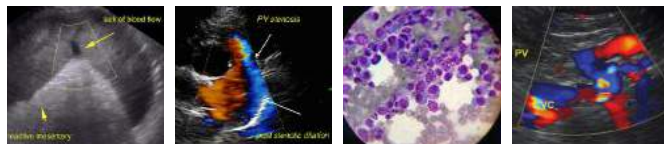
INVOICE

11814kk

The stomach and intestine are free of stasis and exhibit normal peristaltic activity. The gastric lumen is not distended. The gastric wall and pylorus are normal in thickness with a normal layering pattern. The pyloric outflow tract is patent. The small intestinal lumen is not dilated. The small intestinal wall thickness is normal with a normal layering pattern and appropriate mural detail. There is disruption in

DATE

9/14/21



PATIENT

Mistletoe Rothman

the normal 1:3 muscularis: mucosal ratio in most segments. Discreet masses are not identified. The ileocecal colic junction and colonic wall are normal. No obstructive disease is noted.

SPECIES

Feline

Pancreas

The region of the pancreas is isoechoic relative to surrounding omental fat. No obvious parenchymal abnormalities are observed. There is no evidence of regional inflammation or effusion.

BREED

Domestic Shorthair

Free Abdomen

There is no evidence of free fluid. The abdominal lymph nodes are normal/not visible.

SEX

Female Spayed

Primary Findings:

- Bowel pattern consistent with inflammatory bowel disease with potential for emerging lymphoma.

AGE

13 years

Secondary Findings:

- The bilateral renal changes are most consistent with chronic interstitial nephrosis/nephritis.

INTERPRETATION OF THE FINDINGS & FURTHER RECOMMENDATIONS

WEIGHT

9.1 lbs.

If the vomiting does not improve with supportive care, consider the following diagnostics/therapeutics:

1. Serum cobalamin, folate, PLI and TLI
2. Fecal evaluation for ova/Giardia
3. 6-week limited antigen diet trial to assess for food allergies
4. Consider heartworm antigen and antibody testing as heartworm disease can be a cause of chronic vomiting in cats.
5. Three-view thoracic radiographs are recommended to assess for occult esophageal disease.
6. If the above diagnostics/therapeutics are inconclusive, endoscopic or surgical gastrointestinal biopsies may be warranted.

INTERPRETED BY

Andrea Nicastro, DVM,
Diplomate ACVIM
(*Small Animal Internal
Medicine*)

IMAGING PERFORMED BY

Jessica Miller

HOSPITAL NAME

Milburn VH

REFERRING VET

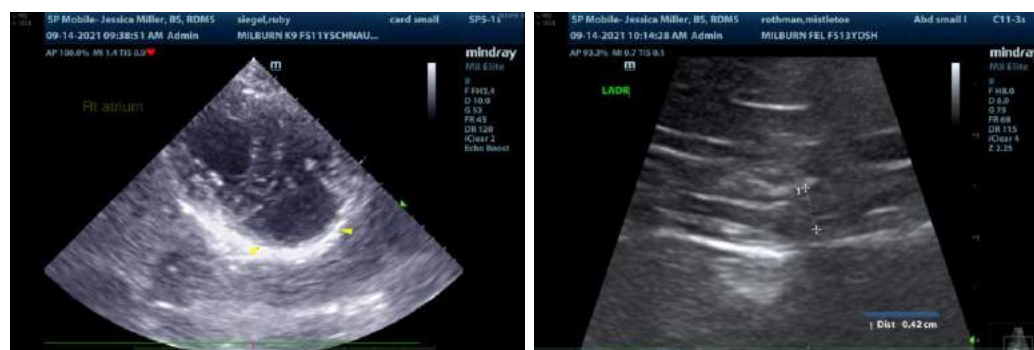
Dr. Turowsky

INVOICE

11814kk

DATE

9/14/21





PATIENT

Mistletoe Rothman

SPECIES

Feline

BREED

Domestic Shorthair

SEX

Female Spayed

AGE

13 years

WEIGHT

9.1 lbs.

INTERPRETED BY

Andrea Nicastro, DVM,
Diplomate ACVIM
(*Small Animal Internal
Medicine*)

**IMAGING
PERFORMED BY**

Jessica Miller

HOSPITAL NAME

Milburn VH

REFERRING VET

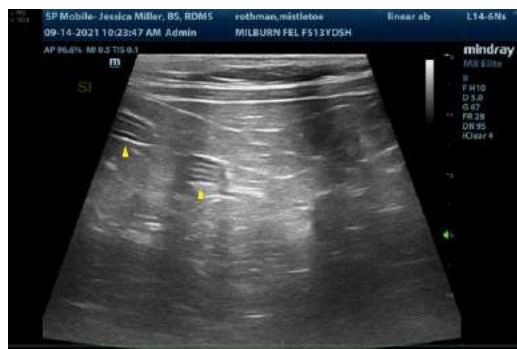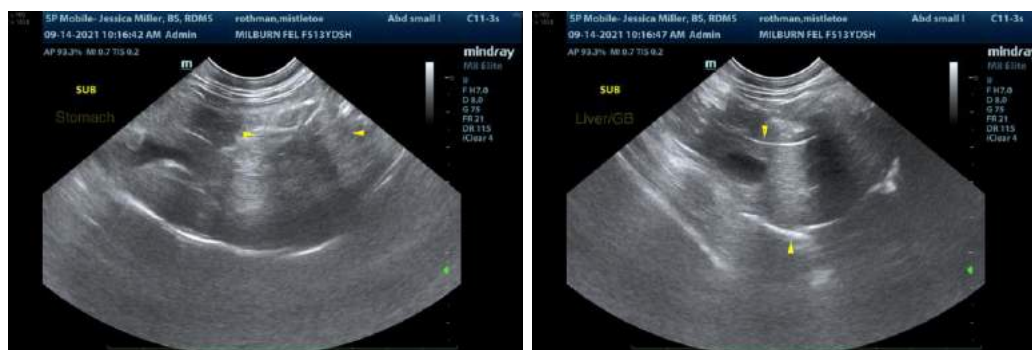
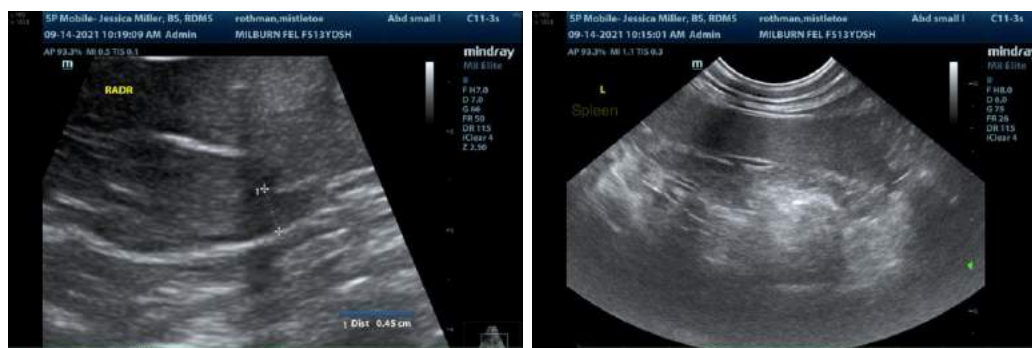
Dr. Turowsky

INVOICE

11814kk

DATE

9/14/21



The information and recommendations provided are based on the images presented by the referring veterinarian. No evaluation can be communicated regarding pathology that was not visible in the image/video clips provided.

Thank you for this referral. If the clinical or image interpretation does not parallel your findings or if I can be of any further assistance, please contact me.

Andrea Nicastro, DVM, Diplomate ACVIM (*Small Animal Internal Medicine*)
Andrea.nicastro@sonopath.com