

**DATE PRESENTING CLINICAL SIGNS**

9/13/22

One month history of abnormal forelimb gait, normal neuro consult, joint taps consistent with IMPA (no fever, effusion, joint pain). Screening for possible triggers.

PATIENT

Titan Murphy

Current Medications: Methocarbamol 500mg BID-TIE, Trazodone 200mg PRN, Cosequin, Prednisone 40mg once daily (just started)

Lab Results: 8/17 ALT 179, unremarkable CBC.

Date of Previous IntraPet Ultrasound: No previous.

Sedation: Patient sedated with Dexdomitor & Torbugesic.

SPECIES

Canine

Stat Report: Not requested.

Imaging Performed By: Andi Parkinson, BS, RDMS.

BREED

Boxer

ULTRASONOGRAPHIC EXAMINATION OF THE ABDOMEN**Urinary System**

The urinary bladder wall is normal in thickness and the mucosal surface is smooth. The bladder lumen is moderately distended with anechoic urine. No masses, inflammatory changes or calculi are observed. Ureteral papillae and visualized portion of the proximal urethra, visible to a depth of 2 cm, are normal.

SEX

Male, neutered

AGE

3/14/2016

The prostate is normal in size (1.03 cm in width) and shape. Parenchyma is homogenous. The prostatic urethra appears normal without evidence of dilation or obstruction.

WEIGHT

27.5 kg.

The left kidney is normal size (7.27 cm in length); normal shape and architecture with smooth peripheral margins. There is a normal 1:3 cortex to medulla ratio with minimal loss of corticomedullary distinction. Hyperechoic medullary band is observed adjacent to the corticomedullary junction. There is no evidence of pyelectasia, nephroliths, infarcts or hydroureter.

INTERPRETED BY

Andrea Nicastro, DVM,
 Diplomate ACVIM
 (Small Animal Internal
 Medicine)

The right kidney is normal size (7.96 cm in length); normal shape and architecture with smooth peripheral margins. There is a normal 1:3 cortex to medulla ratio with minimal loss of corticomedullary distinction. There is no evidence of pyelectasia, nephroliths, infarcts or hydroureter.

HOSPITAL NAME

Nexus VS

Adrenal Glands

The left adrenal gland is normal size (0.54 cm at caudal pole) (2.19 cm in length); normal shape; homogenous parenchyma. The glandular echogenicity and detail are unremarkable. Capsule, cortex, and medullary definition are normal. The phrenicoabdominal vein and surrounding vasculature are normal.

REFERRING VET

Dr. Steele

The right adrenal gland is normal size (0.60 cm at cranial pole) (0.46 cm at caudal pole) (2.96 cm in length); normal shape; homogenous parenchyma. The glandular echogenicity and detail are unremarkable. Capsule, cortex, and medullary definition are normal. The phrenicoabdominal vein and surrounding vasculature are normal.

INVOICE

13947

Spleen

The spleen is normal in size (1.46 cm in width at the level of the hilus) with a normal capsular contour. There is appropriate echogenicity and echotexture. No focal lesions are observed. Splenic vasculature is normal.

Liver

The liver is subjectively normal in size with normal contours and structure. There is appropriate echogenicity and echotexture. No overt structural evidence of inflammatory, infiltrative or regenerative pathology is evident. Vascular and biliary tracts are of normal volume with no evidence of congestion. No pathological hepatic lymphadenopathy observed. The gall bladder lumen is moderately distended. The wall is thin and smooth. Luminal contents are anechoic. The cystic and common bile ducts are normal/not seen.

Gastrointestinal

The gastric lumen is moderately distended with ingesta. The gastric wall and pylorus are normal in thickness with a normal layering pattern. The small intestinal lumen is segmentally gas distended. The small intestinal wall thickness is normal with a normal layering pattern and appropriate mural detail. Discreet masses are not identified. The colonic wall is normal. The colonic lumen contains shadowing fecal material. No obstructive disease is noted.

Pancreas

A portion of the pancreas is obscured by the gastric distention. In the visualized portions, no obvious abnormalities are seen.

Free Abdomen

The peritoneal cavity is normal. There is no evidence of inflammation or effusion. The abdominal lymph nodes are normal/not visible.

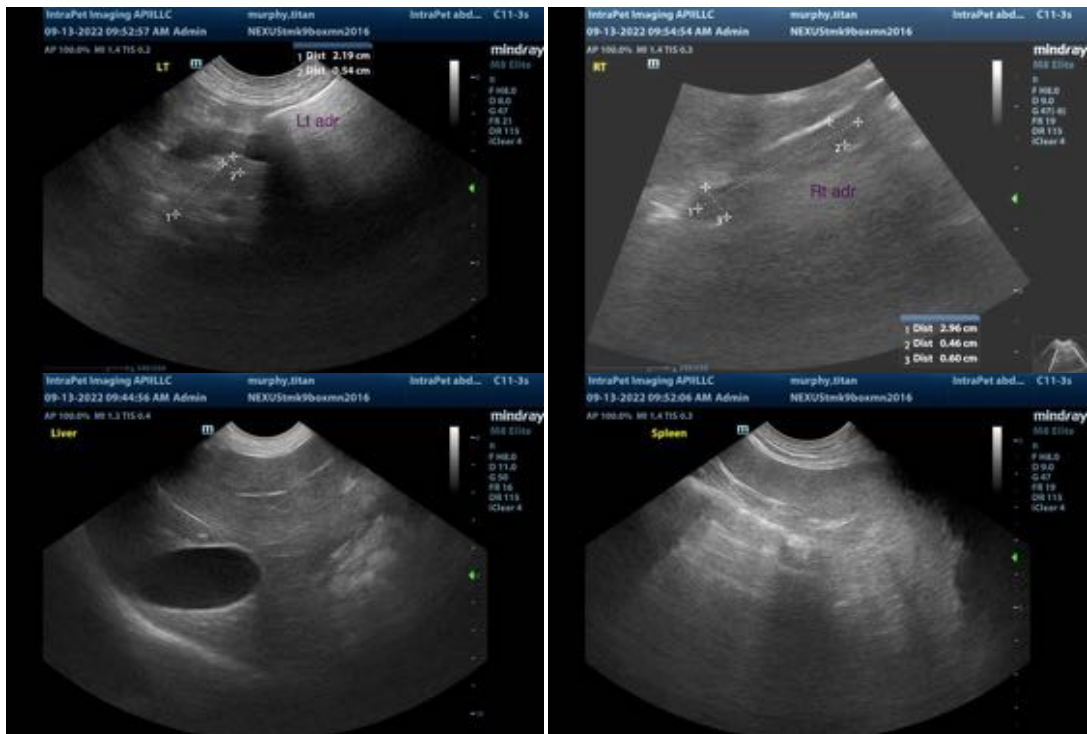
ULTRASONOGRAPHIC FINDINGS

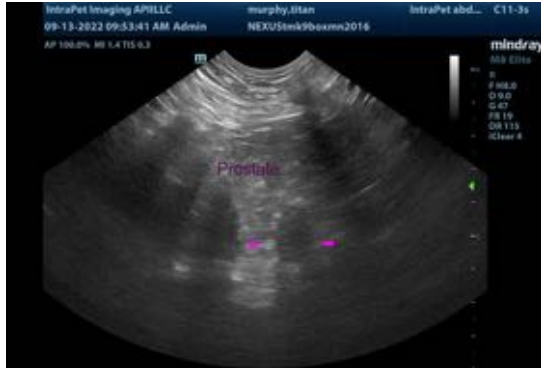- The hyperechoic medullary bands seen in both kidneys may be a normal variant for this patient or may represent a subclinical renal disease.

*There is no obvious evidence of neoplasia, abscesses/infections or other pathology in the abdomen that may be triggering the autoimmune disease in this patient.

INTERPRETATION OF THE FINDINGS & FURTHER RECOMMENDATIONS

Further diagnostic and treatment recommendations are to be implemented by Dr. Cara Steele.





The information and recommendations provided are based on the images presented by the referring veterinarian. No evaluation can be communicated regarding pathology that was not visible in the image/video clips provided.

Thank you for this referral. If the clinical or image interpretation does not parallel your findings or if I can be of any further assistance please contact me.

Andrea Nicastro, MPH, DVM, Diplomate DACVIM (Small Animal Internal Medicine)
info@SonoPath.com