

**DATE PRESENTING CLINICAL SIGNS**

9/13/21

History: Elevated ALT in young dog.

PATIENT

Ranger Saba

Current Medications: No current medications.

Lab Results: 8/28/21 ALT 455, AST 105.

Radiographs: Not provided by the veterinarian.

Date of Previous IntraPet Ultrasound: No previous IntraPet scans.

Sedation: Telazol administered prior to scan.

Stat Report: STAT report not requested by the veterinarian.

SPECIES

Canine

ULTRASONOGRAPHIC EXAMINATION OF THE ABDOMEN**BREED****Urinary System**

The urinary bladder, trigone, and pelvic urethra are normal in thickness and the mucosal surface is smooth. The bladder lumen is mildly distended with anechoic urine. No masses, inflammatory changes or calculi are observed. Ureteral papillae and visualized portion of the proximal urethra, visible to a depth of 2 cm, are normal.

SEX

Male, intact

The prostate is enlarged (1.88 cm in width) with a normal shape. The parenchyma is hyperechoic to slightly mottled in appearance. No distinct focal lesions are observed. The prostatic urethra is not overtly dilated.

AGE

9/6/2020

The left kidney is normal size (5.17 cm in length); normal shape and architecture with smooth peripheral margins. There is a normal 1:3 cortex to medulla ratio with normal corticomedullary distinction. There is no evidence of pyelectasia, nephroliths, infarcts or hydroureter.

WEIGHT

22.6 lbs.

The right kidney is normal size (5.42 cm in length); normal shape and architecture with smooth peripheral margins. There is a normal 1:3 cortex to medulla ratio with normal corticomedullary distinction. There is no evidence of pyelectasia, nephroliths, infarcts or hydroureter.

INTERPRETED BY

Andrea Nicastro, DVM,
 Diplomate ACVIM
 (Small Animal Internal
 Medicine)

Adrenal Glands

The left adrenal gland is normal in length (0.30 cm at cranial pole) (0.34 cm at caudal pole) (2.53 cm in length) with a flattened contour. The glandular echogenicity and detail are unremarkable. Capsule, cortex, and medullary definition are normal. The phrenicoabdominal vein and surrounding vasculature are normal.

The right adrenal gland is normal in length (0.46 cm at cranial pole) (0.36 cm at caudal pole) (2.21 cm in length) with a flattened contour. The glandular echogenicity and detail are unremarkable. Capsule, cortex, and medullary definition are normal. The phrenicoabdominal vein and surrounding vasculature are normal.

HOSPITAL NAME

Warm & Fuzzy
 Veterinary Clinic

Spleen

The spleen is normal in size (1.41 cm in width at the level of the hilus) with a normal capsular contour. There is appropriate echogenicity and echotexture. No focal lesions are observed. Splenic vasculature is normal.

REFERRING VET

Dr. Urie

Liver

The liver is subjectively normal in size with normal contours and structure. There is appropriate echogenicity and echotexture. No overt structural evidence of inflammatory, infiltrative or regenerative pathology is evident. Vascular and biliary tracts are of normal volume with no evidence of congestion. No pathological hepatic lymphadenopathy observed. The portal vein: caudal vena cava ratio is approximately 1:1. The gall bladder lumen is moderately distended. The wall is thin and smooth. Luminal contents are anechoic. The cystic and common bile ducts are normal/not seen.

INVOICE

12067

Gastrointestinal

The stomach and intestine are free of stasis and exhibit normal peristaltic activity. The gastric lumen is not distended. The gastric wall and pylorus are normal in thickness with a normal layering pattern. The pyloric

outflow tract is patent. The small intestinal lumen is not dilated. The small intestinal wall thickness is normal with a normal layering pattern and appropriate mural detail. Discreet masses are not identified. The colonic wall is normal. No obstructive disease is noted.

Pancreas

The right limb of the pancreas is visible with normal curvilinear peripheral contours. The parenchyma is largely hyperechoic relative to surrounding omental fat and slightly mottled in appearance. The pancreatic duct is visible but not overtly dilated. There is no evidence of peripancreatic inflammation or effusion.

Free Abdomen

The peritoneal cavity is normal. There is no evidence of inflammation or effusion. The abdominal lymph nodes are normal/not visible.

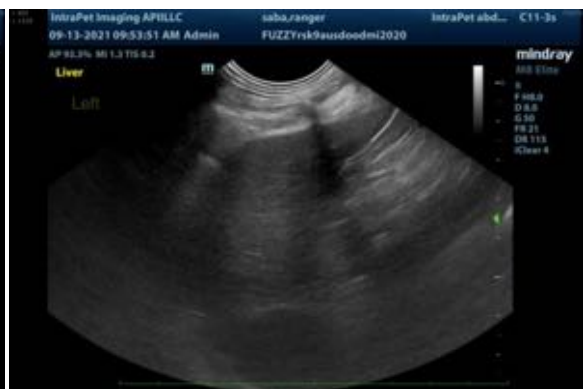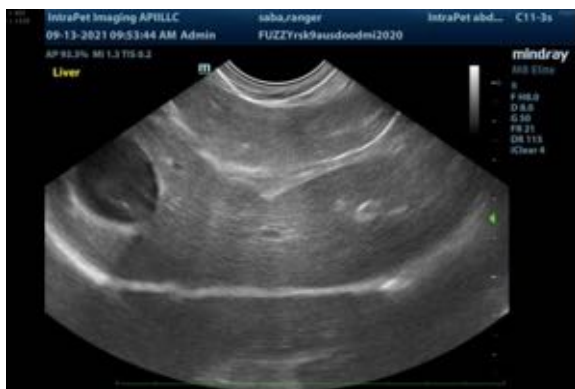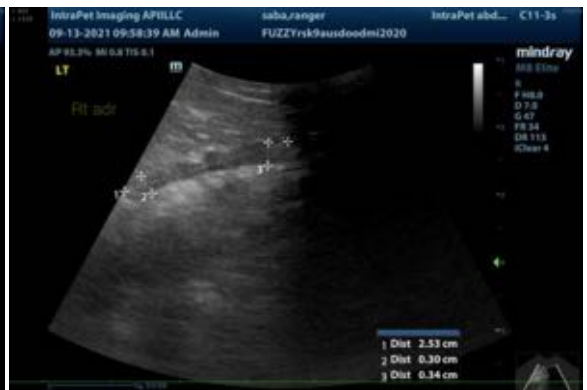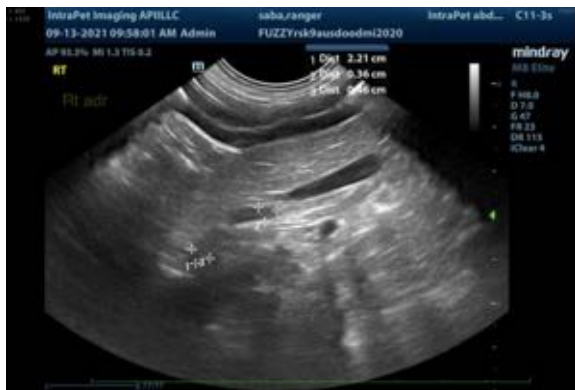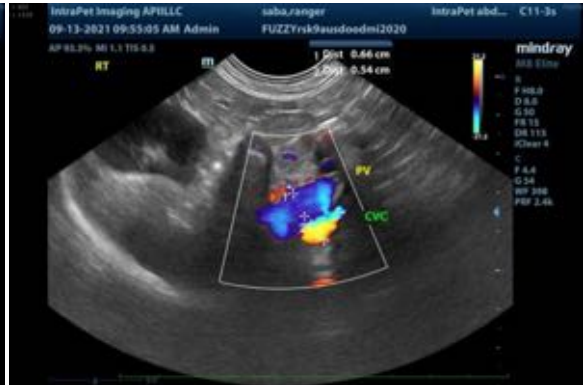
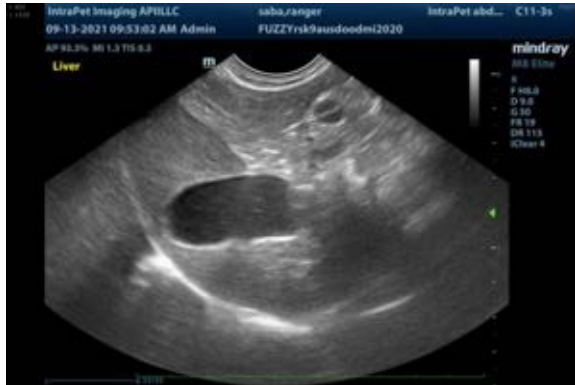ULTRASONOGRAPHIC FINDINGS

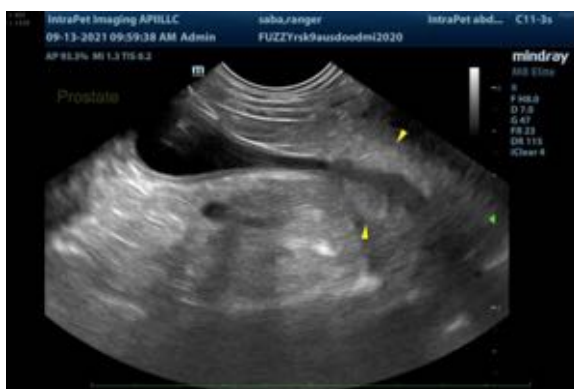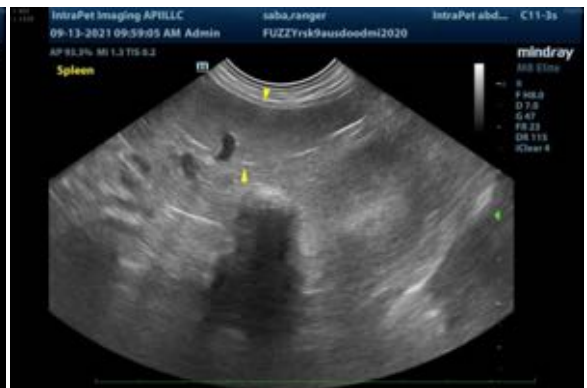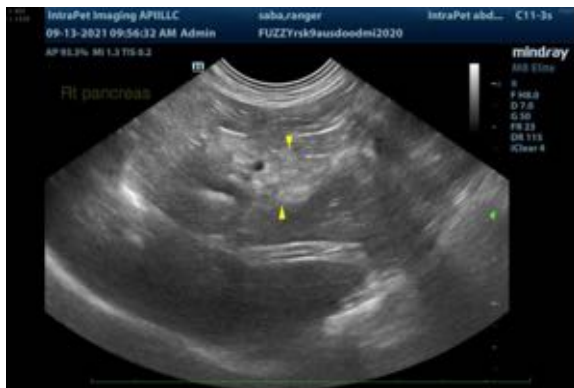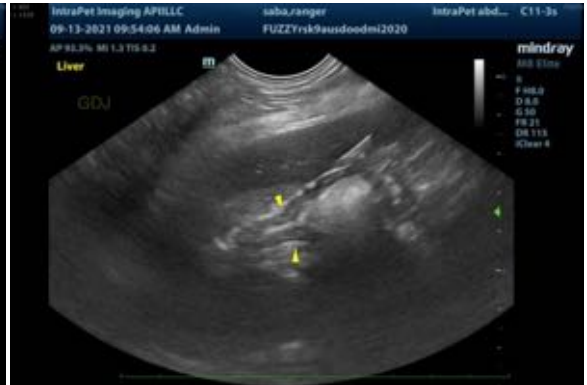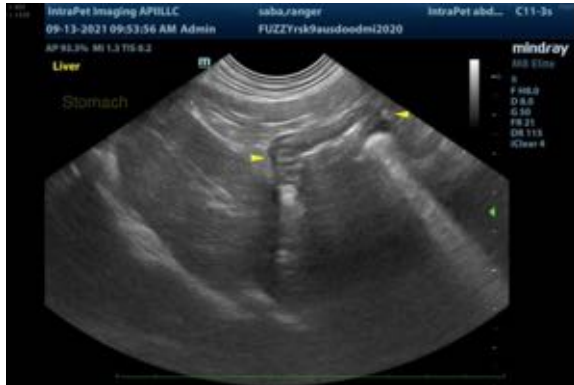- The pancreatic changes are suggestive of remodeling/fibrosis +/- concurrent mild inflammation.
- The flattened adrenal glands may be a normal variant or could be consistent with early atrophy (i.e., secondary to hypoadrenocorticism).

*An obvious cause for the patient's elevated ALT is not identified in this study. Considerations include inflammatory/immune mediated disease, hepatotoxicosis (i.e., copper), reactive hepatopathy, intrahepatic shunt, emerging neoplasia (unlikely), other.

INTERPRETATION OF THE FINDINGS & FURTHER RECOMMENDATIONS

- Pre- and post-prandial serum bile acids can be assessed to evaluate for hepatic dysfunction.
- Cytologic evaluation of the liver should be considered in this patient if clotting status is appropriate. A fine needle aspirate using a 25-gauge needle is recommended. If cytologic evaluation is inconclusive, consider a surgical liver biopsy with aerobic and anaerobic bile cultures and acquisition of additional hepatic tissue samples for copper quantitation.
- If a conservative approach is desired, consider empirical treatment for bacterial cholangiohepatitis (amoxicillin-clavulanic acid, Denamarin Advanced). If no improvement in the liver values is seen within 7-10 days of initiating therapy, antibiotics should be discontinued and hepatic tissue sampling reconsidered. If liver values improve, continue therapy for at least 4-6 weeks and 1 week beyond normalization of the liver values.
- Consider Leptospirosis testing (i.e., blood and urine PCR, serology).





The information and recommendations provided are based on the images presented by the referring veterinarian. No evaluation can be communicated regarding pathology that was not visible in the image/video clips provided.

Thank you for this referral. If the clinical or image interpretation does not parallel your findings or if I can be of any further assistance please contact me.

Andrea Nicastro, DVM, Diplomate ACVIM (*Small Animal Internal Medicine*)
Andrea.nicastro@sonopath.com

