

**DATE PRESENTING CLINICAL SIGNS**

9/13/21 History: Ongoing urination problems. Chronic infections.

**PATIENT** Date of Previous IntraPet Ultrasound: No previous IntraPet scans.

Buggie Ogden Sedation: Not needed.

**SPECIES** Stat Report: Not requested.

Canine

**ULTRASONOGRAPHIC EXAMINATION OF THE ABDOMEN****BREED***Urinary System*

Japanese Chin Mix

The urinary bladder, trigone, and pelvic urethra are normal in thickness and the mucosal surface is smooth. The bladder lumen is moderately distended with mostly anechoic urine. No masses, inflammatory changes or calculi are observed. Ureteral papillae and visualized portion of the proximal urethra, visible to a depth of 2 cm, are normal.

**SEX**

Female Spayed

The left kidney is normal size (4.95 cm in length); normal shape and architecture with smooth peripheral margins. There is a normal 1:3 cortex to medulla ratio with normal corticomedullary distinction. There is no evidence of pyelectasia, nephroliths, infarcts or hydronephrosis. Renal vasculature is normal.

**AGE**

9/8/15

The right kidney is normal size (4.99 cm in length); normal shape and architecture with smooth peripheral margins. There is a normal 1:3 cortex to medulla ratio with normal corticomedullary distinction. There is no evidence of pyelectasia, nephroliths, infarcts or hydronephrosis. Renal vasculature is normal.

**WEIGHT**

19.6 lbs.

*Adrenal Glands*

The left adrenal gland is normal size (0.49 cm at cranial pole) (0.44 cm at caudal pole) (2.01 cm in length); normal shape; homogenous parenchyma. The glandular echogenicity and detail are unremarkable. Capsule, cortex, and medullary definition are normal. The phrenicoabdominal vein and surrounding vasculature are normal.

**INTERPRETED BY**

Andrea Nicastro, DVM,  
 Diplomate ACVIM  
 (Small Animal Internal  
 Medicine)

The right adrenal gland is normal size (0.47 cm at cranial pole) (0.45 cm at caudal pole) (2.17 cm in length); normal shape; homogenous parenchyma. The glandular echogenicity and detail are unremarkable. Capsule, cortex, and medullary definition are normal. The phrenicoabdominal vein and surrounding vasculature are normal.

**HOSPITAL NAME**

Animal Clinic of  
 Southgate

*Spleen*

The spleen is normal in size (1.13 cm in width at the level of the hilus) with a normal capsular contour. There is appropriate echogenicity and echotexture. No focal lesions are observed. Splenic vasculature is normal.

**REFERRING VET**

Dr. Alexander

*Liver*

The liver is subjectively normal in size with normal contours and structure. There is appropriate echogenicity and echotexture. No overt structural evidence of inflammatory, infiltrative, or regenerative pathology is evident. Vascular and biliary tracts are of normal volume with no evidence of congestion. No pathological hepatic lymphadenopathy observed. The gall bladder lumen is moderately distended. The wall is thin and smooth. Luminal contents are anechoic. The cystic and common bile ducts are normal/not seen.

**INVOICE**

11808kk

*Gastrointestinal*

The esophageal inlet is visible/prominent. The stomach and intestine are free of stasis and exhibit normal peristaltic activity. The gastric lumen is not distended. The gastric wall and pylorus are normal in thickness with a normal layering pattern. The pyloric outflow tract is patent. The small intestinal lumen is not

dilated. The small intestinal wall thickness is normal with a normal layering pattern and appropriate mural detail. Discreet masses are not identified. The colonic wall is normal. No obstructive disease is noted.

### ***Pancreas***

The region of the pancreas is isoechoic relative to surrounding omental fat. No obvious parenchymal abnormalities are observed. There is no evidence of regional inflammation or effusion.

### ***Free Abdomen***

The peritoneal cavity is normal. There is no evidence of inflammation or effusion. The abdominal lymph nodes are normal/not visible.

### ***Other***

A uterine stump is visible (0.41 cm in width). No obvious pathology is seen.

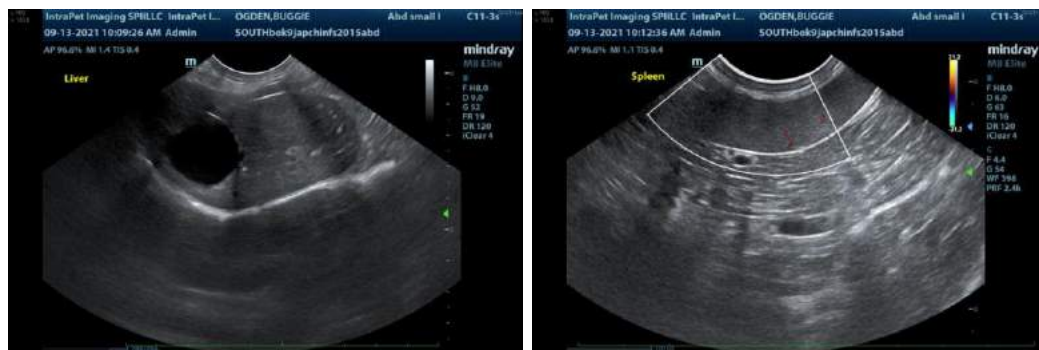
## **ULTRASONOGRAPHIC FINDINGS**

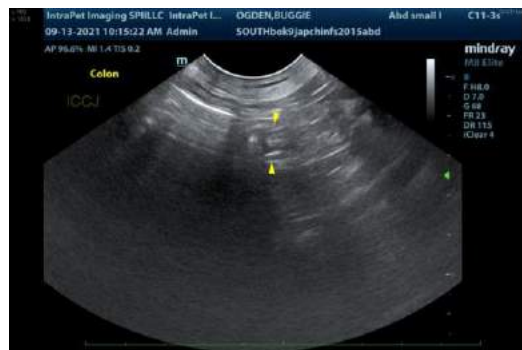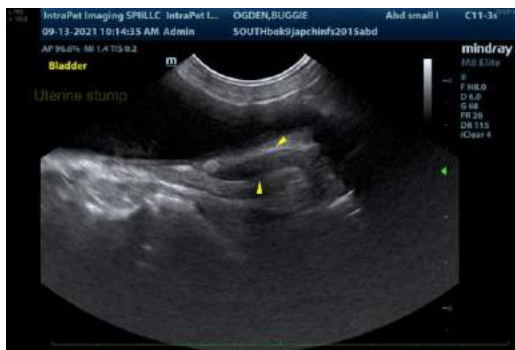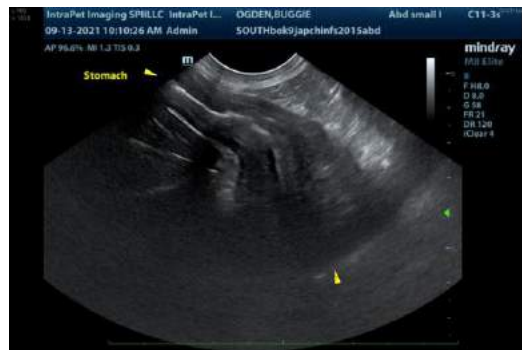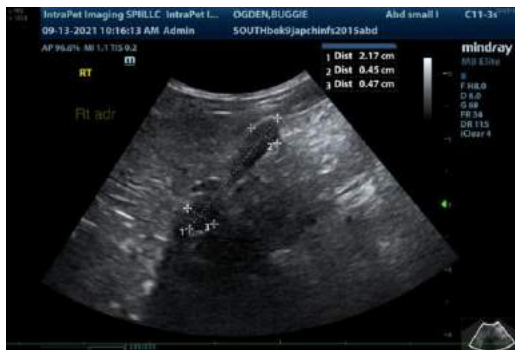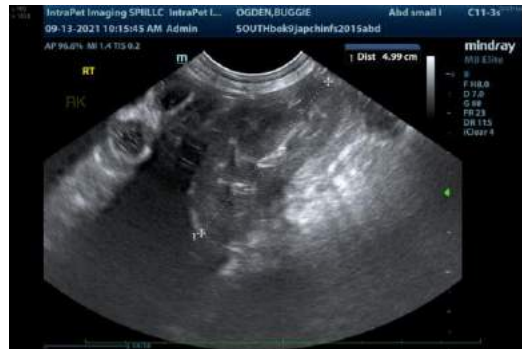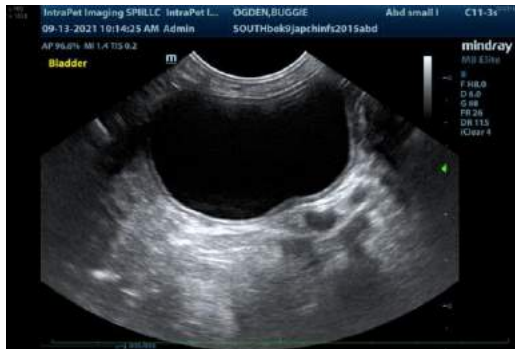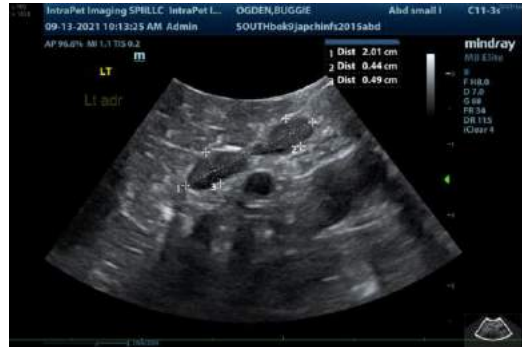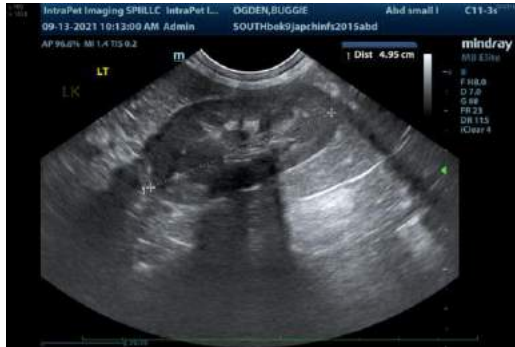- Visible uterine stump – incidental.
- The significance of the visible/prominent esophageal inlet is unclear, but it may be a normal variant for this patient or may be secondary to inflammatory disease (i.e., esophagitis). Correlation with clinical findings is recommended.

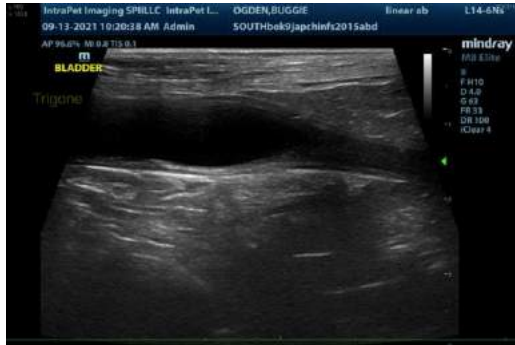\*\*An obvious cause for the patient’s urinary issues is not identified in this study.

## **INTERPRETATION OF THE FINDINGS & FURTHER RECOMMENDATIONS**

1. Baseline lab work including a CBC chemistry panel and urinalysis as well as a urine culture and sensitivity should be considered to assess overall metabolic function and to evaluate for a urinary tract infection, respectively.
2. If the patient is exhibiting evidence of urinary incontinence, further work up may be warranted.







The information and recommendations provided are based on the images presented by the referring veterinarian. No evaluation can be communicated regarding pathology that was not visible in the image/video clips provided.

Thank you for this referral. If the clinical or image interpretation does not parallel your findings or if I can be of any further assistance, please contact me.

Andrea Nicastro, DVM, Diplomate ACVIM (*Small Animal Internal Medicine*)  
Andrea.nicastro@sonopath.com