



PATIENT PRESENTING CLINICAL SIGNS

Hugo Keighan-Pizzi History: Ongoing hematuria. Has been on Amoxi-Clav

SPECIES

Abnormal PE/Chem/CBC/UA Results: USG 1.036 pH7 protein ++ bili ++ WBCs 2-5/hpf RBCs greater than 100/hpf Bacteria negative cystine crystals 1-5/hpf

Canine

ULTRASONOGRAPHIC EXAMINATION OF THE ABDOMEN

BREED

Urinary System

American Bulldog

The **urinary bladder** is mildly to moderately distended. The wall is thickened (up to 0.80 cm) and irregular, particularly in the region of the apex. Several cystic calculi are present within the lumen, one of the largest measuring 1.21 cm in diameter. A scant amount of suspended, echogenic debris is also observed within the lumen. The region of the trigone and the proximal urethra, visible to a depth of 2 cm, are normal.

SEX

Intact Male

The **prostate** is enlarged (5.39 cm in width) with irregular peripheral contours. Parenchyma is hyperechoic relative to surrounding omental fat and heterogenous in appearance. The prostatic urethra is not overtly dilated.

AGE

4.5 years

The **left kidney** is normal size (6.64 cm in length); normal shape and architecture with smooth peripheral margins. There is a normal 1:3 cortex to medulla ratio with moderate loss of corticomedullary distinction. There is no evidence of pyelectasia, nephroliths, infarcts or hydroureter. Renal vasculature is normal.

WEIGHT

34.6 kg

The **right kidney** is normal size (6.19 cm in length); normal shape and architecture with smooth peripheral margins. There is a normal 1:3 cortex to medulla ratio with mild loss of corticomedullary distinction. There is no evidence of pyelectasia, nephroliths, infarcts or hydroureter. Renal vasculature is normal.

INTERPRETED BY

Andrea Nicastro,
DVM, Diplomate ACVIM
(Small Animal Internal
Medicine)

Adrenal Glands

The **left adrenal gland** is normal size (0.55 cm at cranial pole) (0.52 cm at caudal pole) (2.87 cm in length); normal shape; homogenous parenchyma. The glandular echogenicity and detail are unremarkable. Capsule, cortex, and medullary definition are normal. The phrenicoabdominal vein and surrounding vasculature are normal.

IMAGING PERFORMED BY

Crystal Hill

The **right adrenal gland** is normal size (1.19 cm at cranial pole) (0.55 cm at caudal pole) (1.72 cm in length); normal shape; homogenous parenchyma. The glandular echogenicity and detail are unremarkable. Capsule, cortex, and medullary definition are normal. The phrenicoabdominal vein and surrounding vasculature are normal.

HOSPITAL NAME

Chippawa AH

Spleen

The **spleen** is normal in size (2.06 cm in width at the level of the hilus) with a normal capsular contour. There is appropriate echogenicity and echotexture. No focal lesions are observed. Splenic vasculature is normal.

REFERRING VET

Dowell/Van Leeuwen

Liver

The **liver** is subjectively normal in size with normal contours and structure. There is appropriate echogenicity and echotexture. No overt structural evidence of inflammatory, infiltrative, or regenerative pathology is evident. Vascular and biliary tracts are of normal volume with no evidence of congestion. No pathological hepatic lymphadenopathy observed.

INVOICE

11577

The **gall bladder** lumen is moderately distended. The wall is thin and smooth. Luminal contents are anechoic. The cystic and common bile ducts are normal/not seen.

DATE

9.1.22


PATIENT

Hugo Keighan-Pizzi

SPECIES

Canine

BREED

American Bulldog

SEX

Intact Male

AGE

4.5 years

WEIGHT

34.6 kg

INTERPRETED BY

 Andrea Nicastro,
 DVM, Diplomate ACVIM
 (Small Animal Internal
 Medicine)

**IMAGING
 PERFORMED BY**

Crystal Hill

HOSPITAL NAME

Chippawa AH

REFERRING VET

Dowell/Van Leeuwen

INVOICE

11577

DATE

9.1.22

Gastrointestinal

The **gastric lumen** is mildly distended with ingesta. The gastric wall is normal in thickness with a normal layering pattern. The small intestinal lumen is segmentally dilated with gas. The small intestinal wall thickness is normal with a normal layering pattern and appropriate mural detail. Discreet masses are not identified. The colonic wall is normal. There is no evidence of an obstructive pattern.

Pancreas

The region of the **pancreas** is isoechoic relative to surrounding omental fat. No obvious parenchymal abnormalities are observed. There is no evidence of regional inflammation or effusion.

Free Abdomen

The **peritoneal cavity** is normal. There is no evidence of inflammation or effusion. The abdominal **lymph nodes** are normal/not visible.

Other

The testicles are subjectively normal in size (the left measuring 3.90 x 2.51 cm; the right 4.03 x 2.73 cm) and symmetrical, with homogenous parenchyma. No obvious pathology is observed.

ULTRASONOGRAPHIC FINDINGS
Primary Findings

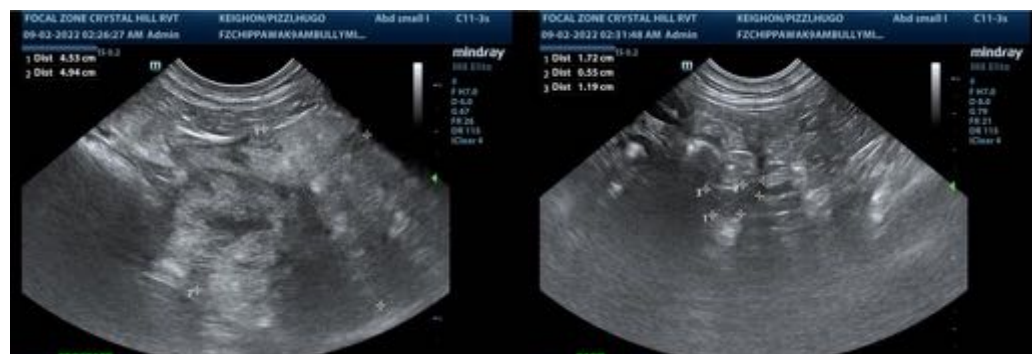
- Cystic calculi.
- The urinary bladder wall changes are consistent with cystitis.
- The prostate changes are consistent with benign prostatic hyperplasia. Concurrent bacterial prostatitis may also be present.

Secondary Findings

- Bilateral degenerative renal changes

INTERPRETATION OF THE FINDINGS & FURTHER RECOMMENDATIONS

A cystotomy with stone removal, analysis and culture is recommended, along with castration. If the cystic calculi are not to be removed at this time, an attempt at medical dissolution can be considered via a prescription urinary diet and broad-spectrum antibiotics. However, if the stone size has not changed within 4 weeks therapy, a cystotomy should be reconsidered.





PATIENT

Hugo Keighan-Pizzi

SPECIES

Canine

BREED

American Bulldog

SEX

Intact Male

AGE

4.5 years

WEIGHT

34.6 kg

INTERPRETED BY

Andrea Nicastro,
DVM, Diplomate ACVIM
(Small Animal Internal
Medicine)

**IMAGING
PERFORMED BY**

Crystal Hill

HOSPITAL NAME

Chippawa AH

REFERRING VET

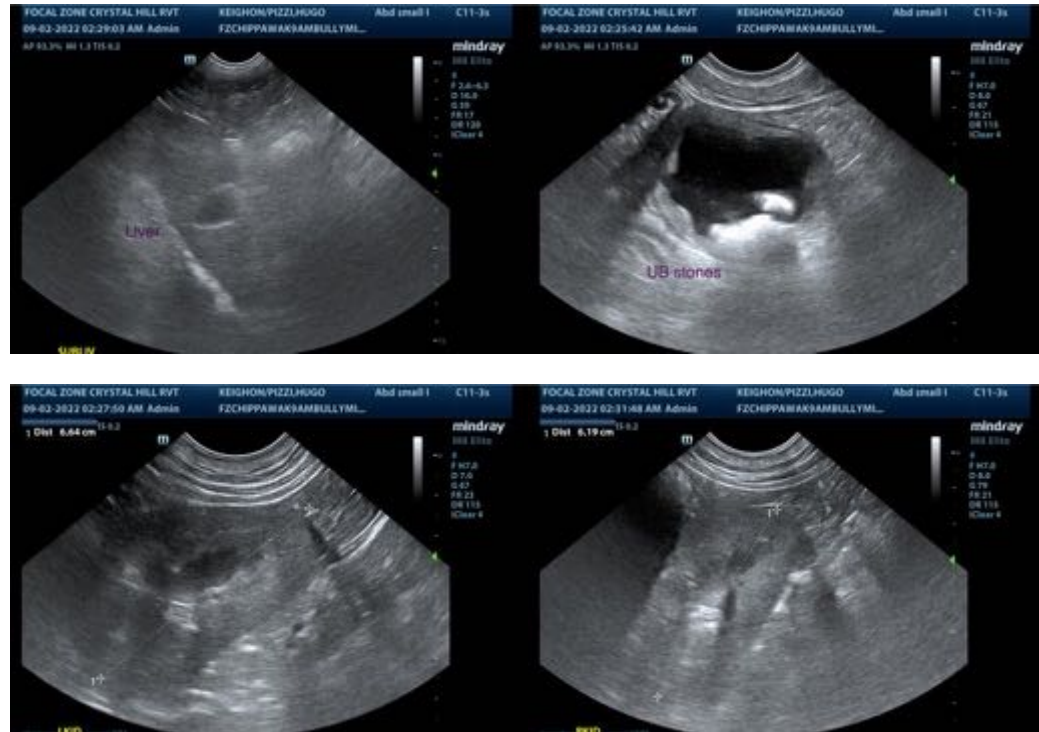
Dowell/Van Leeuwen

INVOICE

11577

DATE

9.1.22



The information and recommendations provided are based on the images presented by the referring veterinarian/sonographer. No evaluation can be communicated regarding pathology that was not visible in the image/video clips provided.

Thank you for this referral. If the clinical or image interpretation does not parallel your findings or if I can be of any further assistance, please contact me.

Andrea Nicastro, MPH, DVM, Diplomate DACVIM (Small Animal Internal Medicine)
info@SonoPath.com