



PATIENT PRESENTING CLINICAL SIGNS

Carmen Terry
114790

History: Carmen is a 14y 0m SF American Cocker Spaniel who presented on 9/1/2022 for further work up of lung nodules. The owner noticed this week that Carmen was panting more than usual. She has also been hyporexic and infrequently coughing. She seems to be moving slower today which prompted her visit to the emergency room.

SPECIES

Canine

Abnormal PE/Chem/CBC/UA Results: 8/30/22 - Seen by rDVM - PE - sinus arrhythmia, OD corneal pigmentation with gray color behind this, some neo-vasc present - Rlateral + VD CXR - focal opacities in left caudal lung area + right mdial/caudal lung lobe area - ECG - Rhythm ok - IOP - OS 22, OD 30 - Stain - negative - CBC - WBC 6.65(N), Lymph 0.69(L), Hct 43.39%(N), Plt 351(N) - Chem - ALP 313(H), Glob 2(L)

BREED

Cocker Spaniel

ULTRASONOGRAPHIC EXAMINATION OF THE ABDOMEN

SEX

Spayed Female

Urinary System

The **urinary bladder** is moderately distended with anechoic urine. The wall in the region of the apex is mildly thickened (up to 0.45 cm) with an irregular mucosal surface. The wall tapers to a normal thickness as it extends towards the cystourethral junction. No cystic calculi are observed. The region of the trigone and the proximal urethra, visible to a depth of 2 cm, are normal.

AGE

14 years

The **left kidney** is normal size (5.20 cm in length); normal shape and architecture with smooth peripheral margins. There is a normal 1:3 cortex to medulla ratio with mild loss of corticomedullary distinction. There is no evidence of pyelectasia, nephroliths, infarcts or hydronephrosis.

WEIGHT

11.8 kg

The **right kidney** is normal size (4.87 cm in length); normal shape and architecture with smooth peripheral margins. There is a normal 1:3 cortex to medulla ratio with mild loss of corticomedullary distinction. There is no evidence of pyelectasia, nephroliths, infarcts or hydronephrosis.

INTERPRETED BY

Andrea Nicastro,
DVM, Diplomate
ACVIM (Small Animal
Internal Medicine)

Adrenal Glands

In the region of the **left adrenal gland**, a mass effect (2.93 cm at cranial pole) (1.36 cm at caudal pole) (4.20 cm in length); is present. The gland is severely enlarged, with an irregular shape and heterogenous parenchyma with foci of mineralization. There is no obvious evidence vascular invasion.

IMAGING PERFORMED BY

Tom McNeill

The **right adrenal gland** is borderline small in size (0.42 cm at cranial pole) (0.38 cm at caudal pole); normal shape; homogenous parenchyma. The glandular echogenicity and detail are unremarkable. Capsule, cortex, and medullary definition are normal. The phrenicoabdominal vein and surrounding vasculature are normal.

HOSPITAL NAME

SVS Imaging CT

Spleen

The **spleen** is subjectively enlarged with a normal capsular contour. There is appropriate echogenicity and echotexture. Several, small hyperechoic nodules are observed throughout the organ. Splenic vasculature is normal.

REFERRING VET

WVRC- Dr. Witzel

Liver

The **liver** is prominent in size with slightly rounded peripheral contours. The parenchyma is isoechoic relative to the spleen and subtly heterogenous in appearance. No distinct focal lesions are observed. Hepatic vasculature and intrahepatic biliary tracts are of normal volume with no evidence of congestion.

INVOICE

11568

The **gall bladder** lumen is moderately distended. The wall is thin and smooth. A scant amount of gravity dependent, echogenic debris is observed within the lumen. The cystic and common bile ducts are normal/not seen.

DATE

9.1.22

**PATIENT**Carmen Terry
114790**SPECIES**

Canine

BREED

Cocker Spaniel

SEX

Spayed Female

AGE

14 years

WEIGHT

11.8 kg

INTERPRETED BYAndrea Nicastro,
DVM, Diplomate
ACVIM (Small Animal
Internal Medicine)**IMAGING
PERFORMED BY**

Tom McNeill

HOSPITAL NAME

SVS Imaging CT

REFERRING VET

WVRC- Dr. Witzel

INVOICE

11568

DATE

9.1.22

Gastrointestinal

The **stomach and intestine** are free of stasis and exhibit normal peristaltic activity. The gastric lumen is not distended. The gastric wall and pylorus are normal in thickness with a normal layering pattern. The pyloric outflow tract is patent. The small intestinal lumen is not dilated. The small intestinal wall thickness is normal with a normal layering pattern and appropriate mural detail. Discreet masses are not identified. The colonic wall is normal. There is no evidence of an obstructive pattern.

Pancreas

The region of the **pancreas** is isoechoic relative to surrounding omental fat. No obvious parenchymal abnormalities are observed. There is no evidence of regional inflammation or effusion.

Free Abdomen

Trace free fluid is observed. A 0.79 x 0.35 cm medial iliac **lymph node** is visualized. The node is normal in shape and echogenicity.

ULTRASONOGRAPHIC FINDINGS**Primary Findings**

- Left adrenal mass effect. Neoplasia (i.e., adenocarcinoma, pheochromocytoma) is considered likely with a lower possibility of a benign process.
- The small right adrenal gland may be secondary to atrophy resulting from a functional left adrenal tumor.

Secondary Findings

- The diffuse hepatic changes are non-specific and could be consistent with vacuolar hepatopathy, regenerative nodular hyperplasia, and/or age-related remodeling. Inflammatory and infiltrative disease are considered less likely.
- The hyperechoic splenic nodules trend toward the benign (i.e., myelolipomas) with a low possibility of emerging neoplasia.
- Minor bilateral degenerative renal changes
- The thickened urinary bladder wall region of the apex is suggestive of cystitis. However, correlation with the patient's clinical history and urinalysis findings is recommended.

INTERPRETATION OF THE FINDINGS & FURTHER RECOMMENDATIONS

To further evaluate for a functional left adrenal tumor, consider a low-dose dexamethasone suppression test and urine/blood catecholamine levels. A baseline blood pressure measurement is also recommended. However, if the lung nodules are thought to be pulmonary metastatic lesions, palliative care should be considered in lieu of aggressive diagnostics.



PATIENT

Carmen Terry
114790

SPECIES

Canine

BREED

Cocker Spaniel

SEX

Spayed Female

AGE

14 years

WEIGHT

11.8 kg

INTERPRETED BY

Andrea Nicastro,
DVM, Diplomate
ACVIM (Small Animal
Internal Medicine)

**IMAGING
PERFORMED BY**

Tom McNeill

HOSPITAL NAME

SVS Imaging CT

REFERRING VET

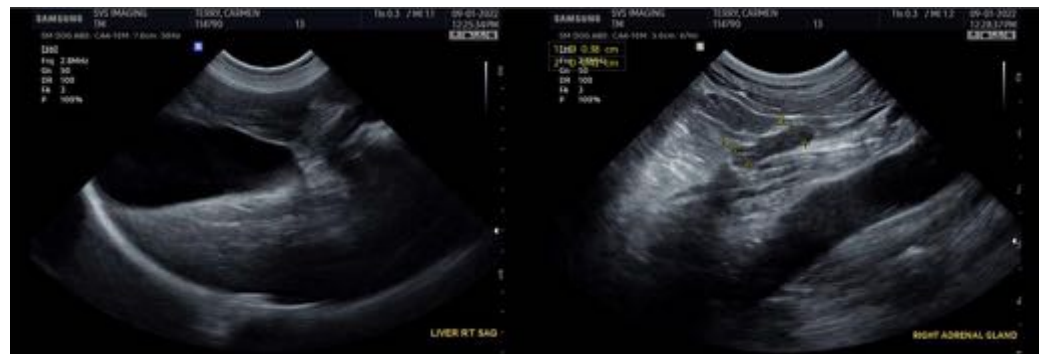
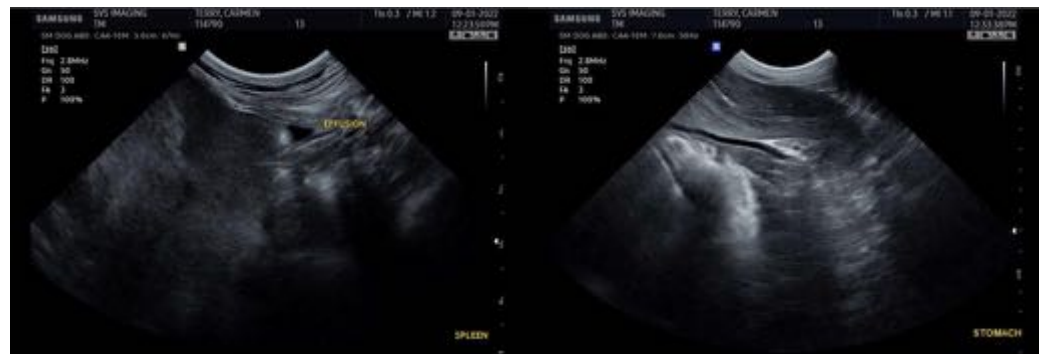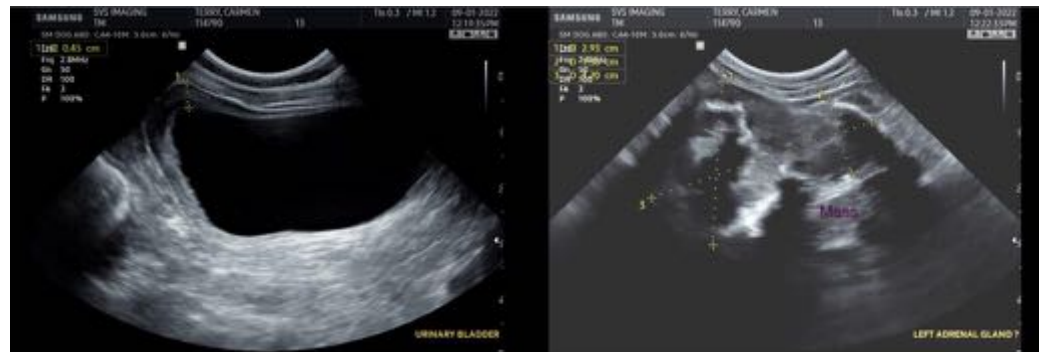WVRC- Dr. Witzel

INVOICE

11568

DATE

9.1.22



The information and recommendations provided are based on the images presented by the referring veterinarian/sonographer. No evaluation can be communicated regarding pathology that was not visible in the image/video clips provided.

Thank you for this referral. If the clinical or image interpretation does not parallel your findings or if I can be of any further assistance, please contact me.

Andrea Nicastro, MPH, DVM, Diplomate DACVIM (Small Animal Internal Medicine)
info@SonoPath.com