

**DATE PRESENTING CLINICAL SIGNS**

9/1/2021

History: Hx of chronic diarrhea nonresponsive to Metronidazole, Provable HP diet and Tylan. Per owner pet is eating normally.

**PATIENT**

Hershey Francis

Current Medications: Tylan Powder 5 grams - 1/4 tsp BID, Welactin Advanced - 2 scoops SID, TRP Tri-Cox - 1/2 chewable SID, 1-TDC - 1 cap SID, Dasuquin Advanced- 1 chew EOD. On rectal exam- right sided dorsal wall, mass effect.

Lab Results: CBC mild thrombocytosis, hypoalbuminemia, hypoglobulinemia

Radiographs: Not provided by the veterinarian.

**SPECIES**

Canine

Date of Previous IntraPet Ultrasound: No previous IntraPet scans.

Sedation: Not needed.

Stat Report: Not requested.

**BREED**

German shepherd

**ULTRASONOGRAPHIC EXAMINATION OF THE ABDOMEN****Urinary System****SEX**

Female, spayed

The urinary bladder is mildly distended. The wall is of appropriate thickness for the level of repletion. A scant amount of echogenic to mineralized debris is observed within the lumen. No distinct calculi are seen. The region of the trigone is normal.

**AGE**

3/5/2008

The left kidney is normal in size (5.06cm in length) with a normal shape, smooth peripheral margins and normal internal architecture. There is minimal loss of corticomedullary distinction. Several hyperechoic shadowing diverticular foci are observed. There is no evidence of pyelectasia, infarcts or hydronephrosis. Renal vasculature is normal.

**WEIGHT**

29 lbs.

The right kidney is normal size (5.39 cm in length); normal shape and architecture with smooth peripheral margins. There is a normal 1:3 cortex to medulla ratio with normal corticomedullary distinction. There is no evidence of pyelectasia, nephroliths, infarcts or hydroureter. Renal vasculature is normal.

**INTERPRETED BY**

Andrea Nicastro, DVM,  
 Diplomate ACVIM  
 (Small Animal Internal  
 Medicine)

**Adrenal Glands**

The left adrenal gland is upper limits of normal size (0.59 cm at cranial pole) (0.74 cm at caudal pole) (2.66 cm in length); normal shape; homogenous parenchyma. The glandular echogenicity and detail are unremarkable. Capsule, cortex, and medullary definition are normal. The phrenicoabdominal vein and surrounding vasculature are normal.

**HOSPITAL NAME**

Claws 'n Paws AH

The right adrenal gland is normal size (0.73 cm at cranial pole) (0.62 cm at caudal pole) (2.83 cm in length); normal shape; homogenous parenchyma. The glandular echogenicity and detail are unremarkable. Capsule, cortex, and medullary definition are normal. The phrenicoabdominal vein and surrounding vasculature are normal.

**REFERRING VET**

Dr. Sing

**Spleen**

The spleen is normal in size (1.55 cm in width at the level of the hilus) with a normal capsular contour. There is appropriate echogenicity and echotexture. No focal lesions are observed. Splenic vasculature is normal.

**INVOICE**

12001

**Liver**

The liver is subjectively normal in size with normal contours and structure. There is appropriate echogenicity and echotexture. No overt structural evidence of inflammatory, infiltrative or regenerative pathology is evident. Vascular and biliary tracts are of normal volume with no evidence of congestion. No pathological hepatic lymphadenopathy observed. The gall bladder lumen is moderately distended. The wall is thin and smooth. A scant amount of suspended echogenic debris is observed within the lumen. The cystic and common bile ducts are normal/not seen.

### ***Gastrointestinal***

The gastric lumen is minimally fluid distended. The gastric wall and pylorus are normal in thickness with a normal layering pattern. The small intestinal lumen is segmentally fluid distended (mild) and hypomotile. The small intestinal wall is normal to mildly thickened (up to 0.64 cm) with a normal layering pattern. There is evidence of mucosal speckling, fogging and striations in some segments. Discreet masses are not identified. The ileocecal colic junction is normal. The wall of the descending colon is thickened (up to 1.34 cm), more so in the distal most aspect. There is retention of the normal layering pattern proximally. However, there is questionable loss of the normal layering pattern at the distal aspect. No obstructive disease is noted.

### ***Pancreas***

The region of the pancreas is isoechoic relative to surrounding omental fat. No obvious parenchymal abnormalities are observed. There is no evidence of regional inflammation or effusion.

### ***Free Abdomen***

The mesentery throughout the abdomen is hyperechoic. A small amount of anechoic free fluid is visualized. The abdominal lymph nodes are normal/not visible.

## **ULTRASONOGRAPHIC FINDINGS**

### **Primary Findings:**

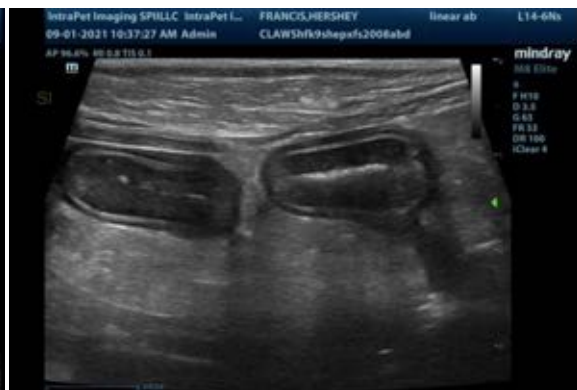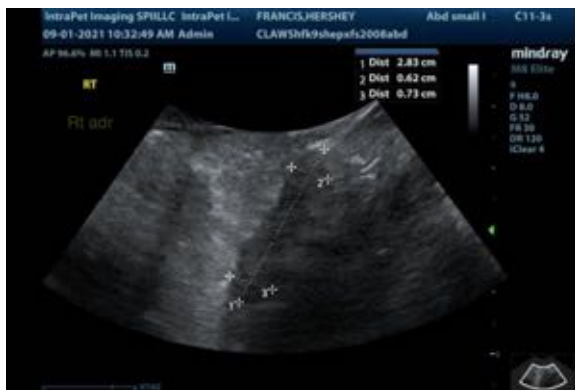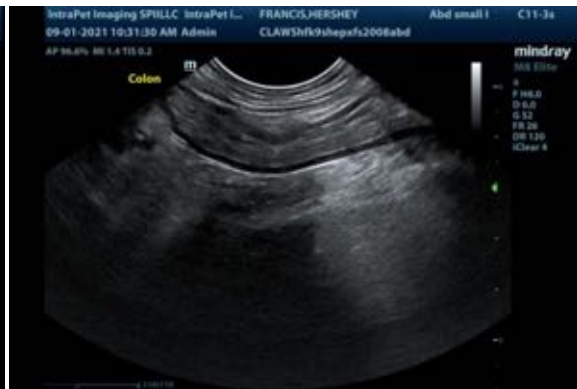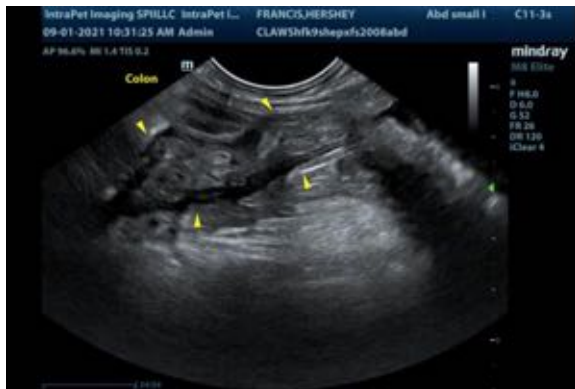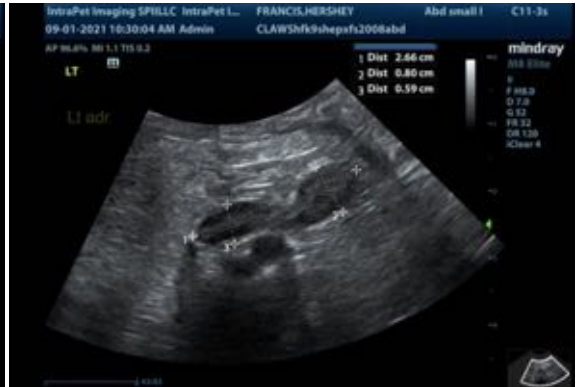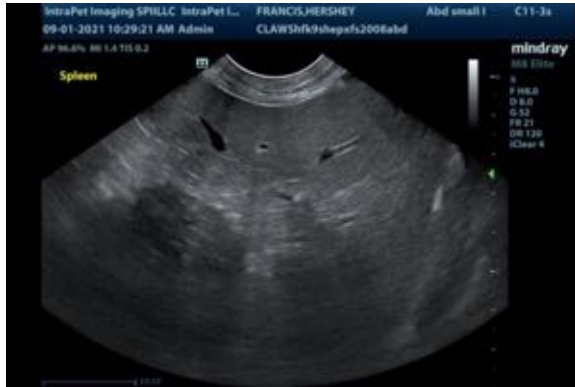- The colonic wall changes (particularly at the distal aspect) are concerning for infiltrative neoplasia (i.e., lymphoma, adenocarcinoma). However, a severe inflammatory process is also possible.
- The small intestinal wall changes are consistent with a protein-losing enteropathy. Differentials include infiltrative neoplasia, lymphangiectasia, inflammatory bowel disease, infectious/parasitic disease, other enteropathy.
- The diffuse peritonitis is likely secondary to bowel pathology and the presence of ascites.

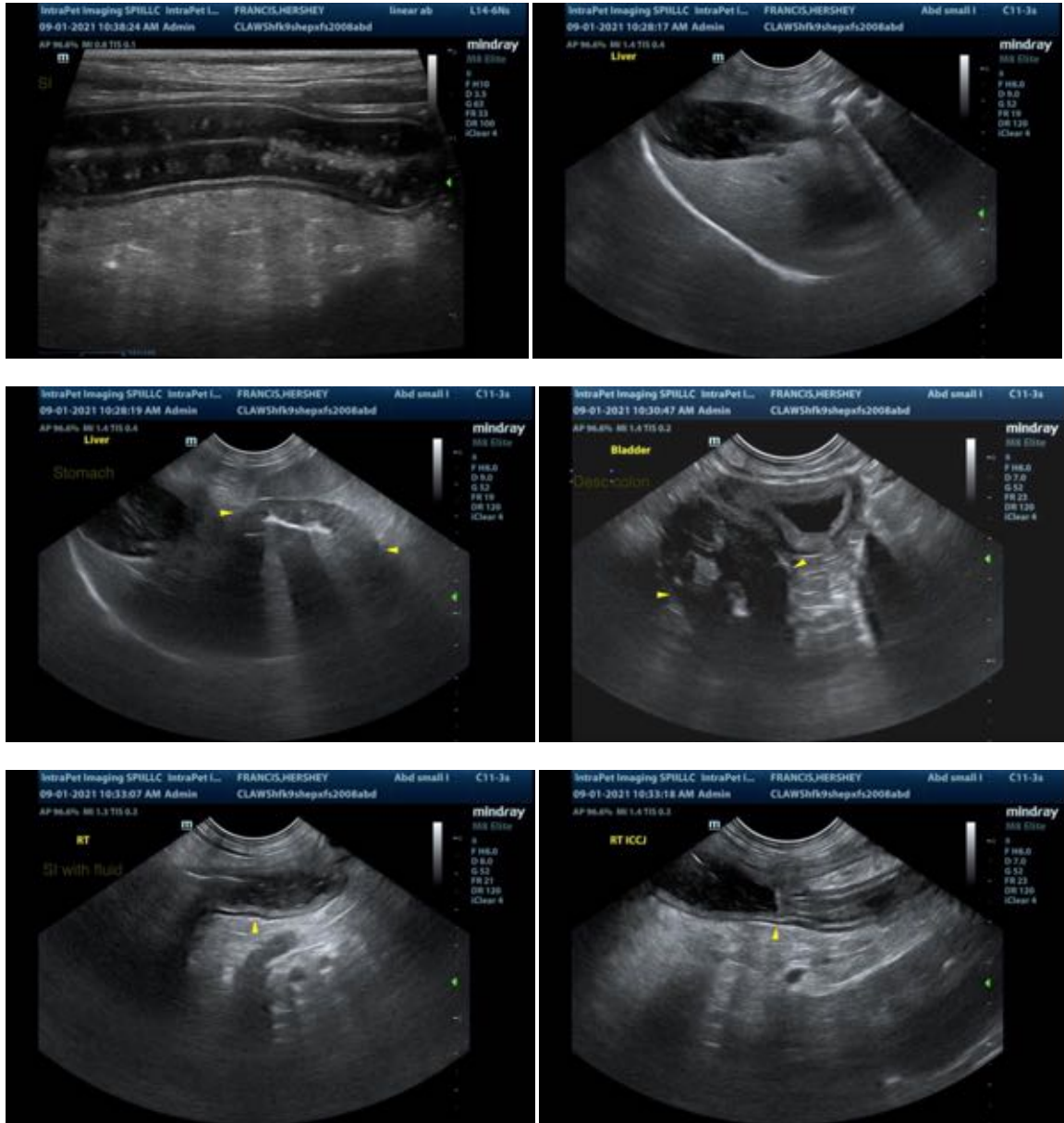
### **Secondary Findings:**

- Minor age-related renal changes with dystrophic mineralization.

## **INTERPRETATION OF THE FINDINGS & FURTHER RECOMMENDATIONS**

- Gastrointestinal/colonic biopsies are recommended to obtain a definitive diagnosis.
- Other diagnostic considerations include the following:
  - Malabsorption panel including serum cobalamin, folate, TLI and PLI
  - A fecal evaluation for ova/Giardia
  - Three-view thoracic radiographs to assess cardiopulmonary status.





The information and recommendations provided are based on the images presented by the referring veterinarian. No evaluation can be communicated regarding pathology that was not visible in the image/video clips provided.

Thank you for this referral. If the clinical or image interpretation does not parallel your findings or if I can be of any further assistance please contact me.

Andrea Nicastro, DVM, Diplomate ACVIM (*Small Animal Internal Medicine*)  
 Andrea.nicastro@sonopath.com