**PATIENT**

Rylie Grivas

SPECIES

Canine

BREED

Pointer/Boxer mix

SEX

Female, spayed

AGE

8 Yrs.

WEIGHT**PRESENTING CLINICAL SIGNS**

History: Hypercalcemia. Concern for kidney disease. Pu/Pd for the past week.

Abnormal PE/Chem/CBC/UA Results: CBC- platelet 119 Chem- Idexx SDMA 18, Creat 1.6, BUN 18. Ca 12.6 U/A - USG 1.006, pH 6.5, protein neg, rbc/wbc neg. T4 1.7

ULTRASONOGRAPHIC EXAMINATION OF THE ABDOMEN

The left thyroid lobe is normal in size (3.10 x 0.47 cm) with a normal shape and smooth peripheral contours. The parenchyma is homogeneous. A 0.48 x 0.17 cm parathyroid gland is observed at the cranial aspect. The parathyroid gland is relatively normal in shape and causes minimal/slight capsular expansion.

The right thyroid lobe is normal in size (2.89 x 0.36 cm) with a normal shape and smooth peripheral contours. The parenchyma is homogeneous. A 0.31 x 0.17 cm parathyroid gland is observed at the cranial aspect. The parathyroid gland is relatively normal in shape and causes no capsular expansion.

The left salivary gland measures 3.43 x 1.29 cm and is normal in size, shape and echogenicity. No obvious pathology is observed.

The right salivary gland measures 3.52 x 1.42 cm and is normal in size, shape and echogenicity. No obvious pathology is observed.

The retropharyngeal lymph nodes are subjectively normal in size, shape and echogenicity.

ULTRASONOGRAPHIC FINDINGS

The visible left parathyroid gland is upper limits of normal size. It is unclear whether this represents a functional adenoma (or hyperplastic gland). Correlation with the patient's PTH level is recommended.

INTERPRETATION OF THE FINDINGS & FURTHER RECOMMENDATIONS

PTH/PTHrP/ionized calcium is recommended. Depending on the results, a left parathyroidectomy may be warranted.

INTERPRETED BY

Andrea Nicastro,
DVM, Diplomate
ACVIM (*Small Animal
Internal Medicine*)

IMAGING PERFORMED BY

PMVU

HOSPITAL NAME

Fairfax Ridge AH

REFERRING VET

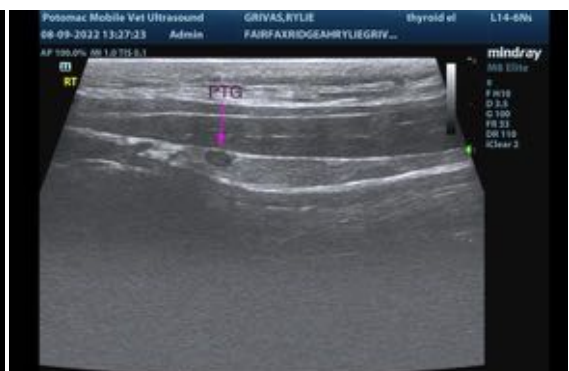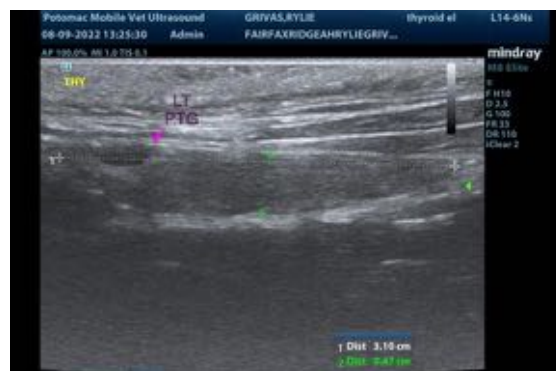Dr. Cathy Jarrett

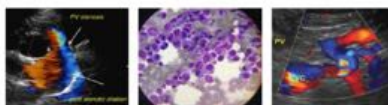
INVOICE

13802

DATE

8/9/22





PATIENT

Rylie Grivas

SPECIES

Canine

BREED

Pointer/Boxer mix

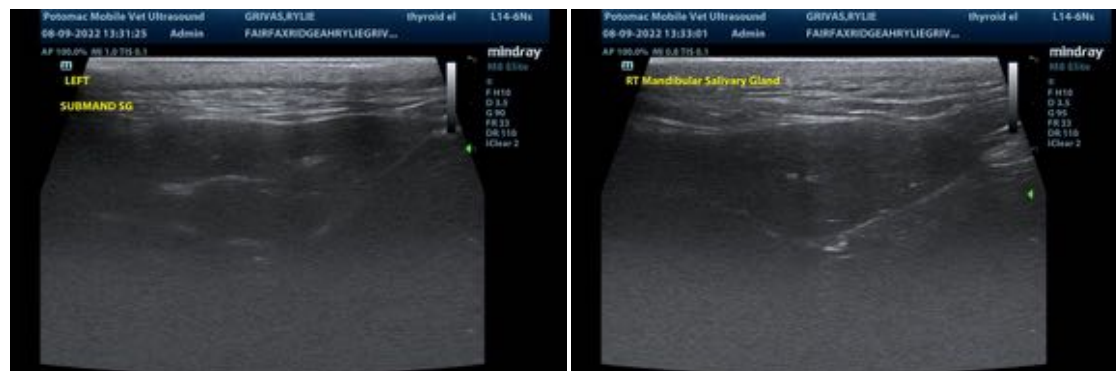
SEX

Female, spayed

AGE

8 Yrs.

WEIGHT



The information and recommendations provided are based on the images presented by the referring veterinarian. No evaluation can be communicated regarding pathology that was not visible in the image/video clips provided.

Thank you for this referral. If the clinical or image interpretation does not parallel your findings or if I can be of any further assistance please contact me.

Andrea Nicastro, DVM, Diplomate ACVIM (*Small Animal Internal Medicine*)

Andrea.nicastro@sonopath.com

INTERPRETED BY

Andrea Nicastro,
DVM, Diplomate
ACVIM (*Small Animal
Internal Medicine*)

IMAGING PERFORMED BY

PMVU

HOSPITAL NAME

Fairfax Ridge AH

REFERRING VET

Dr. Cathy Jarrett

INVOICE

13802

DATE

8/9/22