

**DATE PRESENTING CLINICAL SIGNS**

8.8.2022 Chronic weight loss (2 pounds since last vet visit in 2020), intermittent vomiting. ALT elevation, low normal albumin, questionably reduced appetite.

PATIENT

Jujubee MacMurray

Current Medications: None presently but will come on gabapentin 100mg.

Lab Results: 6/28 rDVM labs ALT 187, Albumin 2.9, normal T4.

Date of Previous IntraPet Ultrasound: No previous.

Sedation: Not required to complete full diagnostic ultrasound.

Stat Report: Not requested.

SPECIES

Feline

Imaging Performed By: Andi Parkinson, BS, RDMS.

BREED**ULTRASONOGRAPHIC EXAMINATION OF THE ABDOMEN**

DLH

Urinary System

The **urinary bladder** wall is normal in thickness and the mucosal surface is smooth. The bladder lumen is moderately distended with anechoic urine. No masses, inflammatory changes or calculi are observed. Ureteral papillae and visualized portion of the proximal urethra, visible to a depth of 2 cm, are normal.

SEX

Spayed Female

AGE

8/1/12

The **left kidney** is normal size (3.96 cm in length); normal shape and architecture with smooth peripheral margins. There is a normal 1:3 cortex to medulla ratio with moderate loss of corticomedullary distinction. There is no evidence of pyelectasia, nephroliths, infarcts or hydroureter.

WEIGHT

3.51 kg

The **right kidney** is normal size (3.29 cm in length); normal shape and architecture with smooth peripheral margins. There is a normal 1:3 cortex to medulla ratio with moderate loss of corticomedullary distinction. There is no evidence of pyelectasia, nephroliths, infarcts or hydroureter.

INTERPRETED BY

Andrea Nicastro, DMV,
Diplomate DACVIM
(Small Animal
Internal Medicine)

Adrenal Glands

The **left adrenal gland** is normal size (0.35 cm width). Normal shape and glandular echogenicity. The phrenicoabdominal vein and surrounding vasculature are normal.

The **right adrenal gland** is normal size (0.49 cm width). Normal shape and glandular echogenicity. The phrenicoabdominal vein and surrounding vasculature are normal.

HOSPITAL NAME

Nexus Veterinary
Specialists

Spleen

The **spleen** is subjectively normal in size (0.92 cm in width at the level of the hilus) with normal curvilinear peripheral contours. The parenchyma is diffusely mottled, bordering on a "moth-eaten" appearance. No distinct focal lesions are observed. Splenic vasculature is normal with no evidence of thrombosis.

REFERRING VET

Dr. Steele

Liver

The **liver** is subjectively normal in size with irregular peripheral contours. The parenchyma is hypoechoic relative to the spleen and heterogenous in appearance. No distinct focal lesions are observed. Hepatic vasculature and intrahepatic biliary tracts are of normal volume with no evidence of congestion.

INVOICE

11369

The **gall bladder** is moderately distended. The wall is diffusely thickened (up to 0.25 cm), hyperechoic and irregular. Luminal contents are mostly anechoic. The cystic and common bile ducts are tortuous and dilated. The common bile duct measures 0.37 cm in diameter at its distal aspect. The duodenal papilla is normal in size (0.31 cm in width). There is no obvious evidence of and intraluminal obstruction.

Gastrointestinal

The **stomach and intestine** are free of stasis and exhibit normal peristaltic activity. The gastric lumen is not distended. The gastric wall and pylorus are normal in thickness with a normal layering pattern. The pyloric

outflow tract is patent. The small intestinal lumen is not dilated. The small intestinal wall thickness is normal with a normal layering pattern and appropriate mural detail. There is disruption in the normal 1:3 muscularis: mucosal ratio in most segments. Discreet masses are not identified. The ileocecal colic junction and colonic wall are normal. No obstructive disease is noted.

Pancreas

The right limb of the **pancreas** is visible with normal curvilinear peripheral contours. The parenchyma is largely isoechoic relative to surrounding omental fat and slightly mottled in appearance. The pancreatic duct is visible but not overtly dilated. There is no evidence of peripancreatic inflammation or effusion.

Free Abdomen

There is no evidence of free fluid. The abdominal **lymph nodes** are normal/not visible.

ULTRASONOGRAPHIC FINDINGS

Primary Findings

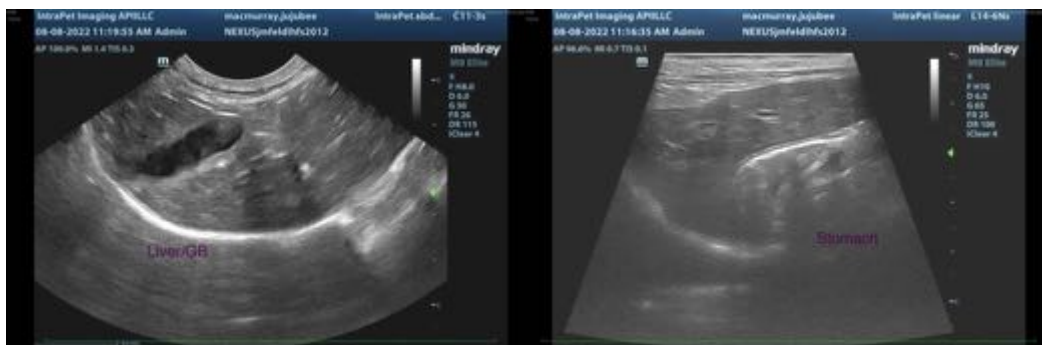
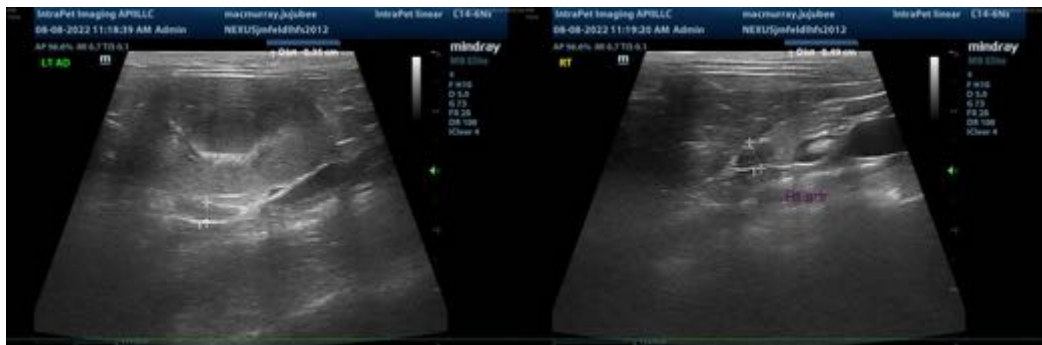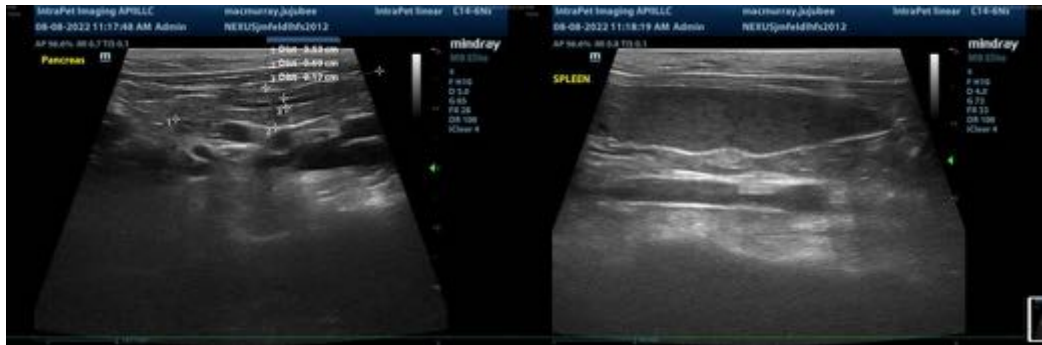
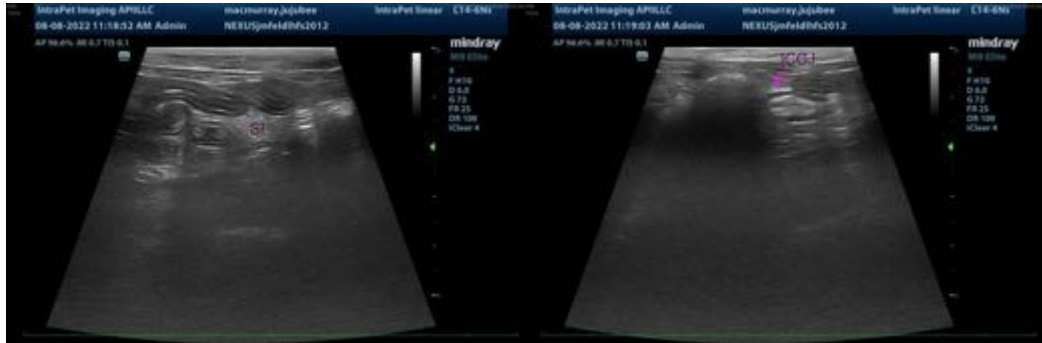- The splenic parenchymal changes are concerning for emerging neoplasia (i.e., round cell tumor). However, a benign process (i.e., lymphoid hyperplasia, extramedullary hematopoiesis, or similar) cannot be completely excluded.
- Diffuse hepatopathy. Top differentials include inflammatory disease (i.e., lymphoplasmacytic hepatitis, bacterial cholangiohepatitis), infiltrative neoplasia (i.e., lymphoma, fibrosis) or other hepatopathy.
- The gall bladder and cystic/common bile duct changes are consistent with cholecystitis/cholangitis, without obvious evidence of intraluminal common bile duct obstruction.
- Bowel pattern consistent with inflammatory bowel disease with some potential for emerging lymphoma.

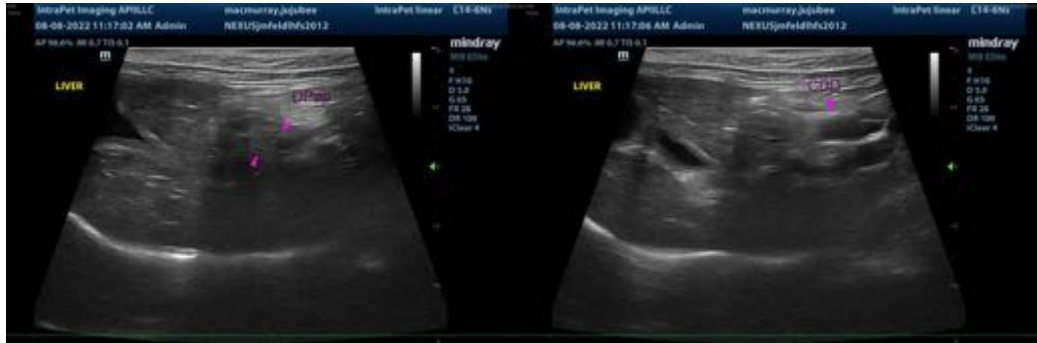Secondary Findings

- The pancreatic changes are most consistent with age-related remodeling, +/- fibrosis. Concurrent low-grade pancreatitis is also a possibility, particularly if the patient's clinical history is supportive of this diagnosis.
- Bilateral, chronic, age-related renal changes

INTERPRETATION OF THE FINDINGS & FURTHER RECOMMENDATIONS

Further diagnostic and treatment recommendations are to be implemented by Dr. Cara Steele.





The information and recommendations provided are based on the images presented by the referring veterinarian/sonographer. No evaluation can be communicated regarding pathology that was not visible in the image/video clips provided.

Thank you for this referral. If the clinical or image interpretation does not parallel your findings or if I can be of any further assistance, please contact me.

Andrea Nicastro, MPH, DVM, Diplomate DACVIM (Small Animal Internal Medicine)
info@SonoPath.com