



## PATIENT PRESENTING CLINICAL SIGNS

JR Ferro History: 2-3 day history of anorexia and vomiting bile. Rads taken at referral showed poss cranial abd mass as well as poss lesion in chest. Hx of HCM (not severe enough for treatment)  
Abnormal PE/Chem/CBC/UA Results: CBC/Chem WNL

## SPECIES

Feline

## ULTRASONOGRAPHIC EXAMINATION OF THE ABDOMEN

### BREED *Urinary System*

DSH

The **urinary bladder** wall is normal in thickness and the mucosal surface is smooth. The bladder lumen is moderately distended with anechoic urine. No masses, inflammatory changes or calculi are observed. The region of the trigone and the visible portion of the proximal urethra are normal.

### SEX

Neutered Male

The **left kidney** is normal size (4.19 cm in length); normal shape and architecture with smooth peripheral margins. There is a normal 1:3 cortex to medulla ratio with minimal to mild loss of corticomedullary distinction. There is no evidence of pyelectasia, nephroliths, infarcts or hydroureter.

### AGE

12 years

The **right kidney** is normal size (4.29 cm in length); normal shape and architecture with smooth peripheral margins. There is a normal 1:3 cortex to medulla ratio with minimal to mild loss of corticomedullary distinction. There is no evidence of pyelectasia, nephroliths, infarcts or hydroureter.

### *Adrenal Glands*

The region of the **adrenal glands** is evaluated. No obvious pathology is observed.

## WEIGHT

13 lbs

### *Spleen*

The **spleen** is prominent in size (1.04 cm in width at the level of the hilus) with normal curvilinear peripheral contours. Throughout the organ, ill-defined hyperechoic areas are observed within the parenchyma. Splenic vasculature is normal with no evidence of thrombosis.

## INTERPRETED BY

Andrea Nicastro,  
DVM, Diplomate  
ACVIM (*Small Animal  
Internal Medicine*)

### *Liver*

The **liver** is subjectively normal in size with normal contours and structure. There is appropriate echogenicity and echotexture. No overt structural evidence of inflammatory, infiltrative, or regenerative pathology is evident. Vascular and biliary tracts are of normal volume with no evidence of congestion. No pathological hepatic lymphadenopathy observed.

## IMAGING PERFORMED BY

Dr. Scott

The **gall bladder** lumen is moderately distended. The wall is thin and smooth. Luminal contents are anechoic. The cystic and common bile ducts are normal.

## HOSPITAL NAME

Ho Ho Kus VH

### *Gastrointestinal*

The **gastric lumen** is not distended. The gastric wall is normal in thickness with a normal layering pattern. The small intestinal lumen is not dilated. The duodenal and jejunal walls are normal in thickness with a normal layering pattern. In a segment of bowel, which is thought to be ileum, a 2.22 x 1.09 cm irregular hypoechoic mass effect is observed. The wall in this region is thickened (up to 1.08 cm) with loss of the normal layering pattern. The mesentery effacing the serosal surface in this region is hyperechoic. The colonic wall is normal. There is no evidence of an obstructive pattern.

## REFERRING VET

Dr. Eisenberg

### *Pancreas*

The region of the **pancreas** is isoechoic relative to surrounding omental fat. No obvious parenchymal abnormalities are observed. There is no evidence of regional inflammation or effusion.

## INVOICE

11364

### *Free Abdomen*

There is no evidence of free fluid. The abdominal **lymph nodes** are normal/not visible.

## DATE

8.8.22

## ULTRASONOGRAPHIC FINDINGS

### Primary Findings

- Focal bowel mass, thought to be ileum. Neoplasia (i.e., adenocarcinoma, round cell tumor) is considered likely. However, a focal inflammatory process (i.e., pyogranulomatous) can be considered. Adjacent peritonitis is present.

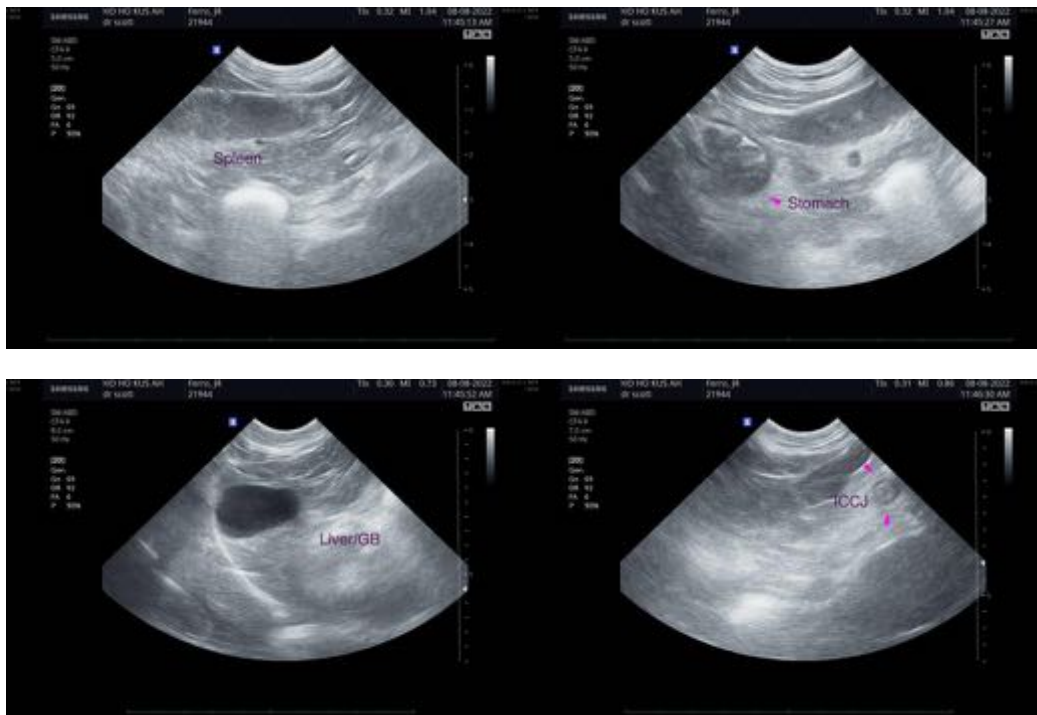
### Secondary Findings

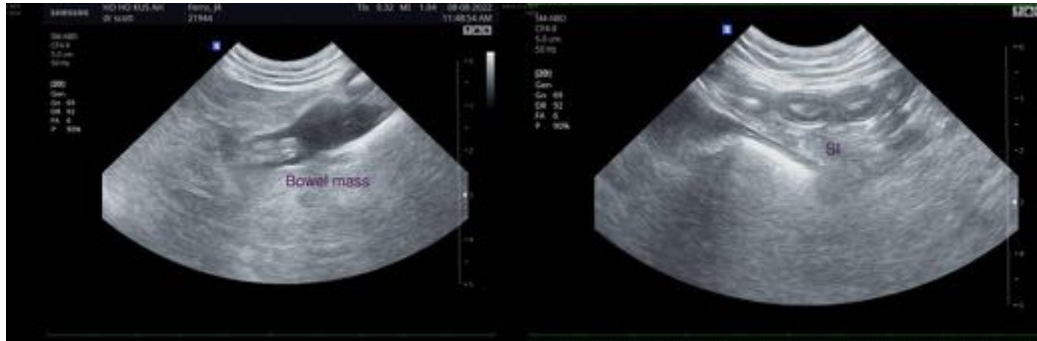- Minor, bilateral, age-related renal changes
- The hyperechoic splenic lesions trend toward the benign (i.e., myelolipomas, or regions of lymphoid hyperplasia) with a lower possibility of emerging neoplasia.

## INTERPRETATION OF THE FINDINGS & FURTHER RECOMMENDATIONS

Three-view thoracic radiographs are recommended to assess for pulmonary metastases.

A fine-needle aspirate of the bowel mass is recommended, if accessible and if clotting status is appropriate. If cytology results are inconclusive, or if the lesion is not accessible, consider an abdominal exploratory with biopsy +/- removal of the bowel mass.





The information and recommendations provided are based on the images presented by the referring veterinarian/sonographer. No evaluation can be communicated regarding pathology that was not visible in the image/video clips provided.

Thank you for this referral. If the clinical or image interpretation does not parallel your findings or if I can be of any further assistance, please contact me.

**Andrea Nicastro, MPH, DVM, Diplomate DACVIM (Small Animal Internal Medicine)**  
[info@SonoPath.com](mailto:info@SonoPath.com)