



PATIENT

Eloise Tapalla

SPECIES

Canine

BREED

Bichon Frise Mix

SEX

Spayed Female

AGE

7.5 years

WEIGHT

14.50 lbs

INTERPRETED BY

Andrea Nicastro,
DVM, Diplomate
ACVIM (*Small Animal
Internal Medicine*)

IMAGING PERFORMED BY

Shari Reffi, CVT

HOSPITAL NAME

Newton VH

REFERRING VET

Dr. Kiim

INVOICE

11354

DATE

8.8.22

PRESENTING CLINICAL SIGNS

History: V/D, soft tissue material noted in stomach on radiographs, suspect pancreatitis. Current meds: Unasyn, Cerenia

Abnormal PE/Chem/CBC/UA Results: Cpl-abnormal, Lymphs 0.67(0.83L); Phos 1.4(1.9L); Glucose 160(125H); K 3.3(3.8L)

ULTRASONOGRAPHIC EXAMINATION OF THE ABDOMEN

Urinary System

The **urinary bladder** wall is normal in thickness and the mucosal surface is smooth. The bladder lumen is moderately distended with anechoic urine. No masses, inflammatory changes or calculi are observed. Ureteral papillae and visualized portion of the proximal urethra, visible to a depth of 2 cm, are normal.

The **left kidney** is normal size (3.64 cm in length); normal shape and architecture with smooth peripheral margins. There is a normal 1:3 cortex to medulla ratio with minimal to mild loss of corticomedullary distinction. There is no evidence of pyelectasia, nephroliths, infarcts or hydroureter. Renal vasculature is normal.

The **right kidney** is normal size (4.38 cm in length); normal shape and architecture with smooth peripheral margins. There is a normal 1:3 cortex to medulla ratio with minimal to mild loss of corticomedullary distinction. Mild pyelectasia is present (0.22 cm in the longitudinal plane). There is no evidence of nephroliths, infarcts or hydroureter. Renal vasculature is normal.

Adrenal Glands

The **left adrenal gland** is normal size (0.41 cm at cranial pole) (0.39 cm at caudal pole) (1.82 cm in length); normal shape; homogenous parenchyma. The glandular echogenicity and detail are unremarkable. Capsule, cortex, and medullary definition are normal. The phrenicoabdominal vein and surrounding vasculature are normal.

The **right adrenal gland** is normal size (0.71 cm at cranial pole) (0.45 cm at caudal pole) (1.83 cm in length); normal shape; homogenous parenchyma. The glandular echogenicity and detail are unremarkable. Capsule, cortex, and medullary definition are normal. The phrenicoabdominal vein and surrounding vasculature are normal.

Spleen

The **spleen** is normal in size (1.21 cm in width at the level of the hilus) with a normal capsular contour. There is appropriate echogenicity and echotexture. No focal lesions are observed. Splenic vasculature is normal.

Liver

The **liver** is subjectively normal in size with normal contours and structure. There is appropriate echogenicity and echotexture. No overt structural evidence of inflammatory, infiltrative, or regenerative pathology is evident. Vascular and biliary tracts are of normal volume with no evidence of congestion. No pathological hepatic lymphadenopathy observed.

The **gall bladder** lumen is moderately distended. The wall is thin and smooth. Luminal contents are anechoic. The cystic and common bile ducts are normal/not seen.

Gastrointestinal

The **gastric lumen** is mildly distended with echogenic ingesta and a small amount of soft, shadowing material. The gastric wall and pylorus are normal in thickness with a normal layering pattern. The pyloric outflow tract appears patent. The small intestinal lumen is not dilated. The small intestinal wall thickness is normal with a normal layering pattern and appropriate mural detail. Discreet masses are not identified. The colonic wall is normal. There is no evidence of an obstructive pattern.

Pancreas

The region of the **pancreas** is isoechoic relative to surrounding omental fat. No obvious parenchymal abnormalities are observed. There is no evidence of regional inflammation or effusion.

Free Abdomen

The **peritoneal cavity** is normal. There is no evidence of inflammation or effusion. The abdominal **lymph nodes** are normal/not visible.

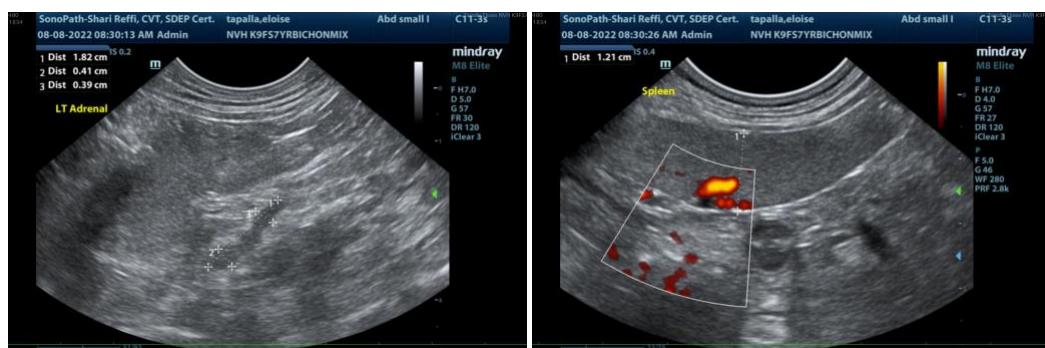
ULTRASONOGRAPHIC FINDINGS

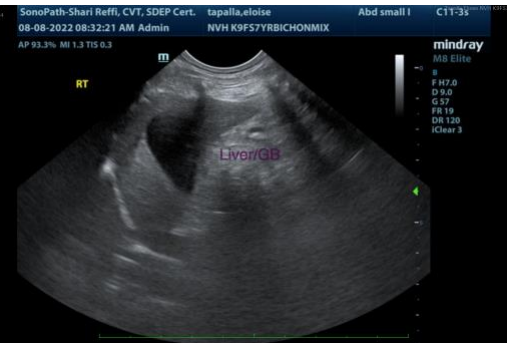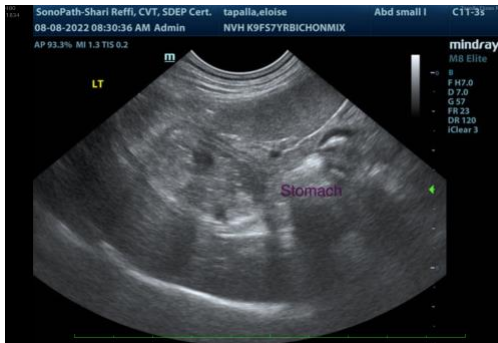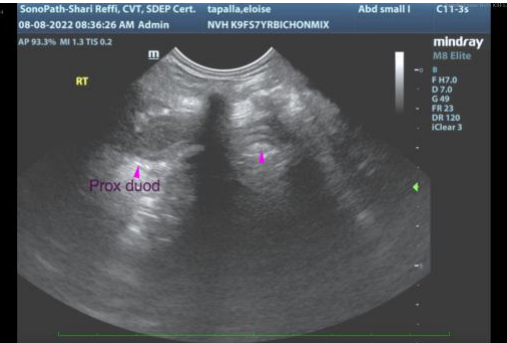
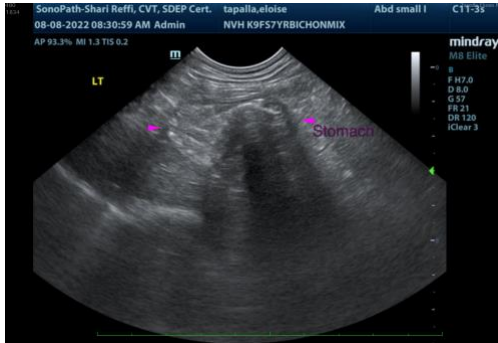
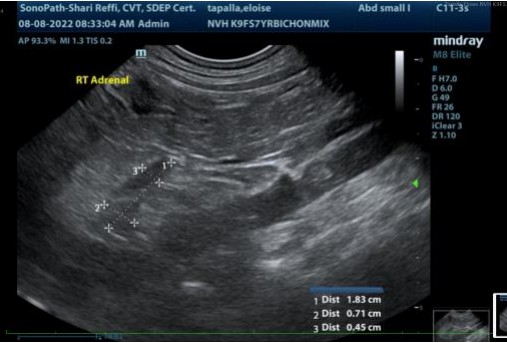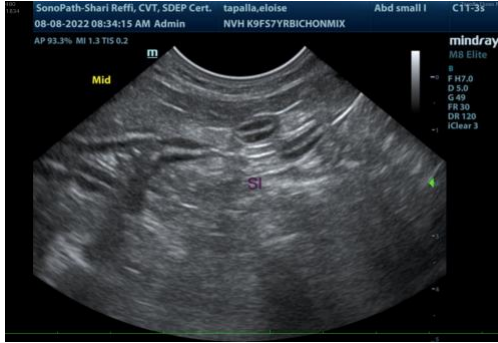Primary Findings

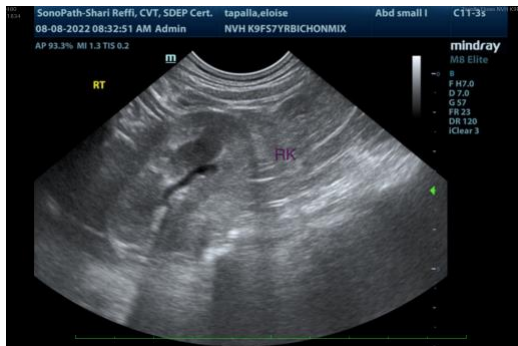- The gastric luminal contents may represent normal ingesta and/or foreign material. The pyloric outflow tract does not appear obstructed at the time of this study.
- Bilateral, chronic, age-related kidney changes. The right pyelectasia may be secondary to pyelonephritis, age-related remodeling, fluid therapy (if applicable), PU/PD or some combination thereof.

INTERPRETATION OF THE FINDINGS & FURTHER RECOMMENDATIONS

- Supportive care for gastroenteritis is recommended. If the patient's clinical signs do not improve over the next 24 hours, a repeat abdominal ultrasound, +/- a gastrotomy, may be warranted.
- Given the right pyelectasia, a urine culture and sensitivity is recommended.







The information and recommendations provided are based on the images presented by the referring veterinarian/sonographer. No evaluation can be communicated regarding pathology that was not visible in the image/video clips provided.

Thank you for this referral. If the clinical or image interpretation does not parallel your findings or if I can be of any further assistance, please contact me.

Andrea Nicastro, MPH, DVM, Diplomate DACVIM (Small Animal Internal Medicine)
info@SonoPath.com