

**DATE PRESENTING CLINICAL SIGNS**

8.4.23 Excessive panting/ restless (pain?) History of bladder cancer (had radiation treatment) / urinating small amount.

PATIENT

Izzy Jakubowski

Current Medications: Vetprofen 75mg: 1/2 tablet once daily, gabapentin 100mg: 1 cap three times daily
 Radiographs: densities in lungs, possible mass in duodenum, large swollen liver? mass in urethral recurring?
 Date of Previous IntraPet Ultrasound: 1/2/23. See attached.
 Sedation: Not required to complete full diagnostic ultrasound.
 Stat Report: Not requested.
 Imaging Performed By: Rachel Brillhart, RDMS.

SPECIES

Canine

ULTRASONOGRAPHIC EXAMINATION OF THE ABDOMEN**BREED**

Mixed

Urinary System

The urinary bladder is mildly-to-moderately distended. The wall is of appropriate thickness for the level of repletion. The mucosal surface is generally smooth. A few small mineralizations are observed near the cystourethral junction. Luminal contents are otherwise anechoic. The trigone area is normal. The proximal urethra is mildly thickened (up to 0.44 cm) and irregular. A 0.23 cm mineralized focus is observed within the urethral wall. The urethral lumen is not overtly dilated.

SEX

Female Spayed

AGE

9/19/2009

The left kidney is normal in size (5.08 cm in length) with a slightly irregular shape, and smooth peripheral contours. The cortex is isoechoic relative to the spleen, and diffusely thickened with moderate loss of corticomedullary distinction. Several, varying-sized cortical cysts are seen. Hyperechoic shadowing diverticular foci are visualized. Several, small, nonobstructive nephroliths are present. There is no evidence of pyelectasia, or hydroureter. Renal vasculature is normal.

WEIGHT

20 lbs

The right kidney is normal in size (5.29 cm in length) with a normal shape, and smooth peripheral contours. The cortex is isoechoic relative to the spleen, and diffusely thickened with moderate loss of corticomedullary distinction. Several varying-sized cortical cysts are seen. Hyperechoic shadowing diverticular foci are visualized. Several small, nonobstructive nephroliths are present. There is no evidence of pyelectasia, infarcts or hydroureter. Renal vasculature is normal.

INTERPRETED BY

Andrea Nicastro, DMV,
 Diplomate DACVIM
 (Small Animal
 Internal Medicine)

Adrenal Glands

The left adrenal gland is mildly enlarged (0.63 cm at cranial pole) (0.79 cm at caudal pole) (2.38 cm in length) with a normal shape and homogenous parenchyma. The glandular echogenicity and detail are unremarkable. Capsule, cortex, and medullary definition are normal. The phrenicoabdominal vein and surrounding vasculature are normal.

HOSPITAL NAME

Honeygo AH

REFERRING VET

Dr. Wright

The right adrenal gland is mildly enlarged (0.50 cm at cranial pole) (0.61 cm at caudal pole) (2.09 cm in length) with a normal shape and homogenous parenchyma. The glandular echogenicity and detail are unremarkable. Capsule, cortex, and medullary definition are normal. The phrenicoabdominal vein and surrounding vasculature are normal.

INVOICE

13939

Spleen

The spleen is normal in size (1.33 cm in width at the level of the hilus) with a normal capsular contour. There is appropriate echogenicity and echotexture. No focal lesions are observed. Splenic vasculature is normal.

Liver

The liver is subjectively prominent in size with normal curvilinear peripheral contours. The parenchyma is isoechoic relative to the spleen and exhibits subtle heterogeneity. A few small, ill-defined hyperechoic nodules are observed. Hepatic vasculature and intrahepatic biliary tracts are of normal volume with no

evidence of congestion.

The gall bladder lumen is moderately distended. The wall is thin and smooth. A small amount of aggregated echogenic-to-mineralized, partially dependent debris is observed within the lumen. The cystic and common bile ducts are normal/not seen.

Gastrointestinal

The gastric lumen is not distended. The gastric wall is normal in thickness with a normal layering pattern. In the region of the pyloric outflow tract/proximal duodenum, an approximately 1.50 cm focal area of wall thickening (up to 1.10 cm) is observed. There is suspected retention of ingesta orad to this region. There is a loss of the normal layering pattern in this region. In the remainder of the small intestine, the lumen is empty. The wall is normal in thickness with a normal layering pattern and appropriate mural detail. The colonic wall is normal.

Pancreas

The right limb of the pancreas is visible with normal curvilinear peripheral contours. The parenchyma is largely isoechoic relative to surrounding omental fat and slightly mottled in appearance. The pancreatic duct is visible but not overtly dilated. There is no evidence of peripancreatic inflammation or effusion.

Free Abdomen

There is no obvious evidence of free fluid. A 0.55 cm lymph node is observed within the cranial abdomen, adjacent to the pyloric outflow tract.

Other

A brief echocardiogram reveals no evidence of pericardial effusion or obvious right atrial/auricular mass. There are no obvious nodules in the visible window of the thorax.

ULTRASONOGRAPHIC FINDINGS

Primary Findings

- The urethral changes appear improved compared to the previous sonogram. The proximal urethra only appears mildly thickened at this time. A few foci of mineralization are observed within the urinary bladder and the urethra. There is no obvious evidence of obstruction.
- Suspected focal proximal duodenal wall thickening. Differentials include neoplasia (i.e., lymphoma, adenocarcinoma), focal inflammatory disease, other.

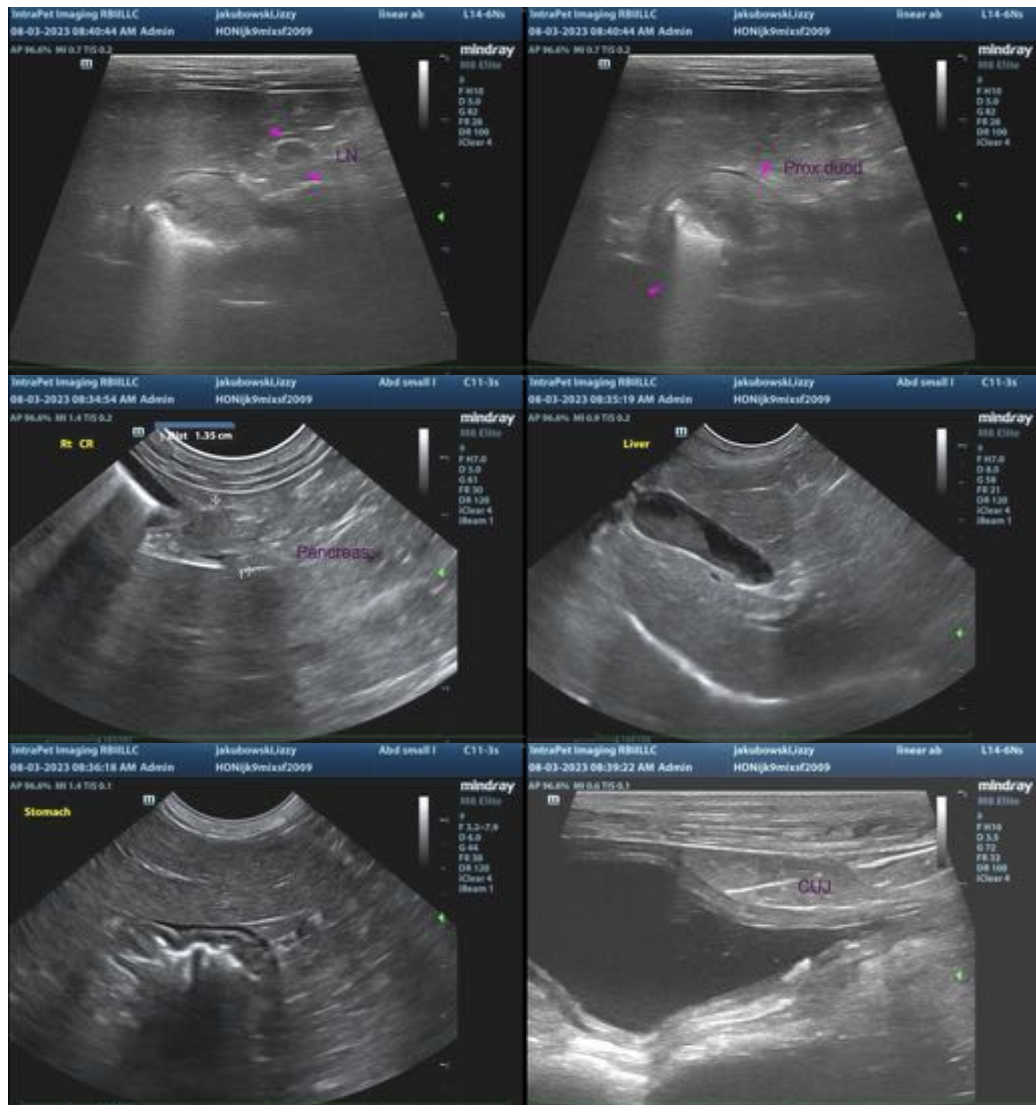
Secondary Findings

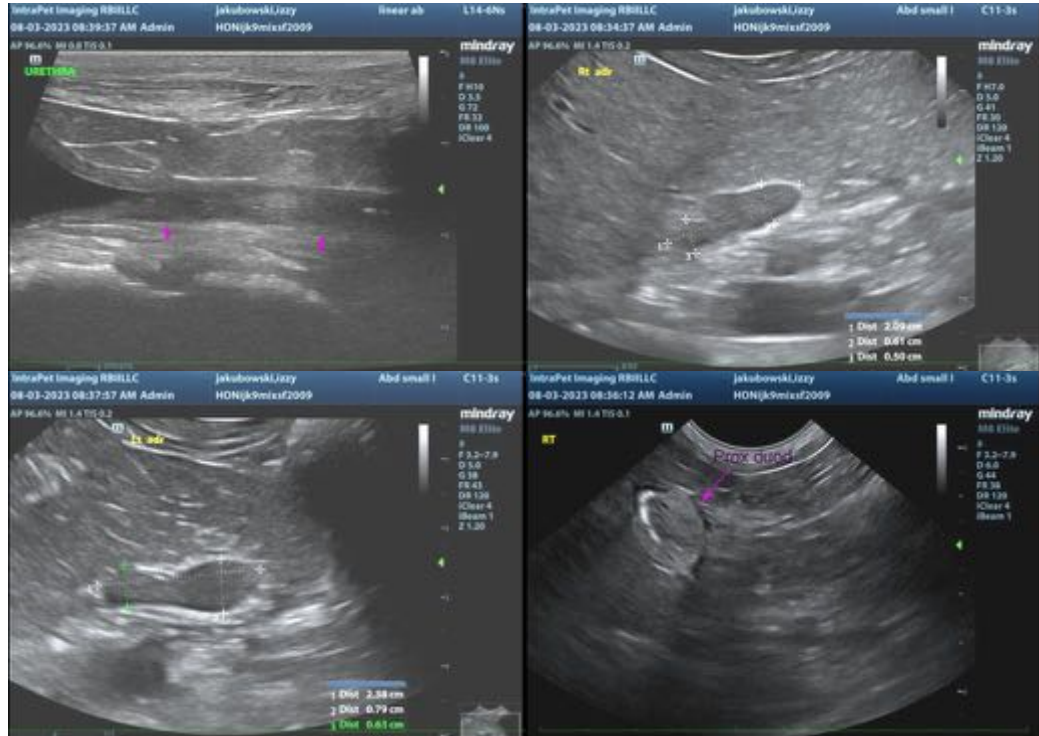
- Bilateral chronic renal changes with nonobstructive nephrolithiasis and cortical cysts.
- The diffuse hepatic changes are non-specific and could be consistent with vacuolar hepatopathy, regenerative nodular hyperplasia, and/or age-related remodeling. Inflammatory and infiltrative disease are considered less likely.
- Gallbladder debris, non-mucocele
- Mild bilateral adrenomegaly
- The pancreatic changes are most consistent with age-related parenchymal remodeling, potentially secondary to a prior inflammatory episode, early fibrosis or chronic pancreatitis.

- The prominent lymph node in the cranial abdomen is likely reactive, with a lower possibility of emerging neoplasia.

INTERPRETATION OF THE FINDINGS & FURTHER RECOMMENDATIONS

- Regarding the urethral disease, consider consultation with a board-certified oncologist for further recommendations.
- Regarding the proximal duodenal change, consider the following:
 1. Three-view thoracic radiographs to assess for pulmonary metastatic disease
 2. Endoscopic or surgical biopsies





The information and recommendations provided are based on the images presented by the referring veterinarian/sonographer. No evaluation can be communicated regarding pathology that was not visible in the image/video clips provided.

Thank you for this referral. If the clinical or image interpretation does not parallel your findings or if I can be of any further assistance, please contact me.

Andrea Nicastro, MPH, DVM, Diplomate DACVIM (Small Animal Internal Medicine)
info@SonoPath.com