


**PATIENT**

Hanna Tziatis

**PRESENTING CLINICAL SIGNS**

History: elevated liver enzymes, PU/PD, sluggish, weight loss, thickened scabbing skin along spine, diagnosed hypothyroid June 2022 meds: thyrotabs 05mg BID, sotalol 40mg BID (right ventricular cardiomyopathy)

**SPECIES**

Canine

Abnormal PE/Chem/CBC/UA Results: ALT 3 x normal, ALKP 10 normal, GGT 3 x normal, bile acids normal

**BREED**

Boxer X

**ULTRASONOGRAPHIC EXAMINATION OF THE ABDOMEN**
**Urinary System**

The **urinary bladder** wall is normal in thickness and the mucosal surface is smooth. The bladder lumen is moderately distended with anechoic urine. No masses, inflammatory changes or calculi are observed. Ureteral papillae and visualized portion of the proximal urethra, visible to a depth of 2 cm, are normal.

**SEX**

Spayed Female

**AGE**

10 years

The **left kidney** is normal size (6.28 cm in length); with a normal shape, smooth peripheral margins, and normal internal architecture. There is mild to moderate loss of corticomedullary distinction. Several hyperechoic shadowing diverticular foci are observed. There is no evidence of pyelectasia, infarcts or hydronephrosis. Renal vasculature is normal.

**WEIGHT**

61.2 lbs

The **right kidney** is normal size (6.02 cm in length); with a normal shape, smooth peripheral margins, and normal internal architecture. There is mild loss of corticomedullary distinction. Several hyperechoic shadowing diverticular foci are observed. There is no evidence of pyelectasia, infarcts or hydronephrosis. Renal vasculature is normal.

**INTERPRETED BY**

Andrea Nicastro, DVM,  
 Diplomate ACVIM  
 (Small Animal Internal  
 Medicine)

**Adrenal Glands**

The **left adrenal gland** is normal size (0.79 cm at cranial pole) (0.62 cm at caudal pole) (2.93 cm in length); normal shape; homogenous parenchyma. The glandular echogenicity and detail are unremarkable. Capsule, cortex, and medullary definition are normal. The phrenicoabdominal vein and surrounding vasculature are normal.

The **right adrenal gland** is mildly enlarged (2.01 cm at cranial pole) (1.22 cm at caudal pole) (2.58 cm in length); normal shape; homogenous parenchyma. The glandular echogenicity and detail are unremarkable. Capsule, cortex, and medullary definition are normal. The phrenicoabdominal vein and surrounding vasculature are normal.

**IMAGING PERFORMED BY**

Kelly Reschny

**Spleen**

The **spleen** is normal in size (2.47 cm in width at the level of the hilus) with a normal capsular contour. The parenchyma is subtly mottled in appearance. A 2.47 irregular heterogenous mass with hyperechoic areas is observed at the craniolateral aspect. Splenic vasculature is normal.

**HOSPITAL NAME**

AH Stoney Creek

**REFERRING VET**

Dr. Egbers

**Liver**

The liver is normal to slightly small in size with normal peripheral contours. The parenchyma is isoechoic relative to the spleen and diffusely homogeneous in appearance. No distinct focal lesions are observed. Vascular and biliary tracts are of normal volume with no evidence of congestion.

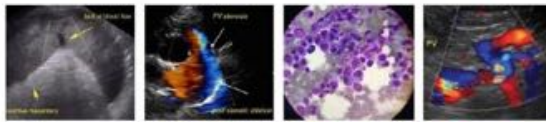
**INVOICE**

11330

The **gall bladder** lumen is moderately distended. The wall is thin and smooth. Luminal contents are anechoic. The cystic and common bile ducts are normal/not seen.

**Gastrointestinal**
**DATE**

8.4.22



**PATIENT**

Hanna Tziatis

The **gastric lumen** is mildly distended with ingesta. The gastric wall is normal in thickness with a normal layering pattern. The small intestinal lumen is not dilated. The small intestinal wall thickness is normal with a normal layering pattern and appropriate mural detail. Discreet masses are not identified. The colonic wall is normal. There is no evidence of an obstructive pattern.

**SPECIES**

Canine

**Pancreas**

The region of the **pancreas** is isoechoic relative to surrounding omental fat. No obvious parenchymal abnormalities are observed. There is no evidence of regional inflammation or effusion.

**BREED**

Boxer X

**Free Abdomen**

The **peritoneal cavity** is normal. There is no evidence of inflammation or effusion. The abdominal **lymph nodes** are normal/not visible.

**SEX**

Spayed Female

**ULTRASONOGRAPHIC FINDINGS**

**Primary Findings**

**AGE**

10 years

- Splenic mass. Differentials include neoplasia (i.e., sarcoma, round cell tumor) versus a benign process (i.e., myelolipoma, lymphoid hyperplasia, or similar).
- Nonspecific, diffuse hepatopathy. Differentials include inflammatory disease (i.e., bacterial cholangiohepatitis, chronic active hepatitis), hepatotoxicosis, Leptospirosis, infiltrative neoplasia (less likely), other hepatopathy, +/- concurrent age-related change (i.e., vacuolar hepatopathy and regenerative nodular hyperplasia).

**WEIGHT**

61.2 lbs

**Secondary Findings**

- Bilateral, nonspecific, chronic renal changes with dystrophic mineralization
- The right adrenomegaly may be a normal variant for this patient or may be secondary to hyperplastic change, or less likely, an emerging tumor.

**INTERPRETED BY**

Andrea Nicastro, DVM,  
Diplomate ACVIM  
(Small Animal Internal  
Medicine)

**INTERPRETATION OF THE FINDINGS & FURTHER RECOMMENDATIONS**

**IMAGING PERFORMED BY**

Kelly Reschny

Leptospirosis testing (i.e., blood and urine PCR, serology)

Given the splenic mass, three-view thoracic radiographs are recommended to assess for pulmonary metastatic disease.

**HOSPITAL NAME**

AH Stoney Creek

If an aggressive approach is desired, consider an abdominal exploratory with splenectomy and submission of the spleen for histopathology, along with a liver biopsy, aerobic and anaerobic bile cultures and acquisition of additional hepatic tissue samples for potential copper quantitation are recommended. Clotting times should be performed prior to any tissue sampling.

**REFERRING VET**

Dr. Egbers

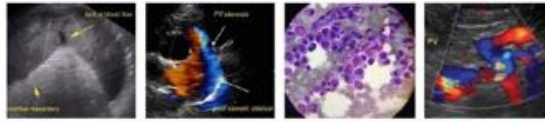
If a more conservative approach is desired, consider a fine-needle aspirate of the splenic mass, if clotting status is appropriate, along with empirical treatment for bacterial cholangiohepatitis/hepatotoxicosis (i.e., broad-spectrum antibiotic therapy and hepatic antioxidants). If no improvement in the liver values is seen within 5–7-days of initiating therapy, hepatic tissue sampling, should be revisited.

**INVOICE**

11330

**DATE**

8.4.22



**PATIENT**

Hanna Tziatis

**SPECIES**

Canine

**BREED**

Boxer X

**SEX**

Spayed Female

**AGE**

10 years

**WEIGHT**

61.2 lbs

**INTERPRETED BY**

Andrea Nicastro, DVM,  
Diplomate ACVIM  
(Small Animal Internal  
Medicine)

**IMAGING PERFORMED BY**

Kelly Reschny

**HOSPITAL NAME**

AH Stoney Creek

**REFERRING VET**

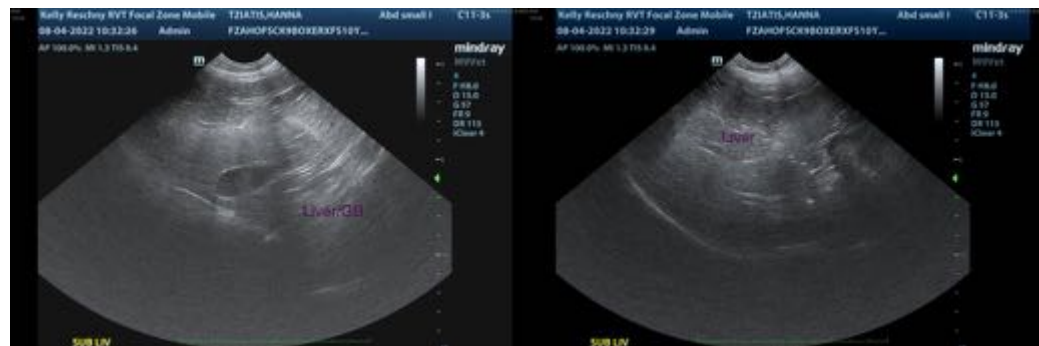
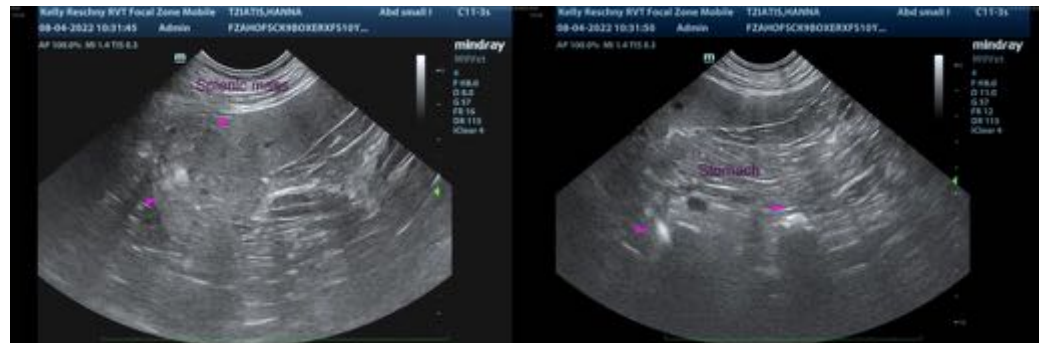
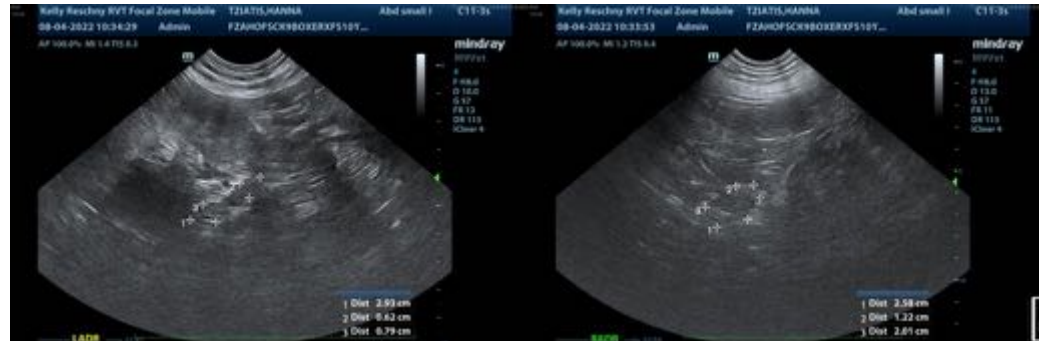Dr. Egbers

**INVOICE**

11330

**DATE**

8.4.22



The information and recommendations provided are based on the images presented by the referring veterinarian/sonographer. No evaluation can be communicated regarding pathology that was not visible in the image/video clips provided.

Thank you for this referral. If the clinical or image interpretation does not parallel your findings or if I can be of any further assistance, please contact me.

**Andrea Nicastro, MPH, DVM, Diplomate DACVIM (Small Animal Internal Medicine)**  
info@SonoPath.com