

**DATE PRESENTING CLINICAL SIGNS**

8.31.2022 13-year-old mixed breed dog that has been urinating in the house and had decreased appetite.

PATIENT

Current Medications: None listed.

Lab Results: UA- no evidence of UTI. Urine has elevated protein, p is 1.7, normal is 0.5 UPC.

Date of Previous IntraPet Ultrasound: No previous.

Sedation: Not required to complete full diagnostic ultrasound.

Stat Report: Not requested.

Imaging Performed By: Rachel Brillhart, RDMS.

Charlie Kluth-Martin

SPECIES

Canine

ULTRASONOGRAPHIC EXAMINATION OF THE ABDOMEN**BREED**

Mixed Breed

Urinary System

The **urinary bladder** is mildly distended with anechoic urine. The wall in the region of the apex is thickened (up to 0.82 cm) with an irregular mucosal surface. The wall tapers to a normal thickness as it extends towards the cystourethral junction. No cystic calculi are observed. The region of the trigone is normal.

SEX

Neutered Male

The region of the **prostate** is not visualized due to its pelvic location.

AGE

4/1/2009

The **left kidney** is normal size (6.57 cm in length); normal shape and architecture with smooth peripheral margins. There is a normal 1:3 cortex to medulla ratio with moderate loss of corticomedullary distinction. Several nonobstructive nephroliths are visualized. There is no evidence of pyelectasia, infarcts or hydroureter. Renal vasculature is normal.

WEIGHT

49lbs

The **right kidney** is normal size (6.65 cm in length); normal shape and architecture with smooth peripheral margins. There is a normal 1:3 cortex to medulla ratio with moderate loss of corticomedullary distinction. Several nonobstructive nephroliths are visualized. There is no evidence of pyelectasia, infarcts or hydroureter. Renal vasculature is normal.

INTERPRETED BY

Andrea Nicastro, DMV,
Diplomate DACVIM
(Small Animal
Internal Medicine)

Adrenal Glands

The **left adrenal gland** is enlarged (1.08 cm at cranial pole) (0.93 cm at caudal pole) (3.36 cm in length); with an irregular shape. The parenchyma is heterogenous with loss of glandular detail. A 0.36 cm cystic area is observed approximately mid-gland. The phrenicoabdominal vein and surrounding vasculature appear normal.

HOSPITAL NAME

Taylorsville
Veterinary Clinic

The **right adrenal gland** is enlarged (3.66 cm at cranial pole) (0.97 cm at caudal pole) (5.70 cm in length); with an irregular shape. A 4.43 x 3.74 cm heterogenous mass is arising from the cranial aspect. There is no obvious evidence vascular invasion. Glandular echogenicity and detail at the caudal aspect are normal.

REFERRING VET

Dr. Earp

Spleen

The **spleen** is normal in size (1.79 cm in width at the level of the hilus) with a normal capsular contour. There is appropriate echogenicity and echotexture. No focal lesions are observed. Splenic vasculature is normal.

INVOICE

11539

Liver

The **liver** is subjectively prominent in size with normal curvilinear peripheral contours. The parenchyma is isoechoic relative to the spleen and mottled in appearance, with at least one, ill-defined hypoechoic to anechoic nodule measuring 1.48 cm in diameter on the right side. Hepatic vasculature and intrahepatic biliary tracts are of normal volume with no evidence of congestion.

The **gall bladder** lumen is moderately distended. The wall is thin and smooth. A moderate amount of aggregated, echogenic suspended sludge in a partially stellate pattern, is observed within the lumen. The cystic and common bile ducts are normal/not seen.

Gastrointestinal

The **gastric lumen** is not distended. The gastric wall in the region of the fundus is normal in thickness with a normal layering pattern. The wall in the region of the pyloric antrum is thickened (up to 0.83 cm) with questionable retention of the normal layering pattern. The pyloric outflow tract is patent. The small intestinal lumen is not dilated. The small intestinal wall is normal in thickness with a normal layering pattern and appropriate mural detail. The ileocecolic junction and colonic wall are normal. There is no evidence of an obstructive pattern.

Pancreas

The region of the **pancreas** is isoechoic relative to surrounding omental fat. No obvious parenchymal abnormalities are observed. There is no evidence of regional inflammation or effusion.

Free Abdomen

There is no evidence of free fluid.

Lymph nodes

(See "Other" category).

Other

A 0.55 cm hypoechoic nodule is observed in the right cranial quadrant.

ULTRASONOGRAPHIC FINDINGS

Primary Findings

- Right adrenal mass. Differentials include neoplasia (i.e., adenocarcinoma, adenoma, pheochromocytoma) with a lower possibility of benign pathology (i.e., excessive nodular hyperplasia). The left adrenal changes are most consistent with hyperplastic change. However, an emerging tumor cannot be completely excluded.
- The gall bladder changes are consistent with a developing mucocele.

Secondary Findings

- Bilateral degenerative renal changes with nonobstructive nephrolithiasis.
- The urinary bladder wall thickening may be artifactual due to lack of full repletion or may be secondary to cystitis. Correlation with the patient's urinalysis and clinical history is recommended.
- The diffuse hepatic changes are non-specific and could be consistent with vacuolar hepatopathy, regenerative nodular hyperplasia, and/or age-related remodeling. Inflammatory and infiltrative disease are considered less likely. Correlation with the patient's liver values is recommended.
- The origin of the nodule on the left cranial quadrant is unclear. It may be a permanent lymph node, or may represent a pancreatic or mesenteric nodule, other. Its significance is unclear.
- The pyloric antral wall thickening could be consistent with an inflammatory process, hypertrophy, or emerging neoplasia.

INTERPRETATION OF THE FINDINGS & FURTHER RECOMMENDATIONS

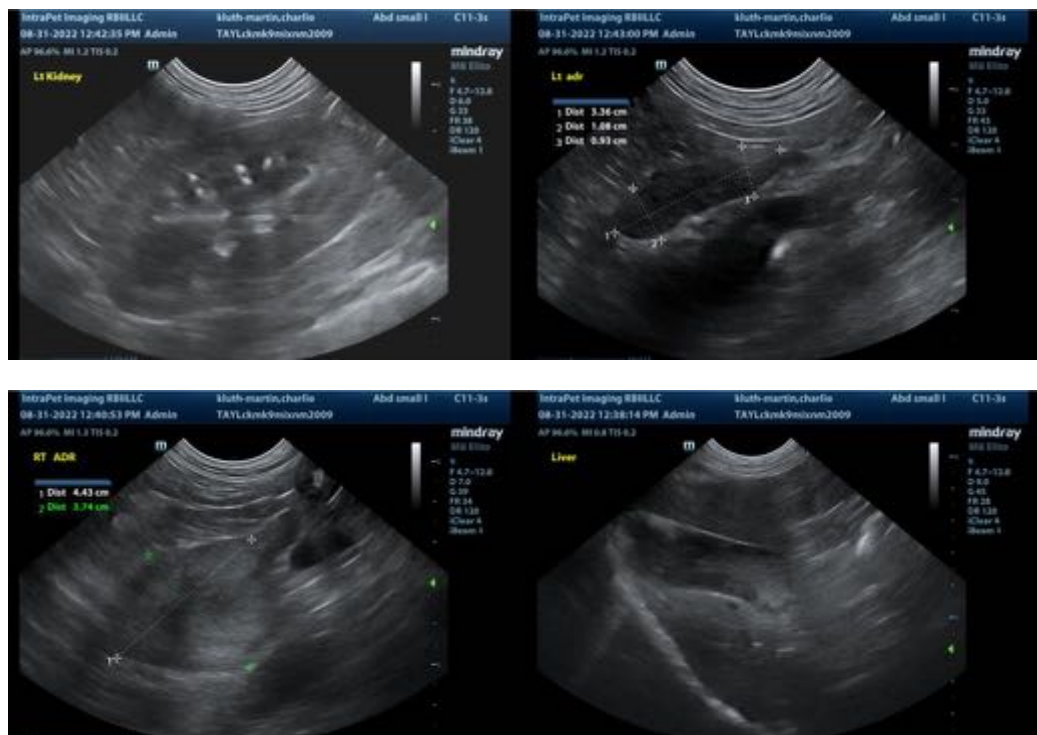
Regarding the right adrenal mass, consider the following:

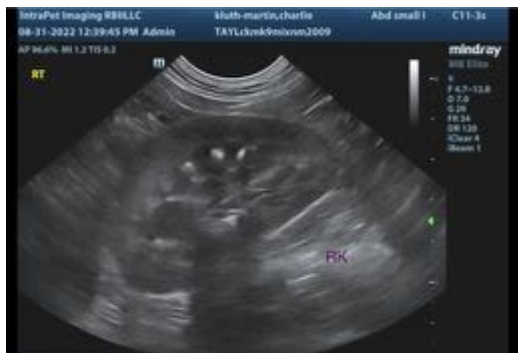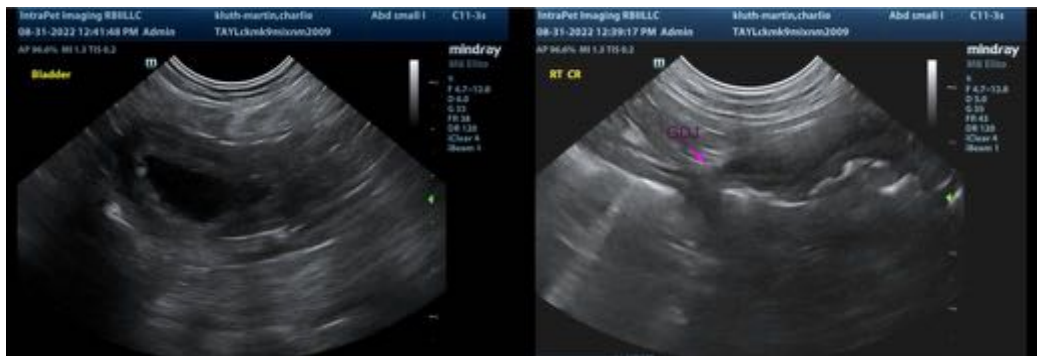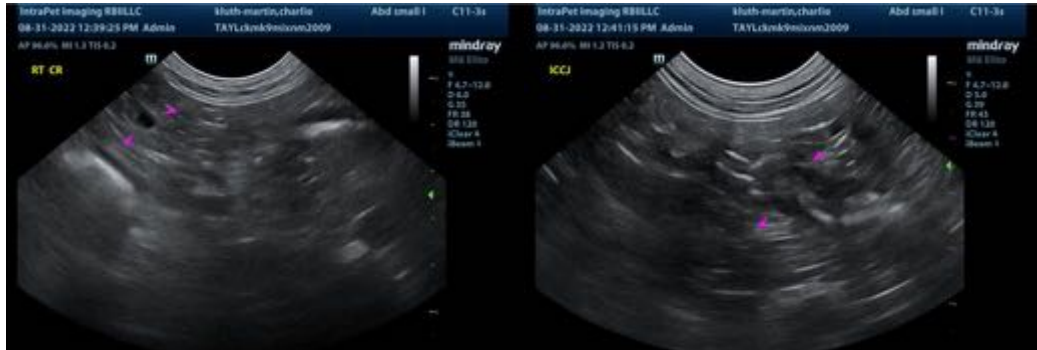1. Three-view thoracic radiographs are recommended to assess for pulmonary metastatic disease.
2. Baseline blood pressure measurement to evaluate for systemic hypertension
3. Further testing to determine if the tumor is functional (i.e., low-dose dexamethasone suppression test, urine/blood catecholamine levels).
4. An abdominal CT scan would be useful in assessing for vascular invasion, particularly if an adrenalectomy is a consideration.

Regarding the proteinuria, consider the following:

1. A urine culture and sensitivity
2. Initiation of an angiotensin receptor blocker
3. Initiation of omega 3 fatty acids
4. +/- transition to a prescription renal diet

Given the gall bladder changes, Ursodeoxycholic acid (Ursodiol) is recommended. Serial sonographic monitoring (e.g., every 6-8 weeks) of the gall bladder is recommended to assess for progression to a fully-formed mucocele.





The information and recommendations provided are based on the images presented by the referring veterinarian/sonographer. No evaluation can be communicated regarding pathology that was not visible in the image/video clips provided.

Thank you for this referral. If the clinical or image interpretation does not parallel your findings or if I can be of any further assistance, please contact me.

Andrea Nicastro, MPH, DVM, Diplomate DACVIM (Small Animal Internal Medicine)
info@SonoPath.com

