



**PATIENT**

Reagan Levine

**SPECIES**

Canine

**BREED**

Shih Tzu Mix

**SEX**

Female Spayed

**AGE**

1 year, 7 months

**WEIGHT**

12 lbs.

**INTERPRETED BY**

Andrea Nicastro, DVM,  
Diplomate ACVIM  
(*Small Animal Internal  
Medicine*)

**IMAGING  
PERFORMED BY**

Shari Reffi CVT

**HOSPITAL NAME**

Rockaway Animal  
Hospital

**REFERRING VET**

Dr. Maniar

**INVOICE**

11731kk

**DATE**

8/31/21

**PRESENTING CLINICAL SIGNS**

History: V+, lethargic x 24hr. Hx of dietary indiscretion.

Abnormal PE/Chem/CBC/UA Results: nsf

**ULTRASONOGRAPHIC EXAMINATION OF THE ABDOMEN**

*Urinary System*

The urinary bladder, trigone, and pelvic urethra are normal in thickness and the mucosal surface is smooth. The bladder lumen is moderately distended with anechoic urine. No masses, inflammatory changes or calculi are observed. Ureteral papillae and visualized portion of the proximal urethra, visible to a depth of 2 cm, are normal.

The left kidney is normal size (3.59 cm in length); normal shape and architecture with smooth peripheral margins. There is a normal 1:3 cortex to medulla ratio with normal corticomedullary distinction. There is no evidence of pyelectasia, nephroliths, infarcts or hydroureter. Renal vasculature is normal.

The right kidney is normal size (3.93 cm in length); normal shape and architecture with smooth peripheral margins. There is a normal 1:3 cortex to medulla ratio with normal corticomedullary distinction. There is no evidence of pyelectasia, nephroliths, infarcts or hydroureter. Renal vasculature is normal.

*Adrenal Glands*

The left adrenal gland is normal size (0.33 cm at cranial pole) (0.35 cm at caudal pole) (1.45 cm in length); normal shape; homogenous parenchyma. The glandular echogenicity and detail are unremarkable. Capsule, cortex, and medullary definition are normal. The phrenicoabdominal vein and surrounding vasculature are normal.

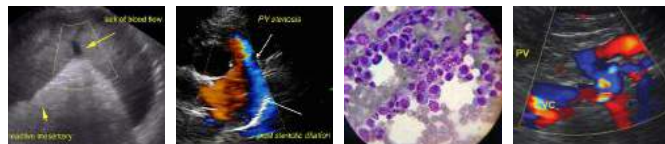
The right adrenal gland is normal size (0.72 cm at cranial pole) (0.55 cm at caudal pole) (1.29 cm in length); normal shape; homogenous parenchyma. The glandular echogenicity and detail are unremarkable. Capsule, cortex, and medullary definition are normal. The phrenicoabdominal vein and surrounding vasculature are normal.

*Spleen*

The spleen is normal in size (1.25 cm in width at the level of the hilus) with a normal capsular contour. There is appropriate echogenicity and echotexture. No focal lesions are observed. Splenic vasculature is normal.

*Liver*

The liver is subjectively normal in size with normal contours and structure. There is appropriate echogenicity and echotexture. No overt structural evidence of inflammatory, infiltrative, or regenerative pathology is evident. Vascular and biliary tracts are of normal volume with no evidence of congestion. No pathological hepatic lymphadenopathy observed. The gall bladder lumen is moderately distended. The wall is thin and smooth. Luminal contents are anechoic. The cystic and common bile ducts are normal/not seen.



**PATIENT**

Reagan Levine

**SPECIES**

Canine

**BREED**

Shih Tzu Mix

**SEX**

Female Spayed

**AGE**

1 year, 7 months

**WEIGHT**

12 lbs.

**INTERPRETED BY**

Andrea Nicastro, DVM,  
Diplomate ACVIM  
(Small Animal Internal  
Medicine)

**IMAGING PERFORMED BY**

Shari Reffi CVT

**HOSPITAL NAME**

Rockaway Animal  
Hospital

**REFERRING VET**

Dr. Maniar

**INVOICE**

11731kk

**DATE**

8/31/21

**Gastrointestinal**

The stomach and intestine are free of stasis and exhibit normal peristaltic activity. The gastric lumen is not distended. The gastric wall and pylorus are normal in thickness with a normal layering pattern. The pyloric outflow tract is patent. The small intestinal lumen is not dilated. The small intestinal wall thickness is normal with a normal layering pattern and appropriate mural detail. Discreet masses are not identified. The colonic wall is normal. No obstructive disease is noted.

**Pancreas**

The pancreas is normal in size with normal peripheral contours. The pancreatic duct is normal. The base and limbs of the pancreas are isoechoic to surrounding omental fat. No focal lesions are observed. There is no evidence of peripancreatic inflammation or effusion.

**Free Abdomen**

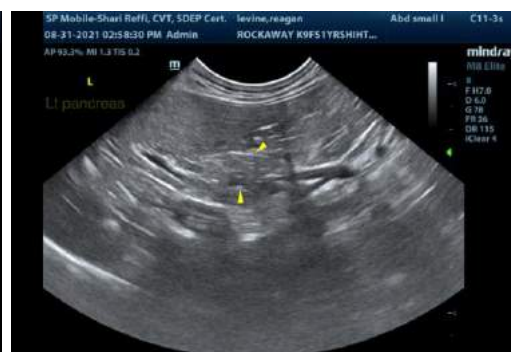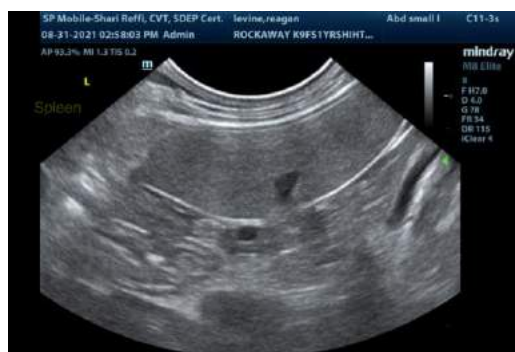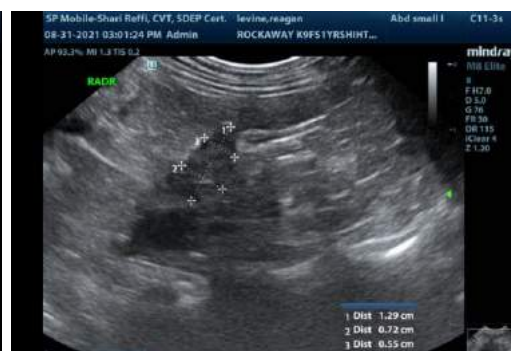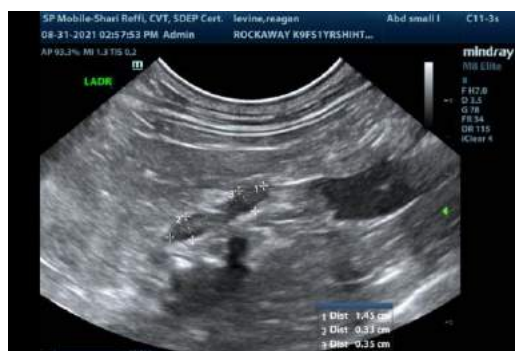The peritoneal cavity is normal. There is no evidence of inflammation or effusion. A 0.53 cm epigastric lymph node is visualized.

**ULTRASONOGRAPHIC FINDINGS**

- The prominent epigastric lymph node is most likely reactive. The remainder of the abdomen is unremarkable. There is no obvious evidence of a foreign body/obstruction. Acute gastroenteritis is suspected.

**INTERPRETATION OF THE FINDINGS & FURTHER RECOMMENDATIONS**

- Supportive care for acute gastroenteritis is recommended. If clinical signs persist despite medical management, a more advanced GI work up may be warranted.





**PATIENT**

Reagan Levine

**SPECIES**

Canine

**BREED**

Shih Tzu Mix

**SEX**

Female Spayed

**AGE**

1 year, 7 months

**WEIGHT**

12 lbs.

**INTERPRETED BY**

Andrea Nicastro, DVM,  
Diplomate ACVIM  
(Small Animal Internal  
Medicine)

**IMAGING  
PERFORMED BY**

Shari Reffi CVT

**HOSPITAL NAME**

Rockaway Animal  
Hospital

**REFERRING VET**

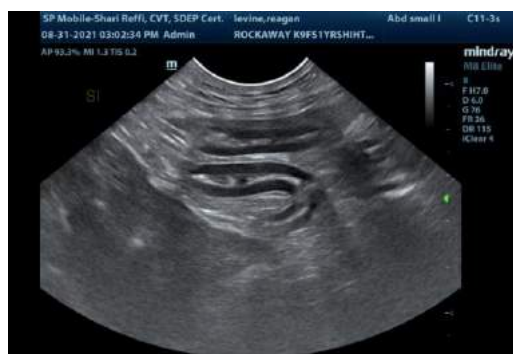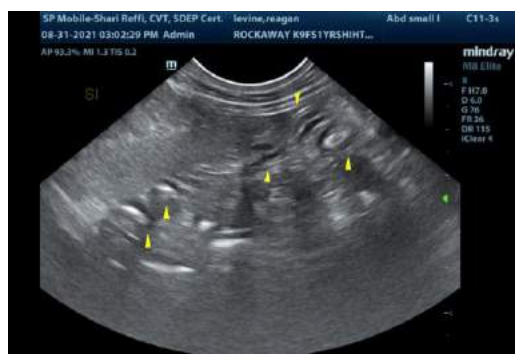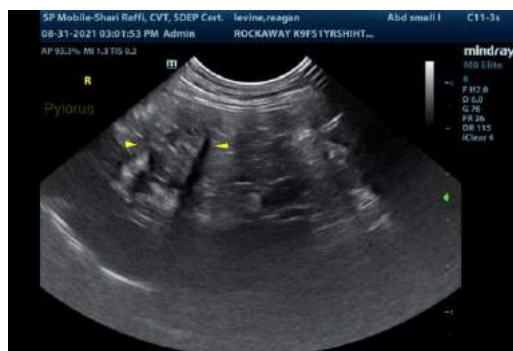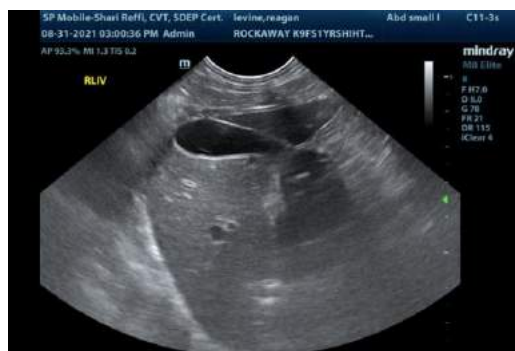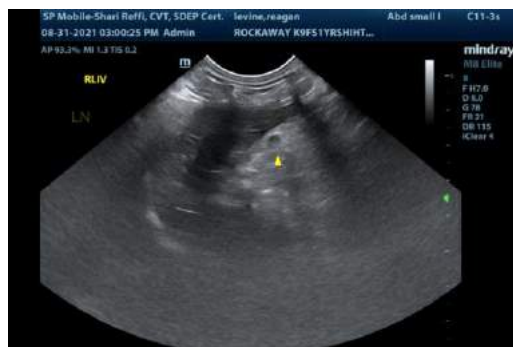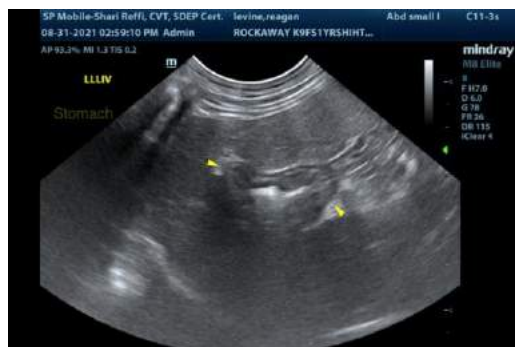Dr. Maniar

**INVOICE**

11731kk

**DATE**

8/31/21



The information and recommendations provided are based on the images presented by the referring veterinarian. No evaluation can be communicated regarding pathology that was not visible in the image/video clips provided.

Thank you for this referral. If the clinical or image interpretation does not parallel your findings or if I can be of any further assistance, please contact me.

Andrea Nicastro, DVM, Diplomate ACVIM (Small Animal Internal Medicine)  
Andrea.nicastro@sonopath.com