

**DATE PRESENTING CLINICAL SIGNS**

8/31/21 History: Severely elevated ALP, ALT, AST, GGT noted on routine blood work. No clinical signs noted.

PATIENT Current Medications: None.

Oliver Claypool Lab Results: BUN is 50. ALP is 2287, ALT is 857, GGT is 80. Total bilirubin is normal. T4 is normal. 4DX is negative. CBC shows thrombocytosis.

SPECIES Date of Previous IntraPet Ultrasound: No previous

Canine Sedation: Not needed.

BREED Stat Report: Not requested.

Maltese Mix

ULTRASONOGRAPHIC EXAMINATION OF THE ABDOMEN**SEX**
Urinary System

Male Neutered The urinary bladder is moderately distended. The wall is normal in thickness with a smooth mucosal surface. Several small cystic calculi are visualized. The region of the trigone and the visible portion of the portion of the proximal urethra are normal.

AGE

2008 The prostate is normal in size (0.86 cm in width) with a normal shape and smooth peripheral contours. The parenchyma is homogenous. A hyperechoic to mineralized focus is suspected within the prostatic urethra; however, the urethra is not overtly dilated.

WEIGHT

16.2 lbs. The left kidney is normal size (4.97 cm in length) with a normal shape and smooth peripheral contours. The cortex is mildly thickened and there is moderate loss of corticomedullary distinction. Numerous, small cortical cysts are present. Several nephroliths are seen. There is no evidence of pyelectasia, infarcts or hydroureter. Renal vasculature is normal.

INTERPRETED BY

Andrea Nicastro, DVM,
Diplomate ACVIM
(Small Animal Internal
Medicine)

The right kidney is normal size (4.35 cm in length) with a slightly irregular shape. The cortex is mildly thickened and there is moderate loss of corticomedullary distinction. Numerous, small cortical cysts are present. Several nephroliths are seen. There is no evidence of pyelectasia, infarcts or hydroureter. Renal vasculature is normal.

HOSPITAL NAME

Festival Veterinary
Clinic

Adrenal Glands

The left adrenal gland is normal size (0.49 cm at cranial pole) (0.41 cm at caudal pole) (2.02 cm in length); normal shape; homogenous parenchyma. The glandular echogenicity and detail are unremarkable. Capsule, cortex, and medullary definition are normal. The phrenicoabdominal vein and surrounding vasculature are normal.

REFERRING VET

Dr. Prange

The right adrenal gland is normal size (0.50 cm at cranial pole) (0.48 cm at caudal pole) (1.67 cm in length); normal shape; homogenous parenchyma. The glandular echogenicity and detail are unremarkable. Capsule, cortex, and medullary definition are normal. The phrenicoabdominal vein and surrounding vasculature are normal.

INVOICE

11735kk

Spleen

The spleen is normal in size (0.98 cm in width at the level of the hilus) with a normal capsular contour. There is appropriate echogenicity and echotexture. No focal lesions are observed. Splenic vasculature is normal.

Liver

The liver is subjectively prominent in size with rounded to irregular peripheral contours. The parenchyma is isoechoic relative to the spleen. Irregular, hyperechoic nodules/masses, the largest measuring 4.84 cm in diameter) are observed throughout the parenchyma. An approximately 3 cm hyperechoic to mottled cystic area/mass is observed deep on the left side. Hepatic vasculature and intrahepatic biliary tracts are of normal volume with no evidence of congestion. The gall bladder lumen is moderately distended. The wall is thin and smooth. A small amount of suspended echogenic debris is observed within the lumen. The cystic and common bile ducts are normal/not seen.

Gastrointestinal

The stomach and intestine are free of stasis and exhibit normal peristaltic activity. The gastric lumen is not distended. The gastric wall and pylorus are normal in thickness with a normal layering pattern. The pyloric outflow tract is patent. The small intestinal lumen is not dilated. The small intestinal wall thickness is normal with a normal layering pattern and appropriate mural detail. Discreet masses are not identified. The colonic wall is normal. No obstructive disease is noted.

Pancreas

The pancreas is normal in size with normal peripheral contours. The pancreatic duct is normal. The base and limbs of the pancreas are isoechoic to surrounding omental fat. No focal lesions are observed. There is no evidence of peripancreatic inflammation or effusion.

Free Abdomen

There is no evidence of free fluid. The abdominal lymph nodes are normal/not visible.

ULTRASONOGRAPHIC FINDINGS

Primary Findings:

- The cystic hepatic area/mass is concerning for a neoplastic process (i.e., hemangiosarcoma). However, a benign process cannot be excluded. The hyperechoic hepatic nodules/masses trend towards the benign (i.e., regenerative nodules) with a lower possibility of infiltrative neoplasia.
- Gall bladder debris- incidental, non-mucocele.
- Cystic calculi.

Secondary Findings:

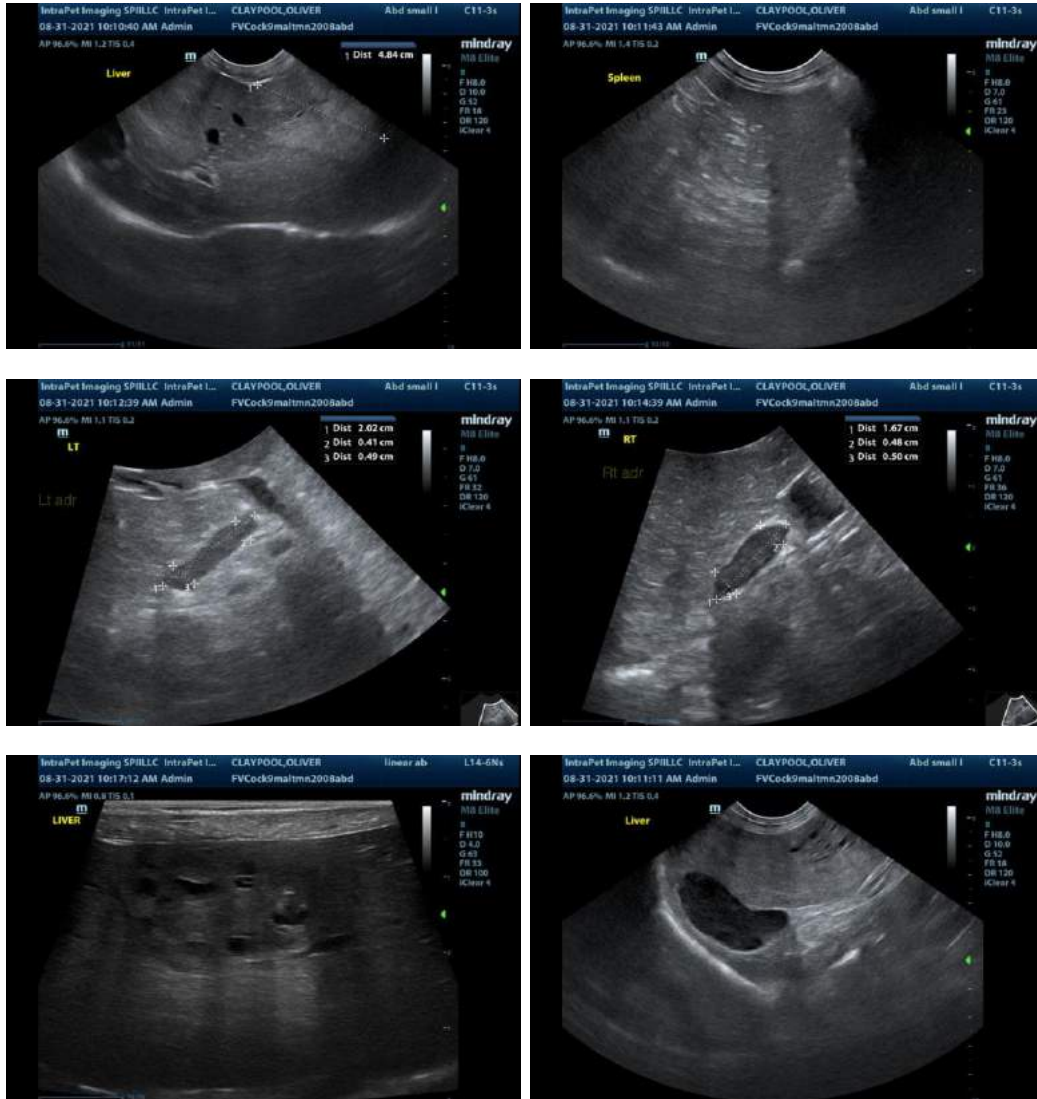
- Bilateral, age-related renal changes with non-obstructive nephroliths and cortical cysts.
- Suspected mineralization within the prostatic urethra, non-obstructive.

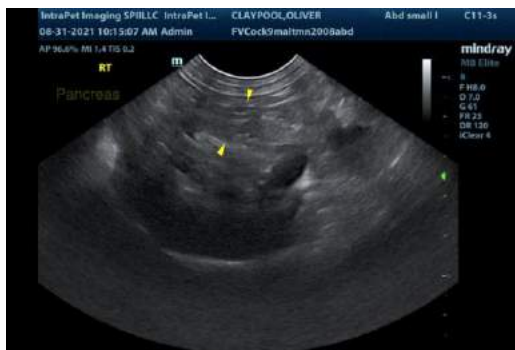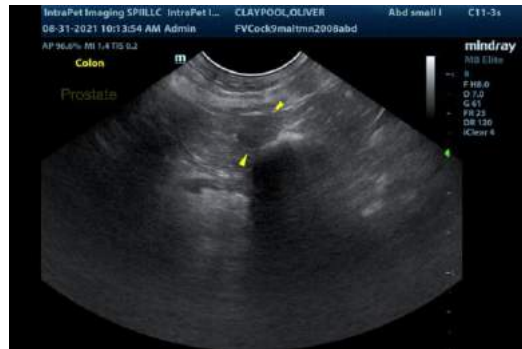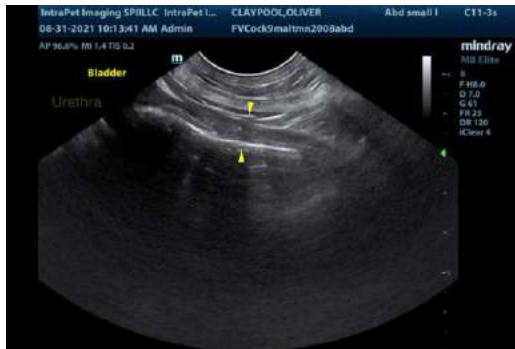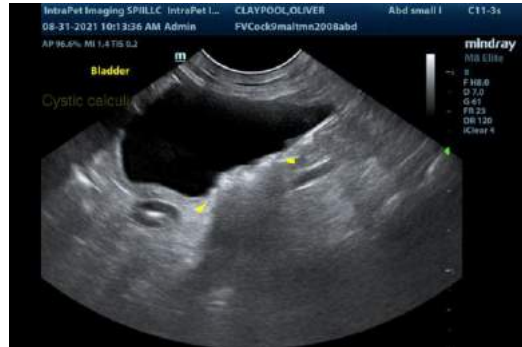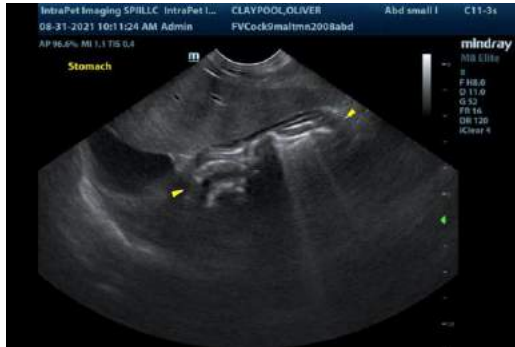INTERPRETATION OF THE FINDINGS & FURTHER RECOMMENDATIONS

1. Three-view thoracic radiographs are recommended to assess for pulmonary metastases.
2. If an aggressive approach is desired, an abdominal exploratory with hepatic biopsies should be considered. If surgery is pursued, a cystotomy with stone removal analysis and culture is also recommended.
3. If a conservative approach is desired, consider empirical treatment for bacterial cholangiohepatitis (amoxicillin-clavulanic acid, Denamarin Advanced). If no improvement in the liver values is seen

within 7-10 days of initiating therapy, antibiotics should be discontinued, and hepatic tissue sampling reconsidered. If liver values improve, continue therapy for at least 4-6 weeks and 1 week beyond normalization of the liver values.

4. Also consider Leptospirosis testing (i.e., blood and urine PCR, serology)





The information and recommendations provided are based on the images presented by the referring veterinarian. No evaluation can be communicated regarding pathology that was not visible in the image/video clips provided.

Thank you for this referral. If the clinical or image interpretation does not parallel your findings or if I can be of any further assistance, please contact me.

Andrea Nicastro, DVM, Diplomate ACVIM (*Small Animal Internal Medicine*)
 Andrea.nicastro@sonopath.com