



**PATIENT**

Cocoa Anderson

**SPECIES**

Canine

**BREED**

Mixed Breed

**SEX**

Female spayed

**AGE**

8 Years

**WEIGHT**

76 lbs.

**INTERPRETED BY**

Andrea Nicastro, DVM,  
Diplomate ACVIM  
(*Small Animal Internal  
Medicine*)

**IMAGING  
PERFORMED BY**

Jessica Miller

**HOSPITAL NAME**

North Warren Animal  
Hospital

**REFERRING VET**

Dr. Corrado

**INVOICE**

11979

**DATE**

8/31/21

**PRESENTING CLINICAL SIGNS**

History: Bunched up gas filled pattern in small intestine on radiographs. Gas issues and previously not eating.

The patient is sedated for the sonogram. Abdominal radiographs show diffuse gas within the small intestine.

**ULTRASONOGRAPHIC EXAMINATION OF THE ABDOMEN**

*Urinary System*

The urinary bladder, trigone, and pelvic urethra are normal in thickness and the mucosal surface is smooth. The bladder lumen is moderately distended with anechoic urine. No masses, inflammatory changes or calculi are observed. Ureteral papillae and visualized portion of the proximal urethra, visible to a depth of 2 cm, are normal.

The left kidney is normal size (6.63 cm in length); normal shape and architecture with smooth peripheral margins. There is a normal 1:3 cortex to medulla ratio with normal corticomedullary distinction. There is no evidence of pyelectasia, nephroliths, infarcts or hydronephrosis. Renal vasculature is normal.

The right kidney is normal size (7.10 cm in length); normal shape and architecture with smooth peripheral margins. There is a normal 1:3 cortex to medulla ratio with normal corticomedullary distinction. There is no evidence of pyelectasia, nephroliths, infarcts or hydronephrosis. Renal vasculature is normal.

*Adrenal Glands*

The left adrenal gland is normal size (0.61 cm at cranial pole) (0.64 cm at caudal pole) (2.86 cm in length); normal shape; homogenous parenchyma. The glandular echogenicity and detail are unremarkable. Capsule, cortex, and medullary definition are normal. The phrenicoabdominal vein and surrounding vasculature are normal.

The right adrenal gland is normal size (0.82 cm at cranial pole) (0.67 cm at caudal pole) (2.29 cm in length); normal shape; homogenous parenchyma. The glandular echogenicity and detail are unremarkable. Capsule, cortex, and medullary definition are normal. The phrenicoabdominal vein and surrounding vasculature are normal.

*Spleen*

The spleen is normal in size (2.44 cm in width at the level of the hilus) with a normal capsular contour. There is appropriate echogenicity and echotexture. No focal lesions are observed. Splenic vasculature is normal.

*Liver*

The liver is subjectively normal in size with normal contours and structure. There is appropriate echogenicity and echotexture. No overt structural evidence of inflammatory, infiltrative, or regenerative pathology is evident. Vascular and biliary tracts are of normal volume with no evidence of congestion. No pathological hepatic lymphadenopathy observed. The gall bladder lumen is moderately distended. The wall is thin and smooth. Luminal contents are anechoic. The cystic and common bile ducts are normal/not seen.



**PATIENT**

Cocoa Anderson

**SPECIES**

Canine

**BREED**

Mixed Breed

**SEX**

Female spayed

**AGE**

8 Years

**WEIGHT**

76 lbs.

**INTERPRETED BY**

Andrea Nicastro, DVM,  
Diplomate ACVIM  
(*Small Animal Internal  
Medicine*)

**IMAGING  
PERFORMED BY**

Jessica Miller

**HOSPITAL NAME**

North Warren Animal  
Hospital

**REFERRING VET**

Dr. Corrado

**INVOICE**

11979

**DATE**

8/31/21

***Gastrointestinal***

The stomach and intestine are free of stasis and exhibit normal peristaltic activity. The gastric lumen is not distended. The gastric wall and pylorus are normal in thickness with a normal layering pattern. The pyloric outflow tract is patent. The small intestinal lumen is segmentally dilated with chyme (mild). The small intestinal wall thickness is normal with a normal layering pattern and appropriate mural detail. Discreet masses are not identified. The colonic wall is normal. No obstructive disease is noted.

***Pancreas***

The region of the pancreas is isoechoic relative to surrounding omental fat. No obvious parenchymal abnormalities are observed. There is no evidence of regional inflammation or effusion.

***Free Abdomen***

The peritoneal cavity is normal. There is no evidence of inflammation or effusion. The abdominal lymph nodes are normal/not visible.

**ULTRASONOGRAPHIC FINDINGS**

- Unremarkable abdomen.

\*An obvious cause for the patient's clinical signs is not identified in this study. Considerations include microscopic gastrointestinal or pancreatic disease, underlying metabolic issue, other.

**INTERPRETATION OF THE FINDINGS & FURTHER RECOMMENDATIONS**

- Three-view thoracic radiographs are recommended to assess for occult esophageal disease.
- Other diagnostic considerations include the following:
  1. Baseline labwork including a CBC chemistry panel, urinalysis and T4, if not already performed.
  2. A fecal evaluation for ova/Giardia
  3. Serum cobalamin, folate, PLI and TLI
  4. A resting cortisol level to screen for hypoadrenocorticism. If resting cortisol level is < 2.0 mcg/dL, an ACTH stimulation test is recommended
- Depending on the results of the above diagnostics, endoscopic or surgical gastrointestinal biopsies may be necessary to get a definitive diagnosis.



**PATIENT**

Cocoa Anderson

**SPECIES**

Canine

**BREED**

Mixed Breed

**SEX**

Female spayed

**AGE**

8 Years

**WEIGHT**

76 lbs.

**INTERPRETED BY**

Andrea Nicastro, DVM,  
Diplomate ACVIM  
(Small Animal Internal  
Medicine)

**IMAGING  
PERFORMED BY**

Jessica Miller

**HOSPITAL NAME**

North Warren Animal  
Hospital

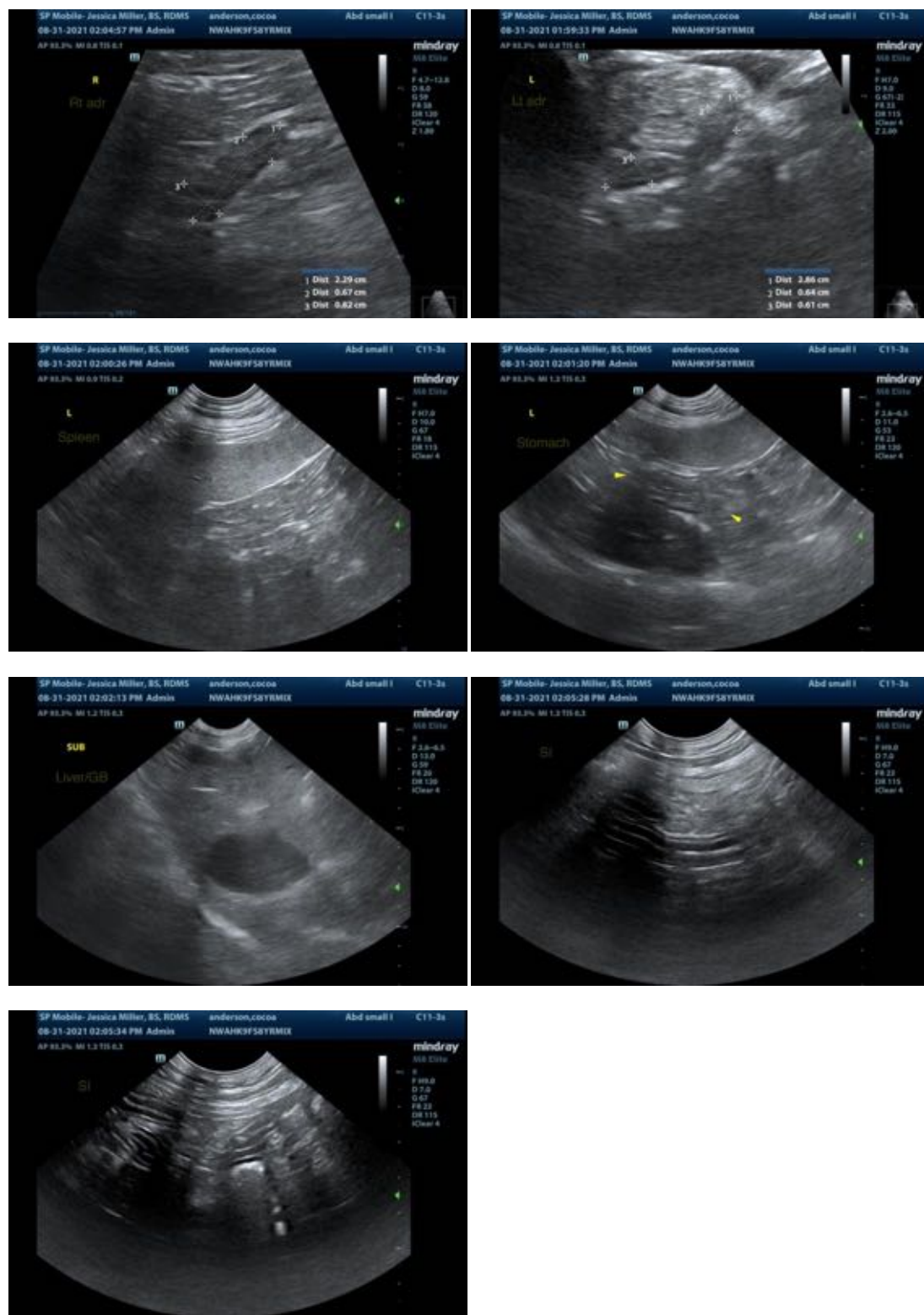
**REFERRING VET**

Dr. Corrado

**INVOICE**

11979

**DATE**  
8/31/21



The information and recommendations provided are based on the images presented by the referring veterinarian. No evaluation can be communicated regarding pathology that was not visible in the image/video clips provided.



**PATIENT**

Cocoa Anderson

Thank you for this referral. If the clinical or image interpretation does not parallel your findings or if I can be of any further assistance, please contact me.

**SPECIES**

Canine

Andrea Nicastro, DVM, Diplomate ACVIM (*Small Animal Internal Medicine*)  
Andrea.nicastro@sonopath.com

**BREED**

Mixed Breed

**SEX**

Female spayed

**AGE**

8 Years

**WEIGHT**

76 lbs.

**INTERPRETED BY**

Andrea Nicastro, DVM,  
Diplomate ACVIM  
(*Small Animal Internal  
Medicine*)

**IMAGING  
PERFORMED BY**

Jessica Miller

**HOSPITAL NAME**

North Warren Animal  
Hospital

**REFERRING VET**

Dr. Corrado

**INVOICE**

11979

**DATE**

8/31/21