

**DATE PRESENTING CLINICAL SIGNS**

8/30/21

History: Hx of vomiting, some diarrhea, diagnosed with thyroid disease on 7/18/21. Not tolerating methimazole or Felimazole. Changed to transdermal ear gel on 8/26/21.

PATIENT

Paddykins Devine

Current Medications: Methimazole (Lipoderm) 5 mg SID, Proviablen forte.

Lab Results: CBC chem is normal.

SPECIES

Feline

Radiographs: Not provided by the veterinarian.

Date of Previous IntraPet Ultrasound: No previous IntraPet scans.

BREED

Domestic Shorthair

Sedation: not needed

Stat Report: not requested

SEX

Female Spayed

ULTRASONOGRAPHIC EXAMINATION OF THE ABDOMEN**AGE**

1/8/08

Urinary System

The urinary bladder, trigone, and pelvic urethra are normal in thickness and the mucosal surface is smooth. The bladder lumen is moderately distended with anechoic urine. No masses, inflammatory changes or calculi are observed. Ureteral papillae and visualized portion of the proximal urethra, visible to a depth of 2 cm, are normal.

WEIGHT

7.4 lbs.

The left kidney is normal size (3.62 cm in length); normal shape and architecture with smooth peripheral margins. There is a normal 1:3 cortex to medulla ratio with minimal loss of corticomedullary distinction. There is no evidence of pyelectasia, nephroliths, infarcts or hydronephrosis. Renal vasculature is normal.

INTERPRETED BY

Andrea Nicastro, DVM,
Diplomate ACVIM
(Small Animal Internal
Medicine)

The right kidney is normal size (3.51 cm in length); normal shape and architecture with smooth peripheral margins. There is a normal 1:3 cortex to medulla ratio with minimal loss of corticomedullary distinction. There is no evidence of pyelectasia, nephroliths, infarcts or hydronephrosis. Renal vasculature is normal.

HOSPITAL NAME

Animal Medical Center
of Dulane Valley

Adrenal Glands

The left adrenal gland is normal size (0.38 cm width). Normal shape and glandular echogenicity. The phrenicoabdominal vein and surrounding vasculature are normal.

The right adrenal gland is normal size (0.29 cm width). Normal shape and glandular echogenicity. The phrenicoabdominal vein and surrounding vasculature are normal.

REFERRING VET

Dr. Chrest

Spleen

The spleen is prominent in size (1.01 cm in width at the level of the hilus) with slight swollen peripheral contours. The parenchyma is subtly mottled in appearance. No distinct focal lesions are observed. Splenic vasculature is normal with no evidence of thrombosis.

INVOICE

11724kk

Liver

The liver is subjectively normal in size with normal contours and structure. There is appropriate echogenicity and echotexture. No overt structural evidence of inflammatory, infiltrative, or regenerative pathology is evident. Vascular and biliary tracts are of normal volume with no evidence of congestion. No pathological hepatic lymphadenopathy observed. The gall bladder lumen is moderately distended. The wall is normal in thickness. Luminal contents are anechoic. The cystic and common bile ducts are visible/tortuous but not overtly dilated. The common bile duct measures 0.27 cm in diameter at the distal aspect. The duodenal papilla is normal in thickness (0.39 cm in width).

Gastrointestinal

The gastric lumen is not distended. The gastric wall and pylorus are normal in thickness with a normal layering pattern. The pyloric outflow tract is patent. A 2.27 x 2.14 cm hypoechoic mass is arising from the duodenum, just distal to the duodenal papilla. Surrounding mesentery is hyperechoic. The remaining small intestinal segments are normal in thickness with a normal layering pattern and appropriate mural detail. The ileocolic junction and colonic wall are normal. There is no obvious evidence of an obstructive pattern.

Pancreas

The pancreas is diffusely prominent in size with minimal deviation from the normal peripheral contours. The parenchyma is hypoechoic relative to surrounding omental fat and mildly heterogeneous in appearance. No distinct focal lesions are observed. The pancreatic duct is dilated (0.35 cm in diameter). The mesentery effacing the serosal surface is hyperechoic.

Free Abdomen

There is no evidence of free fluid. A 1.22 x 0.99 cm hypoechoic lymph node is observed just caudal to the right kidney. Surrounding mesentery is hyperechoic. In addition, a few visible lymph nodes are observed in the right cranial quadrant.

ULTRASONOGRAPHIC FINDINGS

Primary Findings:

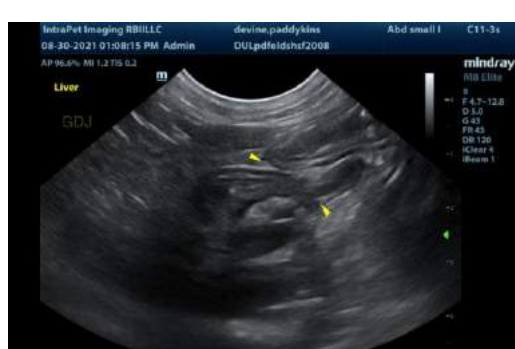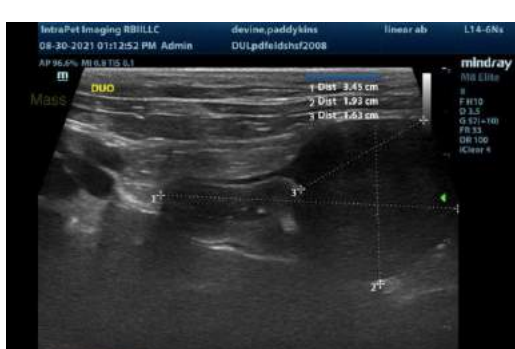
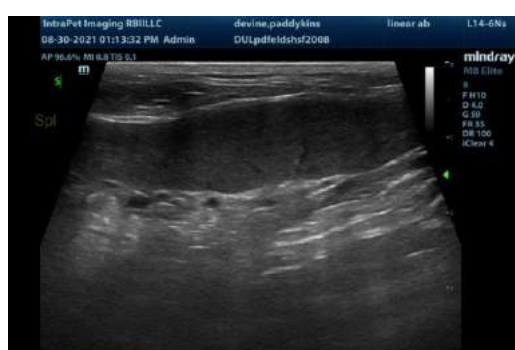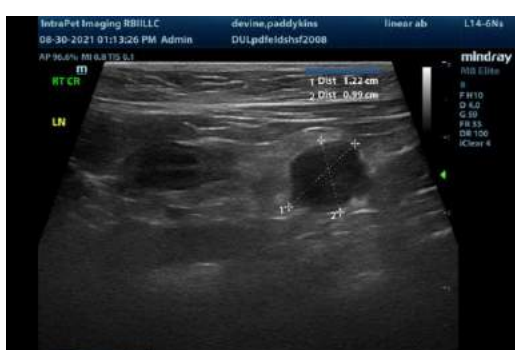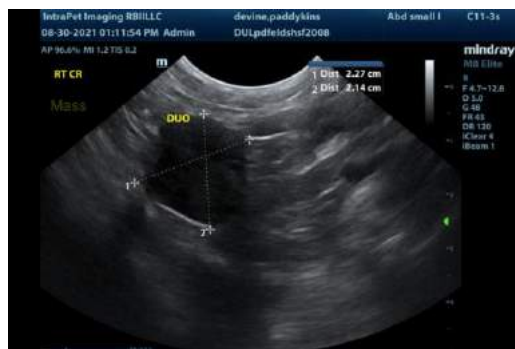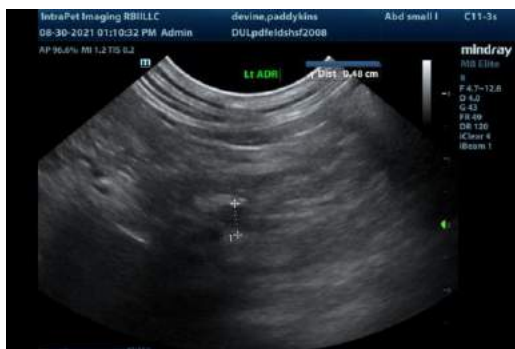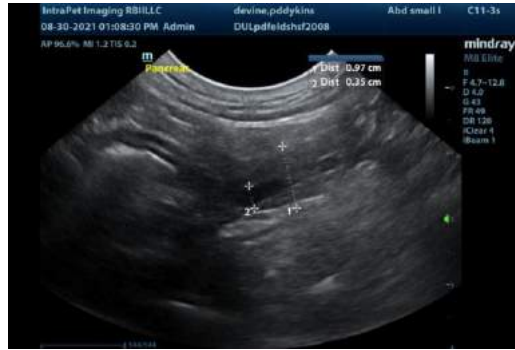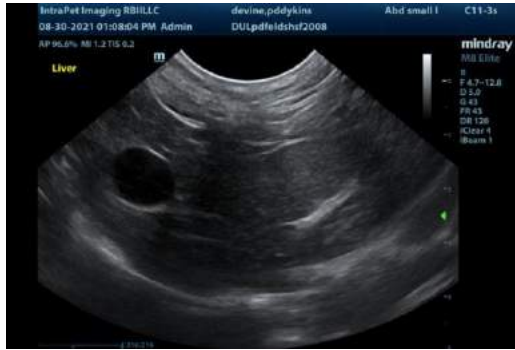- Proximal duodenal mass. Neoplasia (i.e., lymphoma, adenocarcinoma) is considered likely with a lower possibility of benign pathology (i.e., pyogranuloma). Regional peritonitis is present.
- The pancreatic changes are consistent with chronic active pancreatitis.
- The prominent abdominal lymph nodes could be consistent with reactive lymphadenitis, lymphoid hyperplasia, or infiltrative neoplasia.
- The splenic parenchymal changes could be consistent with benign pathology (i.e., extramedullary hematopoiesis or lymphoid hyperplasia). However, infiltrative neoplasia (i.e., round cell tumor) cannot be completely excluded.

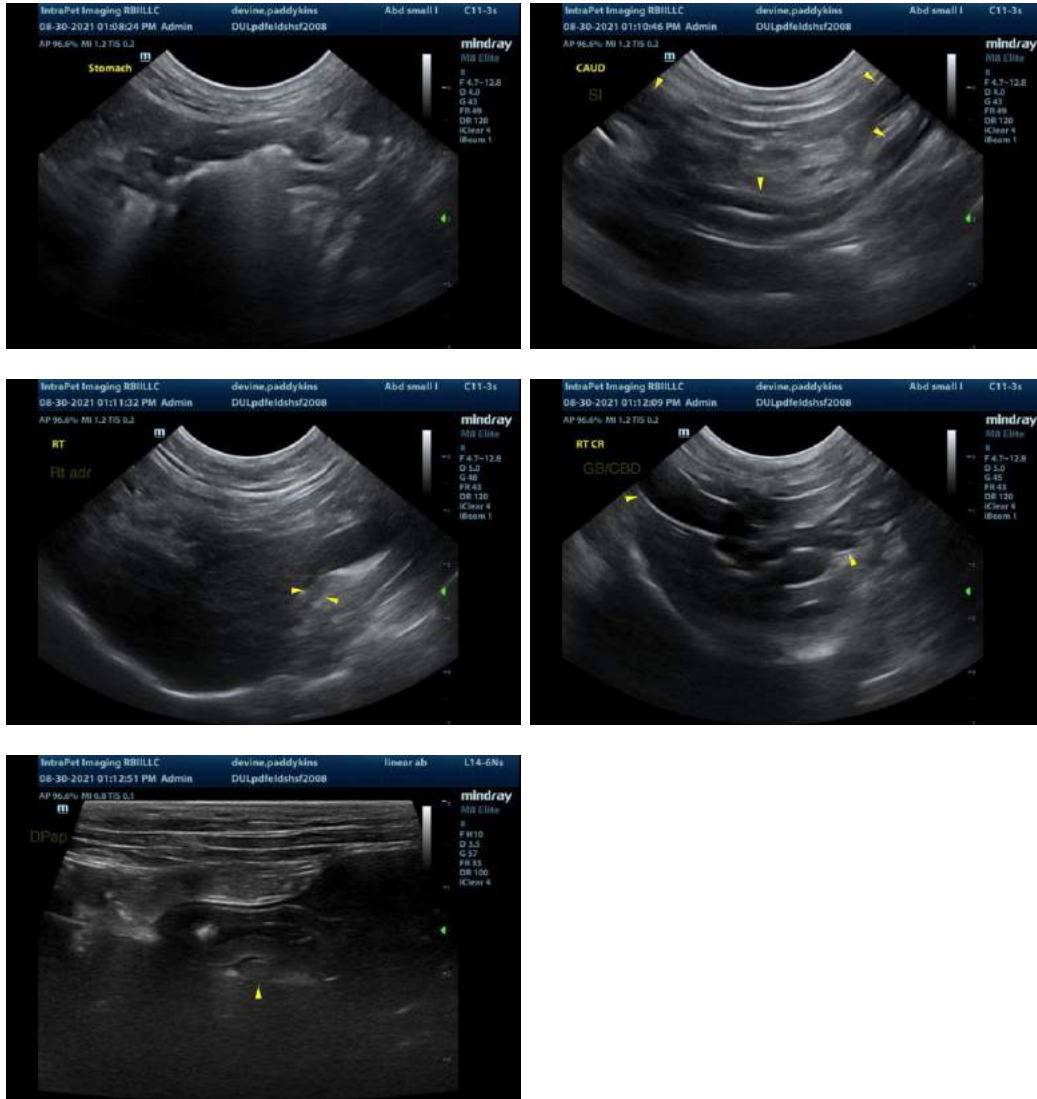
Secondary Findings:

- Minor, age-related renal changes.

INTERPRETATION OF THE FINDINGS & FURTHER RECOMMENDATIONS

1. Three-view thoracic radiographs are recommended to assess for pulmonary metastases.
2. A fine needle aspirate of the duodenal mass is recommended if accessible (if clotting status is appropriate). A 25-gauge needle should be used. If cytologic evaluation is inconclusive or if the lesion is not accessible for aspiration, an abdominal exploratory with duodenal mass removal and submission for histopathology is recommended to get a definitive diagnosis.
3. Also consider a malabsorption panel including serum cobalamin, folate, PLI and TLI.





The information and recommendations provided are based on the images presented by the referring veterinarian. No evaluation can be communicated regarding pathology that was not visible in the image/video clips provided.

Thank you for this referral. If the clinical or image interpretation does not parallel your findings or if I can be of any further assistance, please contact me.

Andrea Nicastro, DVM, Diplomate ACVIM (*Small Animal Internal Medicine*)
 Andrea.nicastro@sonopath.com