

**DATE PRESENTING CLINICAL SIGNS**

8/30/21

History: Previously cat was diagnosed for hyperthyroidism but not anymore, current complaint is anorexia and vomiting. BW indicated elevated pancreatic enzymes x-rays showed no obvious mass.

**PATIENT**

Molly Walz

Current Medications: Cerenia 16 mg tablet 1/2 PO daily for 4 days, i/d low fat diet, Convenia inj. was given today.

**SPECIES**

Feline

Lab Results: Elevated pancreatic enzymes.

Radiographs: Showed no obvious mass.

**BREED**

Domestic Shorthair

Date of Previous IntraPet Ultrasound: No previous IntraPet scans.

Sedation: not needed

**SEX**

Female Spayed

Stat Report: not requested

**ULTRASONOGRAPHIC EXAMINATION OF THE ABDOMEN****AGE**

6/25/05

**Urinary System**

The urinary bladder, trigone, and pelvic urethra are normal in thickness and the mucosal surface is smooth. The bladder lumen is moderately distended with mostly anechoic urine. No masses, inflammatory changes or calculi are observed. Ureteral papillae and visualized portion of the proximal urethra, visible to a depth of 2 cm, are normal.

**WEIGHT**

8.13 lbs.

The left kidney is normal size (3.05 cm in length) with a slightly irregular shape. There is mild loss of corticomedullary distinction. Several hyperechoic shadowing diverticular foci are observed. There is no evidence of pyelectasia, or hydronephrosis. Renal vasculature is normal.

**INTERPRETED BY**

Andrea Nicastro, DVM,  
 Diplomate ACVIM  
 (Small Animal Internal  
 Medicine)

The right kidney is subjectively normal size (3.62 cm in length) with a slightly irregular shape. There is a normal 1:3 cortex to medulla ratio with minimal to mild loss of corticomedullary distinction. There is no evidence of pyelectasia, nephroliths, infarcts or hydroureter. Renal vasculature is normal.

**HOSPITAL NAME**

Glen Burnie Animal  
 Hospital

**Adrenal Glands**

The left adrenal gland is borderline enlarged (0.56 cm width) with a normal shape, glandular echogenicity, and detail. Surrounding vasculature appears normal.

The right adrenal gland is normal size (0.52 cm width). Normal shape and glandular echogenicity. The phrenicoabdominal vein and surrounding vasculature are normal.

**REFERRING VET**

Dr. Shah

**Spleen**

The spleen is normal in size (0.83 cm in width at the level of the hilus) with a normal capsular contour. There is appropriate echogenicity and echotexture. No focal lesions are observed. Splenic vasculature is normal.

**INVOICE**

11726kk

**Liver**

The liver is subjectively normal in size with normal curvilinear peripheral contours. The parenchyma is hypoechoic relative to the spleen with minor changes consistent with age-related remodeling. No focal lesions are observed. Hepatic vasculature and biliary tracts are of normal volume with no evidence of congestion. The gall bladder lumen is moderately distended. The wall is thin and smooth. Luminal contents are anechoic. The cystic and common bile ducts are normal.

### ***Gastrointestinal***

The stomach and intestine are free of stasis and exhibit normal peristaltic activity. The gastric lumen is not distended. The gastric wall and pylorus are normal in thickness with a normal layering pattern. The pyloric outflow tract is patent. The small intestinal lumen is not dilated. The duodenal and jejunal walls are thickened (up to 0.44 cm) with a normal layering pattern and appropriate mural detail. There is disruption in the normal 1:3 muscularis to mucosal ratio with a > 1:1 ratio in some segments. Discreet masses are not identified. The distal ileal wall is thickened (up to 0.55 cm) with a prominent muscularis layer and retention of the normal layering pattern. The colonic wall is normal. There is no evidence of an obstructive pattern.

### ***Pancreas***

The right limb of the pancreas is visible/prominent with normal curvilinear peripheral contours. The parenchyma is hypoechoic relative to surrounding omental fat. The pancreatic duct is visible but not overtly dilated (0.14 cm in diameter). There is no evidence of peripancreatic inflammation or effusion.

### ***Free Abdomen***

Trace free fluid is observed. A > 6 cm mass-effect is infiltrating the mesenteric root lymph nodes. In addition, a 1.30 cm lymph node is observed in the cranial abdomen. The mesentery surrounding the enlarged lymph nodes is hyperechoic.

## **ULTRASONOGRAPHIC FINDINGS**

### **Primary Findings:**

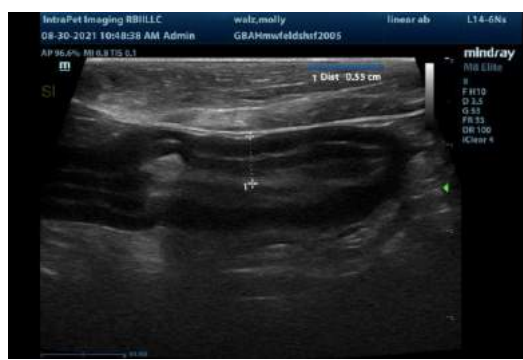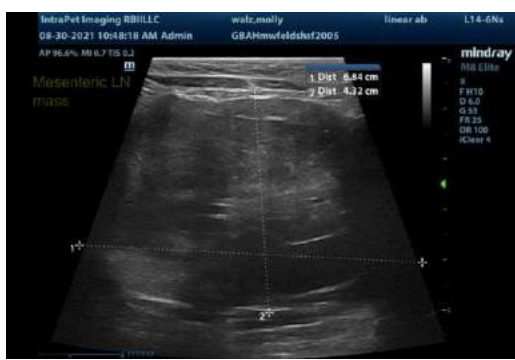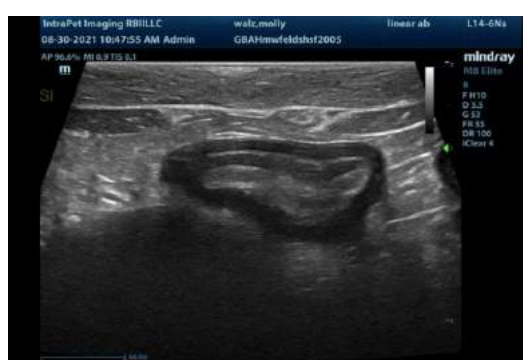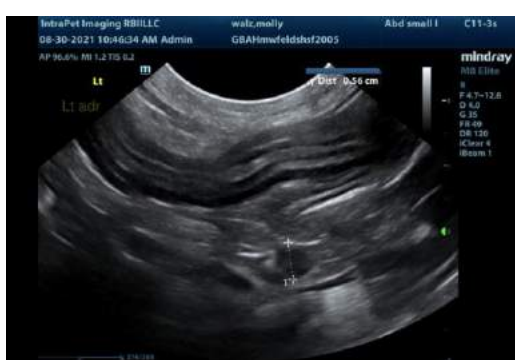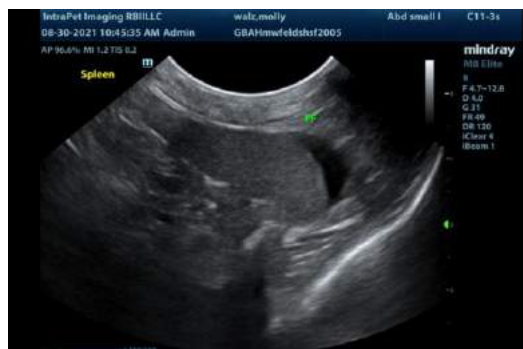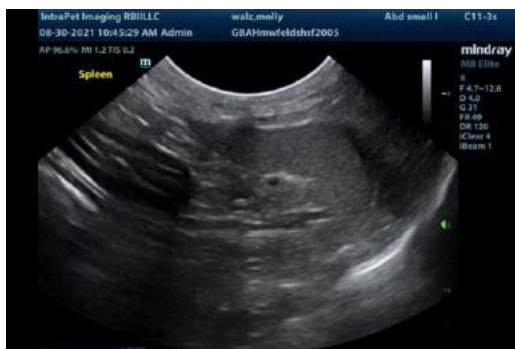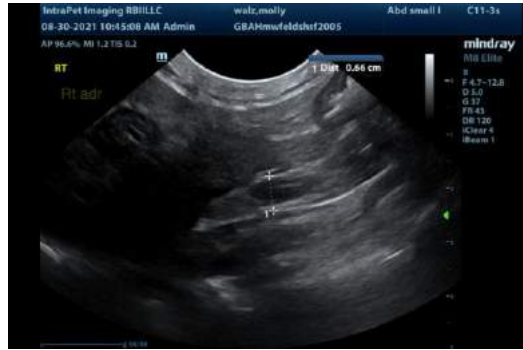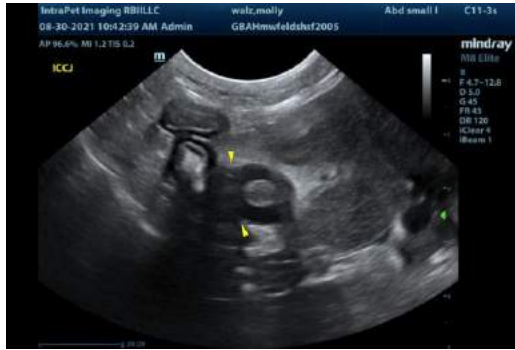- The mesenteric mass-effect is most consistent with infiltrative neoplasia (i.e., round cell tumor). However, pyogranulomatous lymphadenitis (i.e., secondary to FIP) cannot be completely excluded.
- The bowel pattern is consistent with lymphoma or severe inflammatory bowel disease.
- The trace ascites is likely secondary to bowel/lymph node pathology.

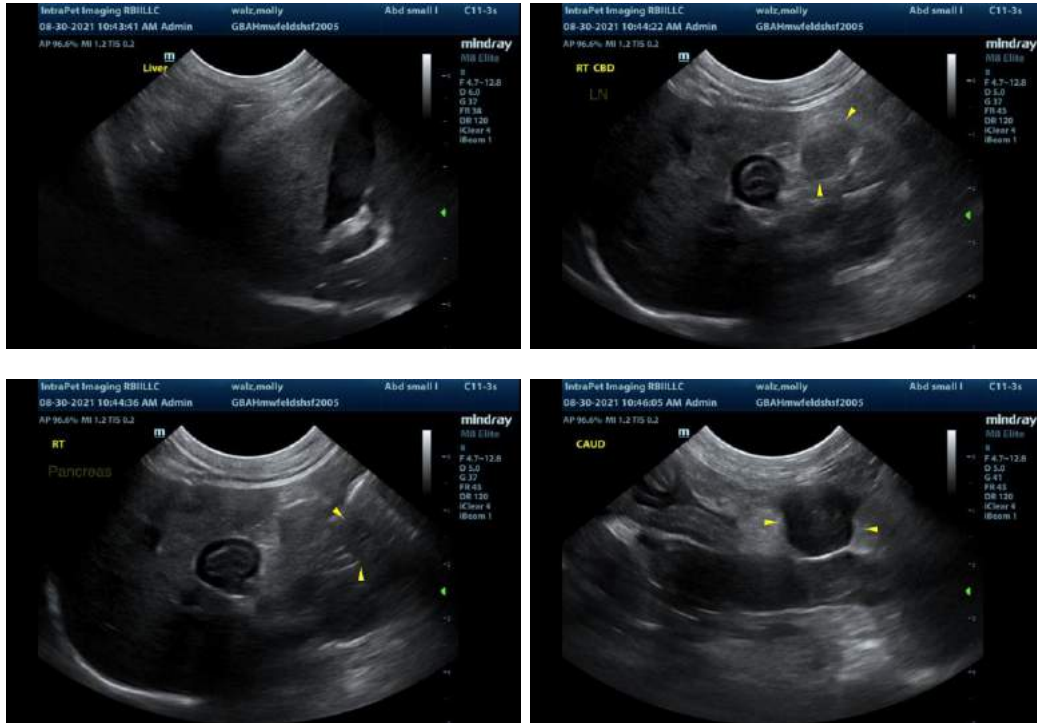
### **Secondary Findings:**

- The pancreatic changes may be a normal variant for this patient or could be consistent with mild, chronic pancreatitis. Correlation with clinical findings is recommended.
- The hepatic changes are consistent with age-related parenchymal remodeling and are not considered clinically significant at this time.
- Bilateral, age-related renal pathology.

## **INTERPRETATION OF THE FINDINGS & FURTHER RECOMMENDATIONS**

1. Three-view thoracic radiographs are recommended to assess for lymphadenopathy in the chest.
2. A fine needle aspirate of the mesenteric mass-effect is recommended (if clotting status is appropriate). A 25-gauge needle should be used. If cytologic evaluation is inconclusive, an abdominal exploratory with biopsies of the mesenteric lymph node mass-effect and gastrointestinal tract may be necessary to get a definitive diagnosis.





The information and recommendations provided are based on the images presented by the referring veterinarian. No evaluation can be communicated regarding pathology that was not visible in the image/video clips provided.

Thank you for this referral. If the clinical or image interpretation does not parallel your findings or if I can be of any further assistance, please contact me.

Andrea Nicastro, DVM, Diplomate ACVIM (*Small Animal Internal Medicine*)  
Andrea.nicastro@sonopath.com