

**DATE PRESENTING CLINICAL SIGNS**

8/30/2021

History: Carrier for hyperuricosuria. Episodes of polyuria.
 Current Medications: No current medications.
 Lab Results: UA – bacteria. USG 1.040 with some proteinuria, bacteriuria
 Radiographs: Not provided by the veterinarian.
 Date of Previous IntraPet Ultrasound: No previous IntraPet scans.
 Sedation: DexDomitor administered prior to scan.
 Stat Report: STAT report not requested by the veterinarian.

SPECIES

Canine

ULTRASONOGRAPHIC EXAMINATION OF THE ABDOMEN

*The gastric lumen is distended with ingesta obscuring a portion of the cranial abdomen.

BREED

Dalmation

Urinary System

The urinary bladder is moderately distended. The wall is normal in thickness with a smooth mucosal surface. A large amount of aggregated echogenic suspended debris is observed within the lumen. In addition, a small amount of gravity-dependent mineralized sand as well as a few tiny cystic calculi are seen. The region of the trigone and the visible portion of the proximal urethra are normal.

SEX

Male, neutered

The prostate is normal in size (1.25 cm in width) and shape. Parenchyma is homogenous. The prostatic urethra appears normal without evidence of dilation or obstruction.

AGE

5/26/2020

The left kidney is normal size (6.13 cm in length); normal shape and architecture with smooth peripheral margins. There is a normal 1:3 cortex to medulla ratio with normal corticomedullary distinction. Trace pyelectasia is present. There is no evidence of nephroliths, infarcts or hydroureter. Renal vasculature is normal.

WEIGHT

58 lbs.

The right kidney is normal size (6.43 cm in length); normal shape and architecture with smooth peripheral margins. There is a normal 1:3 cortex to medulla ratio with normal corticomedullary distinction. There is no evidence of pyelectasia, nephroliths, infarcts or hydroureter. Renal vasculature is normal.

INTERPRETED BY

Andrea Nicastro, DVM,
 Diplomate ACVIM
 (Small Animal Internal
 Medicine)

Adrenal Glands

The left adrenal gland is normal size (0.38 cm at cranial pole) (0.48 cm at caudal pole) (2.62 cm in length); normal shape; homogenous parenchyma. The glandular echogenicity and detail are unremarkable. Capsule, cortex, and medullary definition are normal. The phrenicoabdominal vein and surrounding vasculature are normal.

HOSPITAL NAME

Banfield Pet Hospital
 of Towson

The right adrenal gland is normal size (0.67 cm at cranial pole) (0.56 cm at caudal pole) (3.06 cm in length); normal shape; homogenous parenchyma. The glandular echogenicity and detail are unremarkable. Capsule, cortex, and medullary definition are normal. The phrenicoabdominal vein and surrounding vasculature are normal.

REFERRING VET

Dr. Culbertson

Spleen

The spleen is normal in size (1.29 cm in width at the level of the hilus) with a normal capsular contour. There is appropriate echogenicity and echotexture. No focal lesions are observed. Splenic vasculature is normal.

INVOICE

11968

Liver

The liver is subjectively normal in size with normal contours and structure. There is appropriate echogenicity and echotexture. No overt structural evidence of inflammatory, infiltrative or regenerative pathology is evident. Vascular and biliary tracts are of normal volume with no evidence of congestion. No pathological hepatic lymphadenopathy observed. The gall bladder lumen is moderately distended. The wall is thin and smooth. A small amount of suspended echogenic debris is observed within the lumen. The cystic and common bile ducts are normal/not seen.

Gastrointestinal

The gastric lumen is distended with ingesta. The gastric wall and pylorus are normal in thickness with a normal layering pattern. The pyloric outflow tract is patent. The small intestinal lumen is not dilated. The small intestinal wall thickness is normal with a normal layering pattern and appropriate mural detail. Discreet masses are not identified. The colonic wall is normal. No obstructive disease is noted.

Pancreas

The region of the pancreas is isoechoic relative to surrounding omental fat. No obvious parenchymal abnormalities are observed. There is no evidence of regional inflammation or effusion.

Free Abdomen

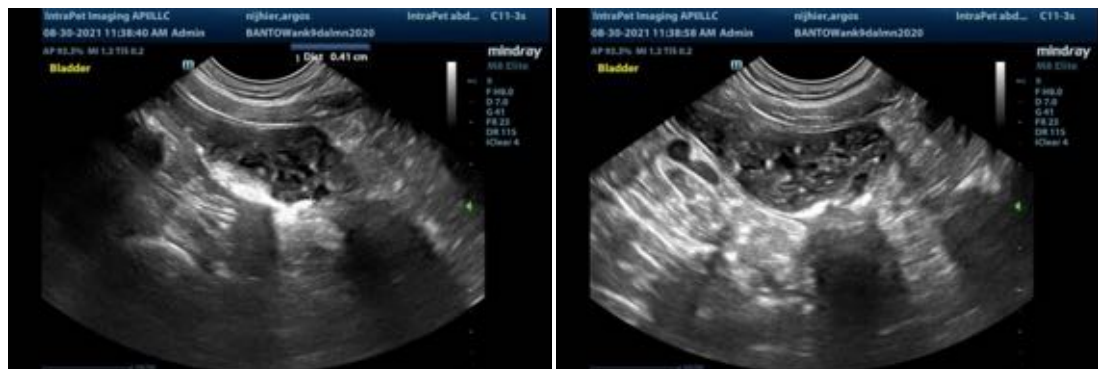
The peritoneal cavity is normal. There is no evidence of inflammation or effusion. A 1.41 cm mid-abdominal lymph node is visualized.

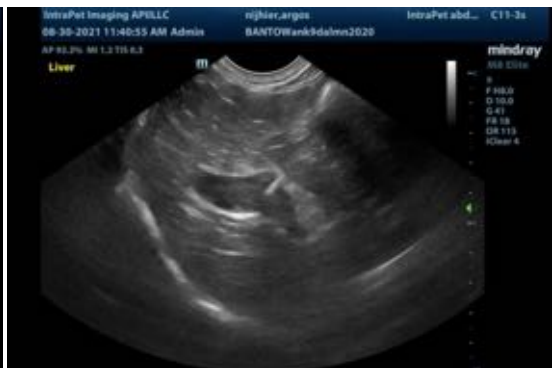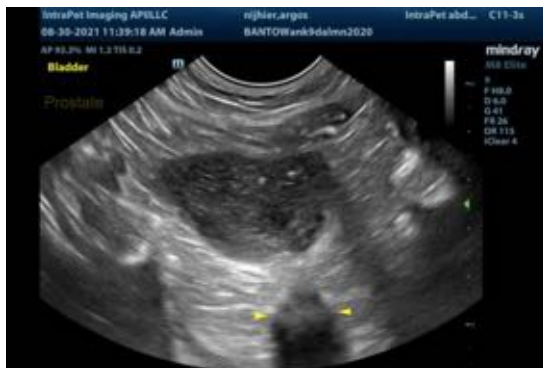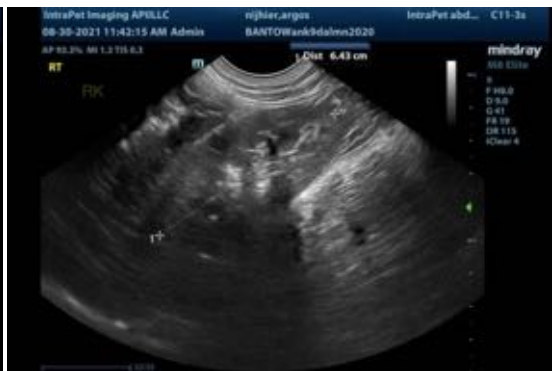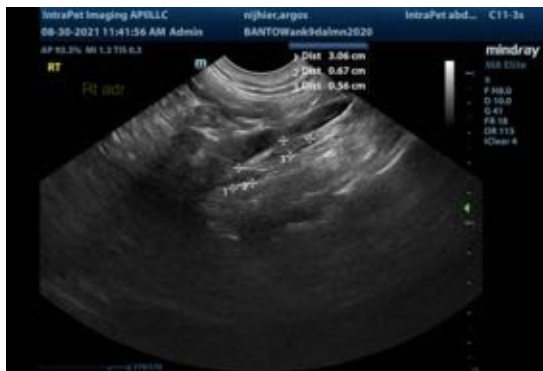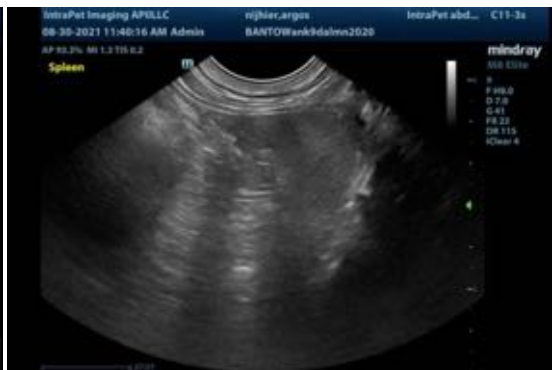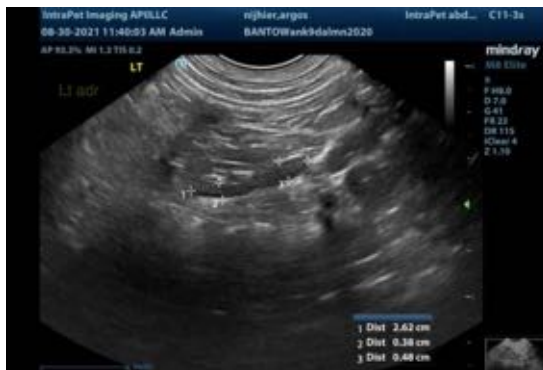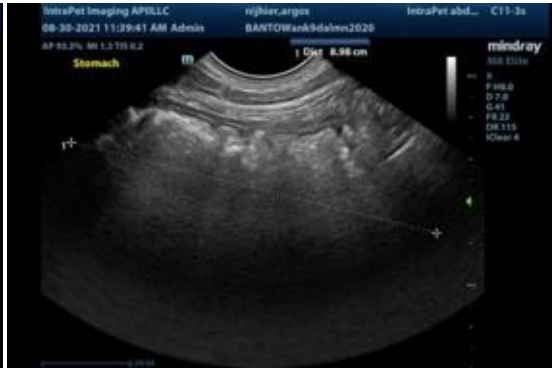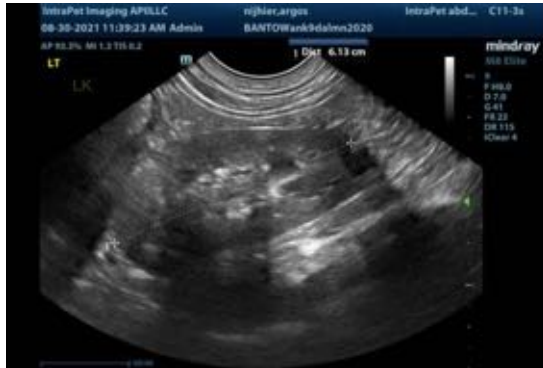ULTRASONOGRAPHIC FINDINGS

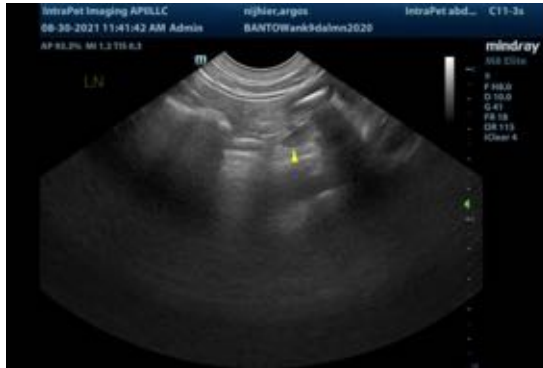- Urinary bladder sand/debris/tiny calculi. Given the breed, urate crystals/stones are of primary concern.
- The left pyelectasia may be secondary to pyelonephritis, PU/PD, other.

INTERPRETATION OF THE FINDINGS & FURTHER RECOMMENDATIONS

- A urine culture and sensitivity is recommended 5-7 days after the last dose of antibiotics.
- Abdominal radiographs would be useful to determine the number of cystic calculi that are present. A cystotomy with stone removal, analysis and culture should be considered if calculi are confirmed on abdominal radiographs.







The information and recommendations provided are based on the images presented by the referring veterinarian. No evaluation can be communicated regarding pathology that was not visible in the image/video clips provided.

Thank you for this referral. If the clinical or image interpretation does not parallel your findings or if I can be of any further assistance please contact me.

Andrea Nicastro, DVM, Diplomate ACVIM (*Small Animal Internal Medicine*)
Andrea.nicastro@sonopath.com