

**DATE PRESENTING CLINICAL SIGNS**

8.3.23 Vomiting. History of pancreatitis.

**PATIENT**

Meka Lilli

Current Medications: metro 50mg 1 tablet twice daily, currently feeding rx i/d low-fat diet  
Lab Results: CPLI snap test performed 5-18-2023, 06-08-2023, and 08-02-2023 all Positive

However, did one on 6-22-2023 and that test was negative

Date of Previous IntraPet Ultrasound: No previous.

Sedation: Not required to complete full diagnostic ultrasound.

Stat Report: Not requested.

Imaging Performed By: Rachel Brillhart, RDMS.

**SPECIES**

Canine

**BREED**

Dachshund

**SEX**

Female Spayed

**AGE**

6/11/2012

**WEIGHT**

13.4 lbs

**INTERPRETED BY**Andrea Nicastro, DMV,  
Diplomate DACVIM  
(Small Animal  
Internal Medicine)**HOSPITAL NAME**

Honeygo AH

**REFERRING VET**

Dr. Moffa

**INVOICE**

13929

**ULTRASONOGRAPHIC EXAMINATION OF THE ABDOMEN****Urinary System**

The urinary bladder wall is normal in thickness and the mucosal surface is smooth. The bladder is moderately distended. Luminal contents are anechoic. No cystic calculi are observed. The region of the trigone and the proximal urethra, visible to a depth of 1-2 cm, are normal.

The left kidney is normal in size (4.26 cm in length) with a normal shape, architecture and smooth peripheral margins. There is a normal 1:3 cortex to medulla ratio with minimal loss of corticomedullary distinction. There is no evidence of pyelectasia, nephroliths, infarcts or hydronephrosis. Renal vasculature is normal.

The right kidney is normal in size (4.74 cm in length) with a normal shape, architecture and smooth peripheral margins. There is a normal 1:3 cortex to medulla ratio with minimal loss of corticomedullary distinction. There is no evidence of pyelectasia, nephroliths, infarcts or hydronephrosis. Renal vasculature is normal.

**Adrenal Glands**

The left adrenal gland is normal in size (0.57 cm at cranial pole) (0.49 cm at caudal pole) (2.05 cm in length) with a normal shape and homogenous parenchyma. The glandular echogenicity and detail are unremarkable. Capsule, cortex, and medullary definition are normal. The phrenicoabdominal vein and surrounding vasculature are normal.

The right adrenal gland is in normal size (0.49 cm at cranial pole) (0.49 cm at caudal pole) (2.35 cm in length) with a normal shape and homogenous parenchyma. The glandular echogenicity and detail are unremarkable. Capsule, cortex, and medullary definition are normal. The phrenicoabdominal vein and surrounding vasculature are normal.

**Spleen**

The spleen is normal in size (0.96 cm in width at the level of the hilus) with a normal capsular contour. There is appropriate echogenicity and echotexture. No focal lesions are observed. Splenic vasculature is normal.

**Liver**

The liver is subjectively normal in size with normal contours and structure. There is appropriate echogenicity and echotexture. No overt structural evidence of inflammatory, infiltrative, or regenerative pathology is evident. Vascular and biliary tracts are of normal volume with no evidence of congestion. No pathological hepatic lymphadenopathy observed.

The gall bladder lumen is moderately distended. The wall is thin and smooth. A small-to-moderate amount of aggregated, echogenic-to-mineralized gravity-dependent debris is observed within the lumen. The cystic and common bile ducts are normal/not seen.

### ***Gastrointestinal***

The gastric lumen is moderately distended with ingesta. The gastric wall and pylorus are normal in thickness with a normal layering pattern. The pyloric outflow tract appears patent. The small intestinal lumen is not dilated. The small intestinal wall is normal in thickness. There is slight disruption in the normal 1:3 muscularis: mucosal ratio in some segments. Discreet masses are not identified. The colonic wall is normal. There is no evidence of an obstructive pattern.

### ***Pancreas***

The base and limbs of the pancreas are visible with normal curvilinear peripheral contours. The parenchyma is mildly hypoechoic relative to surrounding omental fat and slightly mottled in appearance. The pancreatic duct is visible but not overtly dilated. There is no evidence of peripancreatic inflammation or effusion.

### ***Free Abdomen***

The peritoneal cavity is normal. There is no evidence of inflammation or effusion. The abdominal lymph nodes are normal/not visible.

## **ULTRASONOGRAPHIC FINDINGS**

### **Primary Findings**

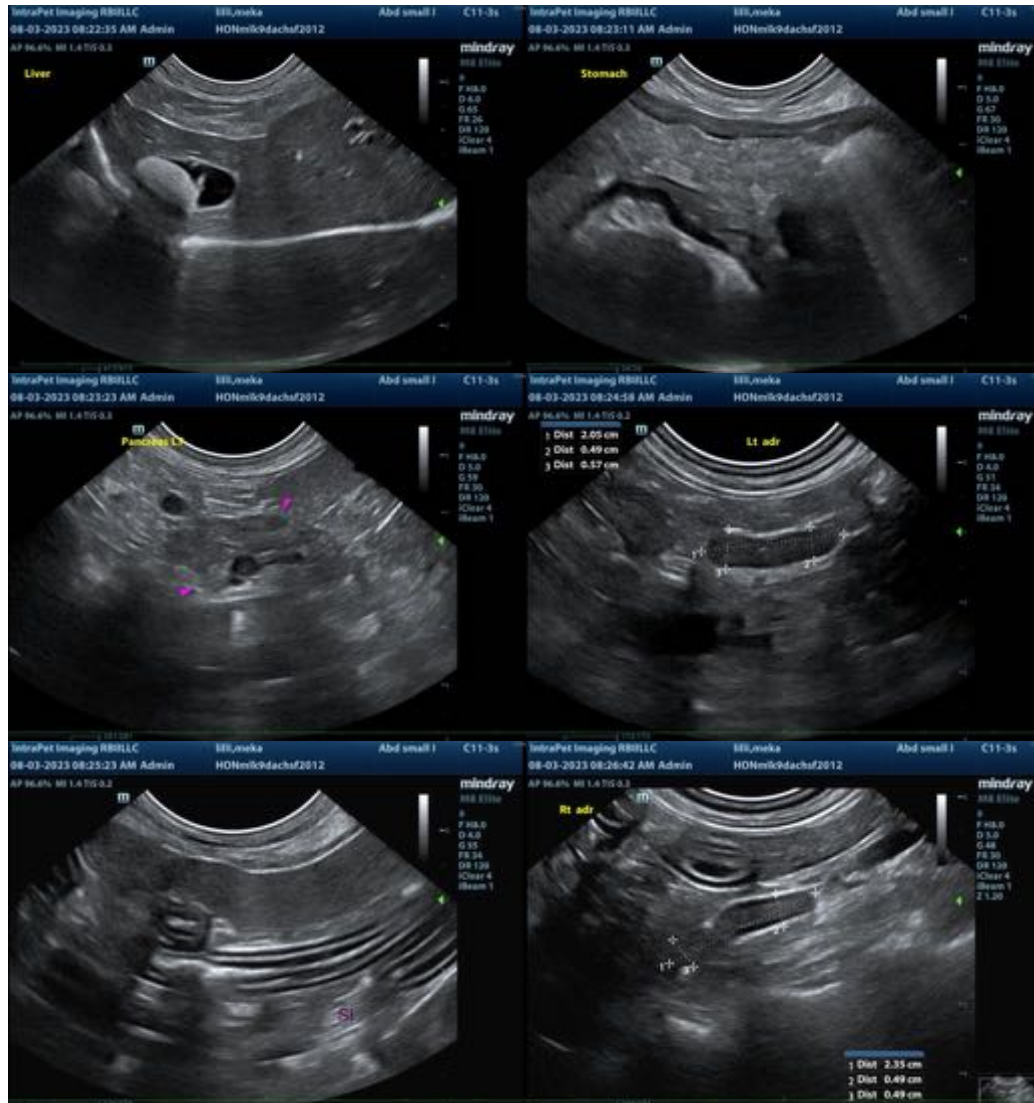
- The pancreatic changes are most consistent with chronic pancreatitis with age-related remodeling, +/- minor fibrosis.

### **Secondary Findings**

- Bowel pattern suggestive of inflammatory bowel disease. However, the changes may be a normal variant for this patient.
- Gallbladder sand – incidental/non-mucocele

## **INTERPRETATION OF THE FINDINGS & FURTHER RECOMMENDATIONS**

- Continuation of a prescription low-fat diet is recommended to help reduce the risk of future pancreatitis flareups.
- Given the bowel changes, consider a Texas GI panel including serum cobalamin and folate, TLI, PLI and resting cortisol level to assess for maldigestion/malabsorption, pancreatic disease and to screen for atypical hypoadrenocorticism.



The information and recommendations provided are based on the images presented by the referring veterinarian/sonographer. No evaluation can be communicated regarding pathology that was not visible in the image/video clips provided.

Thank you for this referral. If the clinical or image interpretation does not parallel your findings or if I can be of any further assistance, please contact me.

**Andrea Nicastro, MPH, DVM, Diplomate DACVIM (Small Animal Internal Medicine)**  
[info@SonoPath.com](mailto:info@SonoPath.com)