



PATIENT PRESENTING CLINICAL SIGNS

Chase Ven Der Polder

History: Presented for anorexia and abdominal distension for a few days. No response to symptomatic treatment with Cerenia injection, SQ fluids, Mirtazapine tablet on July 28th. Radiographs taken August 8th revealed fluid in peritoneal cavity, aspirated about 400ml of clear, red-colored fluid. Fluid analysis and cytology pending.

SPECIES

Feline

Abnormal PE/Chem/CBC/UA Results: Fluid analysis and cytology pending please see attached rads.

BREED

Himalayan

Urinary System

The **urinary bladder** is normal in thickness and the mucosal surface is smooth. The bladder is distended. A small to moderate amount of suspended, echogenic debris is observed within the lumen. No masses, inflammatory changes or calculi are observed. The cystourethral junction and the visible portion of the proximal urethra are normal.

SEX

Neutered Male

The **left kidney** is normal size (4.38 cm in length); normal shape and architecture with smooth peripheral margins. There is a normal 1:3 cortex to medulla ratio with mild to moderate loss of corticomedullary distinction. There is no evidence of pyelectasia, nephroliths, infarcts or hydronephrosis. Renal vasculature is normal.

AGE

12 years

The **right kidney** is normal size (3.91 cm in length); normal shape and architecture with smooth peripheral margins. There is a normal 1:3 cortex to medulla ratio with mild to moderate loss of corticomedullary distinction. There is no evidence of pyelectasia, nephroliths, infarcts or hydronephrosis. Renal vasculature is normal.

WEIGHT

16.11 lbs

Adrenal Glands

The region of the **adrenal glands** is evaluated. No obvious pathology is observed.

INTERPRETED BY

Andrea Nicastro, DVM,
Diplomate ACVIM
(Small Animal Internal
Medicine)

Spleen

The **spleen** is enlarged with irregular peripheral contours. A 1.95 cm hypoechoic to heterogeneous mass, with ill-defined hyperechoic areas appears to be arising from the medial aspect. The mass causes capsular expansion. The remaining parenchyma is slightly mottled with small, ill-defined hyperechoic regions. Splenic vasculature appears normal with no evidence of thrombosis.

IMAGING PERFORMED BY

Kelly Reschny

Liver

The **liver** is subjectively enlarged with swollen peripheral contours. The parenchyma is hyperechoic relative to the spleen. At least two cystic areas are observed adjacent to the diaphragm, one measuring 3.30 cm in diameter, the other measuring 2.60 cm in diameter. The larger cyst appears multiseptated. The remaining parenchyma is homogenous. Hepatic vasculature and intrahepatic biliary tracts are of normal volume with no evidence of congestion.

HOSPITAL NAME

Village Centre AH

The **gall bladder** is mildly distended. The wall is normal in thickness. Luminal contents are mostly anechoic. The cystic and common bile ducts are visible/tortuous but not overtly dilated.

REFERRING VET

Dr. Kunnath

Gastrointestinal

The **stomach** is difficult to visualize in its entirety due to the cranial abdomen pathology. In the visualized portions, the lumen is not distended. The wall appears normal in thickness. The small intestinal lumen is not dilated. The small intestinal wall is normal in thickness with a normal layering pattern and appropriate mural detail. Discrete masses are not identified. There is no obvious evidence of an obstructive pattern.

INVOICE

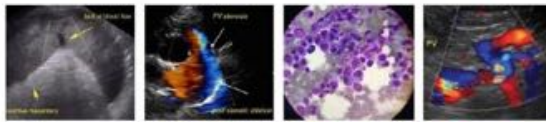
11316

Pancreas

Portions of the **pancreas** are obscured by the diffuse abdominal pathology. In the visualized portions, no obvious abnormalities are seen.

DATE

8.3.22



PATIENT

Chase Ven Der Polder

SPECIES

Feline

BREED

Himalayan

SEX

Neutered Male

AGE

12 years

WEIGHT

16.11 lbs

INTERPRETED BY

Andrea Nicastro, DVM,
Diplomate ACVIM
(Small Animal Internal
Medicine)

**IMAGING
PERFORMED BY**

Kelly Reschny

HOSPITAL NAME

Village Centre AH

REFERRING VET

Dr. Kunnath

INVOICE

11316

DATE

8.3.22

Free Abdomen

A large amount of echogenic free fluid is present. The omentum throughout the abdomen is hyperechoic and nodular in appearance. The abdominal **lymph nodes** are normal/not visible.

ULTRASONOGRAPHIC FINDINGS

Primary Findings

- Suspected splenic mass. However, a different area of origin (i.e., mesentery) is also possible. Neoplasia (i.e., sarcoma, carcinoma, round cell tumor) is suspected, with a lower possibility of benign pathology.
- The diffuse omental changes could be consistent with neoplasia (i.e., carcinomatosis) or reactive change.
- The diffuse ascites may be secondary to increased vascular permeability (i.e., neoplastic effusion), increased hydrostatic pressure or low oncotic pressure.

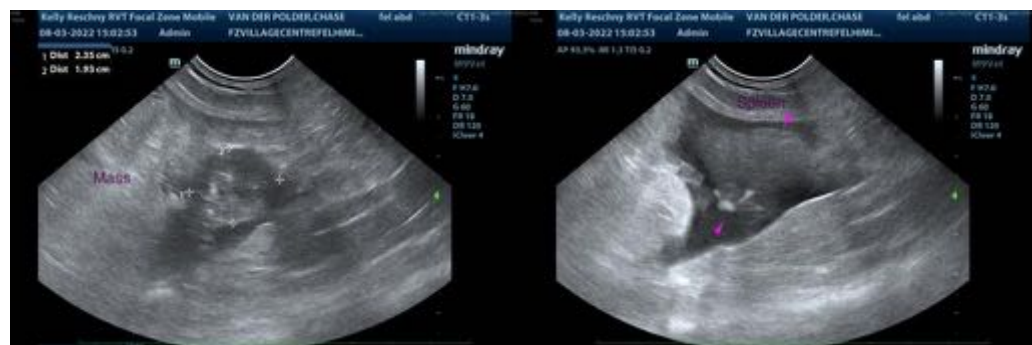Secondary Findings

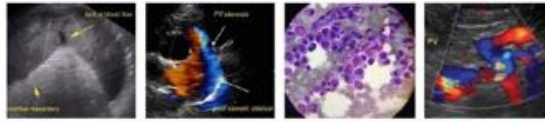
- The diffuse hepatic parenchymal changes could be consistent with hepatic lipidosis, inflammatory disease, and/or infiltrative neoplasia (i.e., lymphoma). The cystic hepatic lesions trend towards the benign (i.e., complex cysts, biliary cystadenoma) with a lower possibility of malignancy (i.e., cystadenocarcinoma).
- Bilateral, chronic, age-related renal changes.
- The urinary bladder debris could be consistent with cells, crystals, lipid droplets, and/or exfoliated material.

INTERPRETATION OF THE FINDINGS & FURTHER RECOMMENDATIONS

Three-view thoracic radiographs are recommended to assess for pulmonary metastases.

If the abdominal fluid analysis is inconclusive, a fine-needle aspirate of the nodular omentum or an abdominal exploratory with splenectomy and biopsy of the omentum may be necessary to get a definitive diagnosis. A liver biopsy should also be considered at the time of surgery. In the meantime, supportive care and nutritional support (i.e., via temporary feeding tube) is recommended.





PATIENT

Chase Ven Der Polder

SPECIES

Feline

BREED

Himalayan

SEX

Neutered Male

AGE

12 years

WEIGHT

16.11 lbs

INTERPRETED BY

Andrea Nicastro, DVM,
Diplomate ACVIM
(Small Animal Internal
Medicine)

**IMAGING
PERFORMED BY**

Kelly Reschny

HOSPITAL NAME

Village Centre AH

REFERRING VET

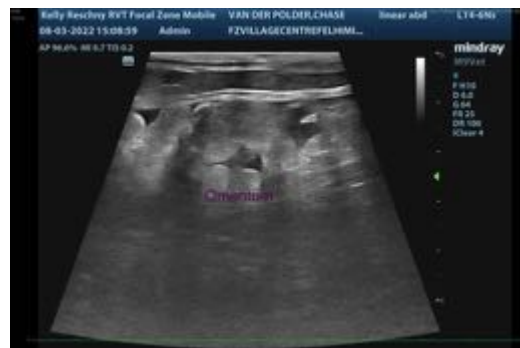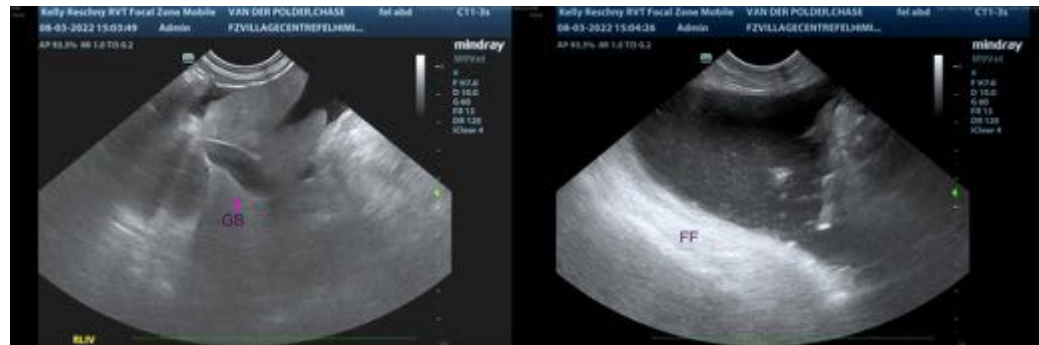
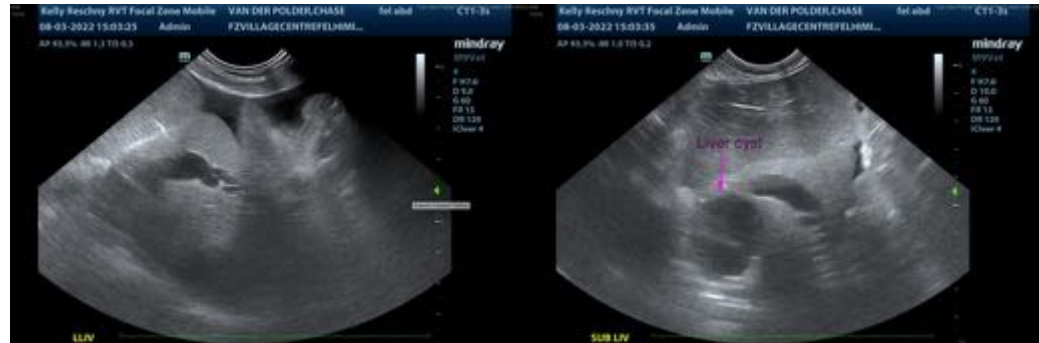Dr. Kunnath

INVOICE

11316

DATE

8.3.22



The information and recommendations provided are based on the images presented by the referring veterinarian/sonographer. No evaluation can be communicated regarding pathology that was not visible in the image/video clips provided.

Thank you for this referral. If the clinical or image interpretation does not parallel your findings or if I can be of any further assistance, please contact me.

Andrea Nicastro, MPH, DVM, Diplomate DACVIM (Small Animal Internal Medicine)
info@SonoPath.com