



**PATIENT PRESENTING CLINICAL SIGNS**

Lilly Vohland

**SPECIES**

Canine

**BREED**

Viszla

**SEX**

Female Spayed

**AGE**

5 years

**WEIGHT**

77.2 lbs

History: Pt. presented for weakness which started 2 nights ago (8/25/23), Pt. would not get up to come back inside. Pt. noted he then took Pt. to the coast and Pt. would not eat when they stopped at a rest area. Pt. did not drink ocean water or from any streams, rivers while visiting coast per O. Pt. chews and possibly swallows per O and has allergic reactions (dermatitis on head) to them per O. O noted Pt's urine has been progressively darker since yesterday (no obvious hematuria) and is concerned about a UTI. Last BM yesterday was runny, no hematochezia/melena per O. O mentioned Pt. "has had a cough for a while now and it sounds like Pt. is going to throw up" (no vomit produced). Vxs UTD, No Hx of heart murmur/problem. Pt. take interceptor HW preventative every month. Pt. was seen at Alpine Animal Hospital for V+/D+ and was treated w/ metronidazole & Fortiflora (both of these medications are finished).

**Abnormal PE/Chem/CBC/UA Results:**

CBC- HCT 43.9%, RETIC HGB 20.0, Neu 2.39, MONO 2.35, PLT 110,  
CHEM 10- GLU 72, GLOB 4.7, ALP 1794, ALT too high to read  
ALT dilution 1:10-3688  
EPOC\_HCT 44%, Bicarb 14.6, LAC 4.3, pH 7.3,  
intake BP-134/84 MAP 101  
PT/PTT- 17 (high normal), PTT 127 (h)  
CPL-360.5 (suspect panc)  
TBili-3.5 (high)

**INTERPRETED BY**

Andrea Nicastro,  
DVM, Diplomate  
ACVIM (Small Animal  
Internal Medicine)

**IMAGING PERFORMED BY**

Maggiulli

**HOSPITAL NAME**

Willamette VH

**REFERRING VET**

Maggiulli

**INVOICE**

14251

**DATE**

8.28.23

**ULTRASONOGRAPHIC EXAMINATION OF THE ABDOMEN**

**Urinary System**

The urinary bladder wall is normal in thickness and the mucosal surface is smooth. The bladder is moderately distended. Luminal contents are anechoic. No cystic calculi are observed. The region of the trigone is normal.

The left kidney is normal in size (6.50 cm in length) with a normal shape, architecture and smooth peripheral margins. There is a normal 1:3 cortex to medulla ratio with mild loss of corticomedullary distinction. There is no evidence of pyelectasia, nephroliths, infarcts or hydroureter. Renal vasculature is normal.

The right kidney is normal in size (7.09 cm in length) with a normal shape, architecture and smooth peripheral margins. There is a normal 1:3 cortex to medulla ratio with minimal loss of corticomedullary distinction. There is no evidence of pyelectasia, nephroliths, infarcts or hydroureter. Renal vasculature is normal.

**Adrenal Glands**

The left adrenal gland is normal in size (0.52 cm at cranial pole) (0.45 cm at caudal pole) with a normal shape and homogenous parenchyma. The glandular echogenicity and detail are unremarkable. Capsule, cortex, and medullary definition are normal. The phrenicoabdominal vein and surrounding vasculature are normal.

The region of the right adrenal gland is evaluated. No obvious pathology is observed in this region.

**Spleen**

The spleen is normal in size (1.55 cm in width at the level of the hilus) with a normal capsular contour. There is appropriate echogenicity and echotexture. No focal lesions are observed. Splenic vasculature is normal.



**PATIENT**

Lilly Vohland

**SPECIES**

Canine

**BREED**

Viszla

**SEX**

Female Spayed

**AGE**

5 years

**WEIGHT**

77.2 lbs

**INTERPRETED BY**

Andrea Nicastro,  
DVM, Diplomate  
ACVIM (Small Animal  
Internal Medicine)

**IMAGING  
PERFORMED BY**

Maggiulli

**HOSPITAL NAME**

Willamette VH

**REFERRING VET**

Maggiulli

**INVOICE**

14251

**DATE**

8.28.23

**Liver**

The liver is subjectively normal in size with normal contours and structure. There is appropriate echogenicity and echotexture. No overt structural evidence of inflammatory, infiltrative, or regenerative pathology is evident. Vascular and biliary tracts are of normal volume with no evidence of congestion. No pathological hepatic lymphadenopathy observed.

The gall bladder is moderately distended. The wall is normal in thickness and slightly hyperechoic. A small amount of echogenic debris is observed within the lumen. The cystic and common bile ducts are normal/not seen.

**Gastrointestinal**

The lumen is mildly-to-moderately distended with fluid and gas. The gastric wall is normal in thickness with a normal layering pattern. The small intestinal lumen is not dilated. The small intestinal wall thickness is normal with a normal layering pattern and appropriate mural detail. Discreet masses are not identified. The colonic wall is normal.

**Pancreas**

The region of the pancreas is isoechoic relative to surrounding omental fat. No obvious parenchymal abnormalities are observed. There is no evidence of regional inflammation or effusion.

**Free Abdomen**

The peritoneal cavity is normal. There is no evidence of inflammation or effusion. The abdominal lymph nodes are normal/not visible.

**Other**

A brief visualization of the heart reveals no obvious evidence of pericardial effusion.

**ULTRASONOGRAPHIC FINDINGS**

- An obvious cause for the elevated liver enzymes is not identified in the study. However, a microscopic hepatopathy (i.e., bacterial cholangiohepatitis, Leptospirosis, chronic active hepatitis, copper-associated hepatotoxicity, infiltrative neoplasia (less likely)) is suspected.
- The gallbladder wall changes could be consistent with cholecystitis or may be a normal variant for this patient.

**INTERPRETATION OF THE FINDINGS & FURTHER RECOMMENDATIONS**

- Leptospirosis testing (i.e., blood and urine PCR, serology) is recommended.
- If the patient's clotting status can be stabilized, hepatic tissue sampling (i.e., fine-needle aspirate or biopsies) can be considered. If biopsies are pursued, aerobic and anaerobic bile cultures are recommended along with hepatic copper quantitation.
- If a more conservative approach is desired, consider empirical treatment for cholangiohepatitis/cholecystitis/Leptospirosis with amoxicillin-clavulanic acid along with hepatic antioxidants. If liver values do not begin to improve within 7-10 days of initiating therapy, antibiotics should be discontinued and hepatic tissue sampling reconsidered. If values do improve, a 4-6-week course of treatment is recommended.
- Given the patient's neutropenia, close monitoring of the patient's CBC is recommended. Also consider a clinical pathological review of the CBC.



**PATIENT**

Lilly Vohland

**SPECIES**

Canine

**BREED**

Viszla

**SEX**

Female Spayed

**AGE**

5 years

**WEIGHT**

77.2 lbs

**INTERPRETED BY**

Andrea Nicastro, DVM, Diplomate ACVIM (Small Animal Internal Medicine)

**IMAGING PERFORMED BY**

Maggiulli

**HOSPITAL NAME**

Willamette VH

**REFERRING VET**

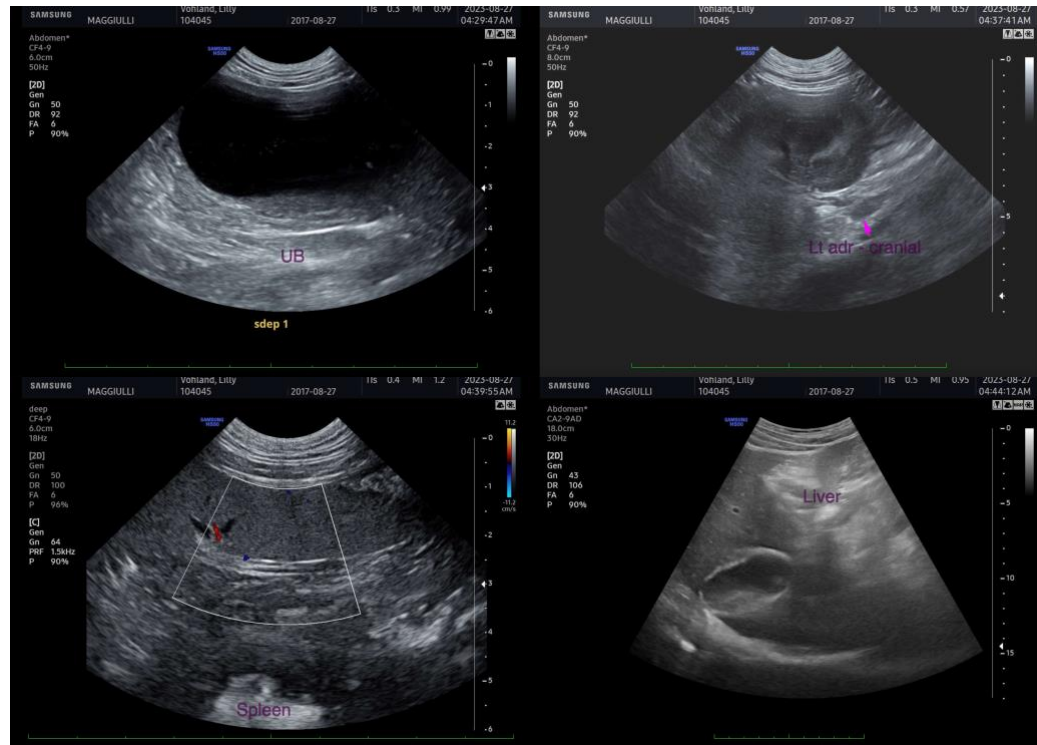
Maggiulli

**INVOICE**

14251

**DATE**

8.28.23



The information and recommendations provided are based on the images presented by the referring veterinarian/sonographer. No evaluation can be communicated regarding pathology that was not visible in the image/video clips provided.

Thank you for this referral. If the clinical or image interpretation does not parallel your findings or if I can be of any further assistance, please contact me.

**Andrea Nicastro, MPH, DVM, Diplomate DACVIM (Small Animal Internal Medicine)**  
[info@SonoPath.com](mailto:info@SonoPath.com)