



PATIENT

Misha Nater

PRESENTING CLINICAL SIGNS

Patient presented with brown, viscous urine.

SPECIES

Canine

ULTRASONOGRAPHIC EXAMINATION OF THE ABDOMEN

Urinary System

The urinary bladder, trigone, and pelvic urethra are normal in thickness and the mucosal surface is smooth. The bladder lumen is moderately distended with anechoic urine. No masses, inflammatory changes or calculi are observed. Ureteral papillae and visualized portion of the proximal urethra, visible to a depth of 2 cm, are normal.

BREED

Havanese

The left kidney is normal size (3.95 cm in length); normal shape and architecture with smooth peripheral margins. There is a normal 1:3 cortex to medulla ratio with normal corticomedullary distinction. There is no evidence of pyelectasia, nephroliths, infarcts or hydroureter. Renal vasculature is normal.

SEX

Male Neutered

The right kidney is normal size (4.92 cm in length); normal shape and architecture with smooth peripheral margins. There is a normal 1:3 cortex to medulla ratio with normal corticomedullary distinction. There is no evidence of pyelectasia, nephroliths, infarcts or hydroureter. Renal vasculature is normal.

AGE

7 Years

Adrenal Glands

WEIGHT

16.6 lbs.

The left adrenal gland is normal size (0.47 cm at cranial pole) (0.48 cm at caudal pole) (1.39 cm in length); normal shape; homogenous parenchyma. The glandular echogenicity and detail are unremarkable. Capsule, cortex, and medullary definition are normal. The phrenicoabdominal vein and surrounding vasculature are normal.

INTERPRETED BY

Andrea Nicastro, DVM,
Diplomate ACVIM
(Small Animal Internal
Medicine)

The right adrenal gland is normal size (0.40 cm at cranial pole) (0.49 cm at caudal pole) (1.47 cm in length); normal shape; homogenous parenchyma. The glandular echogenicity and detail are unremarkable. Capsule, cortex, and medullary definition are normal. The phrenicoabdominal vein and surrounding vasculature are normal.

IMAGING PERFORMED BY

Spleen

The spleen is normal in size (1.38 cm in width at the level of the hilus) with a normal capsular contour. There is appropriate echogenicity and echotexture. No focal lesions are observed. Splenic vasculature is normal.

Andrea Nicastro, DVM

HOSPITAL NAME

Liver

Rockaway Animal
Hospital

The liver is subjectively normal in size with normal contours and structure. There is appropriate echogenicity and echotexture. No overt structural evidence of inflammatory, infiltrative, or regenerative pathology is evident. Vascular and biliary tracts are of normal volume with no evidence of congestion. No pathological hepatic lymphadenopathy observed. The gall bladder lumen is moderately distended. The wall is thin and smooth. A moderate amount of echogenic debris, some of which is gravity dependent and some of which is adherent, is observed within the lumen. The cystic and common bile ducts are normal/not seen.

REFERRING VET

INVOICE

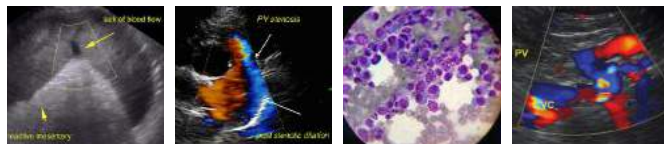
Gastrointestinal

11707kk

The stomach and intestine are free of stasis and exhibit normal peristaltic activity. The gastric lumen is not distended. The gastric wall and pylorus are normal in thickness with a normal layering pattern. The pyloric outflow tract is patent. The small intestinal lumen is not dilated. The small intestinal wall

DATE

8/27/21



PATIENT

thickness is normal with a normal layering pattern and appropriate mural detail. Discreet masses are not identified. The colonic wall is normal. No obstructive disease is noted.

Misha Nater

Pancreas

SPECIES

The pancreas is normal in size with normal peripheral contours. The pancreatic duct is normal. The base and limbs of the pancreas are isoechoic to surrounding omental fat. No focal lesions are observed. There is no evidence of peripancreatic inflammation or effusion.

Canine

BREED

Free Abdomen

Havanese

The peritoneal cavity is normal. There is no evidence of inflammation or effusion. The abdominal lymph nodes are normal/not visible.

SEX

ULTRASONOGRAPHIC FINDINGS

Male Neutered

- Unremarkable abdomen. An obvious cause for the patient's clinical signs is not identified in this study. A urinary tract infection is suspected.

AGE

INTERPRETATION OF THE FINDINGS & FURTHER RECOMMENDATIONS

7 Years

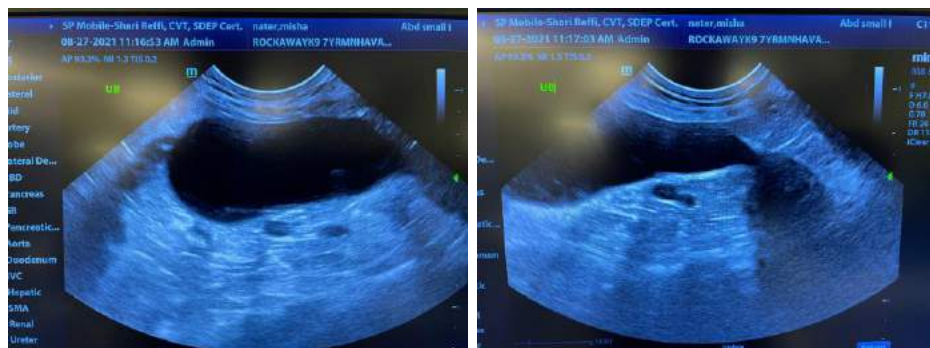
1. Urine culture and sensitivity.
2. Baseline lab work including a CBC chemistry panel and urinalysis, if not already performed.

WEIGHT

16.6 lbs.

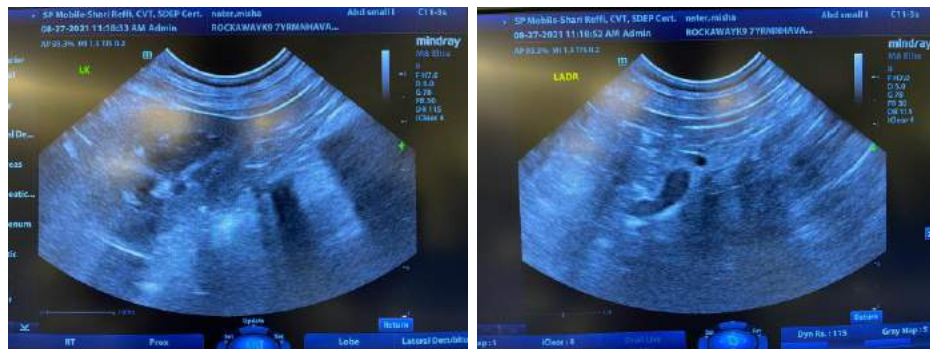
INTERPRETED BY

Andrea Nicastro, DVM,
Diplomate ACVIM
(Small Animal Internal
Medicine)



IMAGING PERFORMED BY

Andrea Nicastro, DVM



HOSPITAL NAME

Rockaway Animal
Hospital

REFERRING VET

INVOICE

11707kk

DATE

8/27/21



PATIENT

Misha Nater

SPECIES

Canine

BREED

Havanese

SEX

Male Neutered

AGE

7 Years

WEIGHT

16.6 lbs.

INTERPRETED BY

Andrea Nicastro, DVM,
Diplomate ACVIM
(Small Animal Internal
Medicine)

IMAGING PERFORMED BY

Andrea Nicastro, DVM

HOSPITAL NAME

Rockaway Animal
Hospital

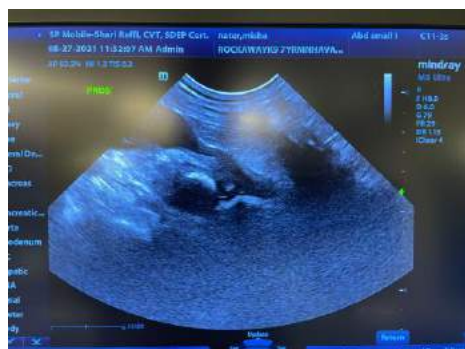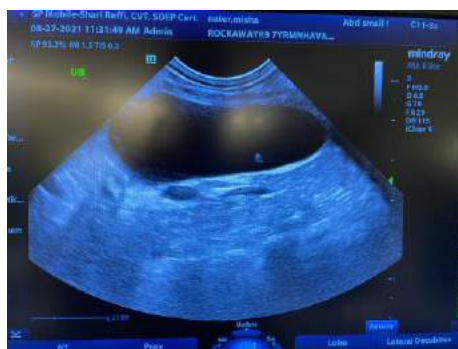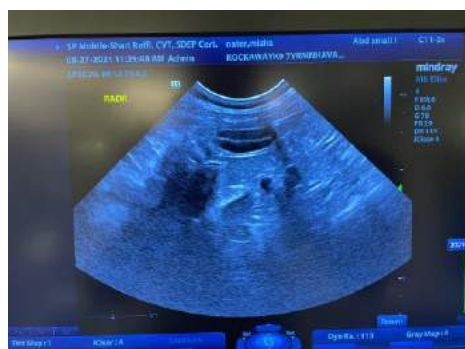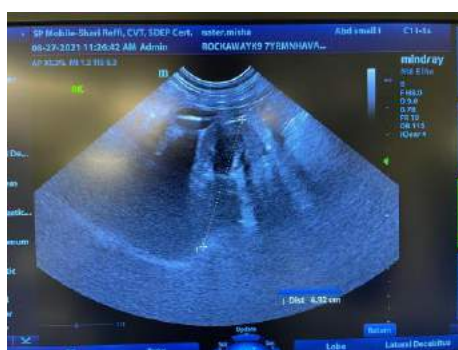
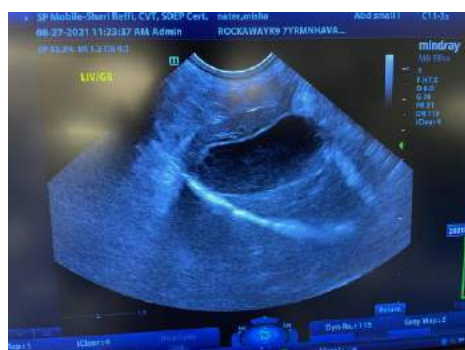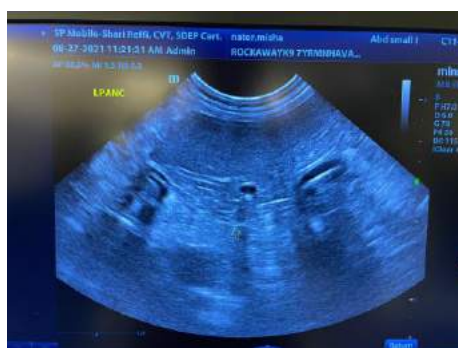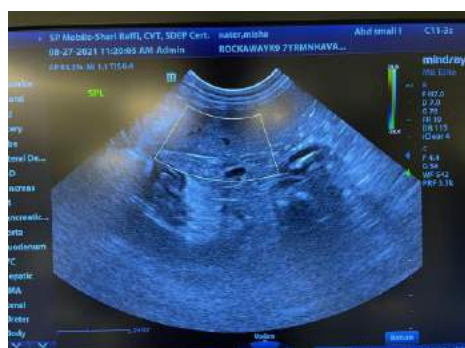
REFERRING VET

INVOICE

11707kk

DATE

8/27/21



The information and recommendations provided are based on the images presented by the referring veterinarian. No evaluation can be communicated regarding pathology that was not visible in the image/video clips provided.

Thank you for this referral. If the clinical or image interpretation does not parallel your findings or if I can be of any further assistance, please contact me.



PATIENT

Misha Nater

Andrea Nicastro, DVM, Diplomate ACVIM (*Small Animal Internal Medicine*)

Andrea.nicastro@sonopath.com

SPECIES

Canine

BREED

Havanese

SEX

Male Neutered

AGE

7 Years

WEIGHT

16.6 lbs.

INTERPRETED BY

Andrea Nicastro, DVM,
Diplomate ACVIM
(*Small Animal Internal
Medicine*)

**IMAGING
PERFORMED BY**

Andrea Nicastro, DVM

HOSPITAL NAME

Rockaway Animal
Hospital

REFERRING VET

INVOICE

11707kk

DATE

8/27/21