



PATIENT

Holly Miraowski

PRESENTING CLINICAL SIGNS

The patient presented for intermittent vomiting. She consumed a diaper one week prior.

SPECIES

Canine

ULTRASONOGRAPHIC EXAMINATION OF THE ABDOMEN

Urinary System

The urinary bladder, trigone, and pelvic urethra are normal in thickness and the mucosal surface is smooth. The bladder lumen is moderately distended with anechoic urine. No masses, inflammatory changes or calculi are observed. Ureteral papillae and visualized portion of the proximal urethra, visible to a depth of 2 cm, are normal.

BREED

Catahoula Leopard
Mix

The left kidney is normal size (5.69 cm in length); normal shape and architecture with smooth peripheral margins. There is a normal 1:3 cortex to medulla ratio with normal corticomedullary distinction. There is no evidence of pyelectasia, nephroliths, infarcts or hydronephrosis. Renal vasculature is normal.

SEX

Female spayed

The right kidney is normal size (6.05 cm in length); normal shape and architecture with smooth peripheral margins. There is a normal 1:3 cortex to medulla ratio with normal corticomedullary distinction. There is no evidence of pyelectasia, nephroliths, infarcts or hydronephrosis. Renal vasculature is normal.

AGE

3 Years

Adrenal Glands

WEIGHT

45.5 lbs.

The left adrenal gland is normal size (0.55 cm at cranial pole) (0.41 cm at caudal pole) (2.40 cm in length); normal shape; homogenous parenchyma. The glandular echogenicity and detail are unremarkable. Capsule, cortex, and medullary definition are normal. The phrenicoabdominal vein and surrounding vasculature are normal.

INTERPRETED BY

Andrea Nicastro, DVM,
Diplomate ACVIM
(Small Animal Internal
Medicine)

The right adrenal gland is normal size (0.47 cm at cranial pole) (1.11 cm at caudal pole) (2.55 cm in length); normal shape; homogenous parenchyma. The glandular echogenicity and detail are unremarkable. Capsule, cortex, and medullary definition are normal. The phrenicoabdominal vein and surrounding vasculature are normal.

IMAGING PERFORMED BY

Spleen

The spleen is normal in size (1.55 cm in width at the level of the hilus) with a normal capsular contour. There is appropriate echogenicity and echotexture. No focal lesions are observed. Splenic vasculature is normal.

Andrea Nicastro, DVM

HOSPITAL NAME

Liver

Rockaway Animal
Hospital

The liver is subjectively normal in size with normal contours and structure. There is appropriate echogenicity and echotexture. No overt structural evidence of inflammatory, infiltrative, or regenerative pathology is evident. Vascular and biliary tracts are of normal volume with no evidence of congestion. No pathological hepatic lymphadenopathy observed. The gall bladder lumen is moderately distended. The wall is thin and smooth. Luminal contents are anechoic. The cystic and common bile ducts are normal/not seen.

REFERRING VET

INVOICE

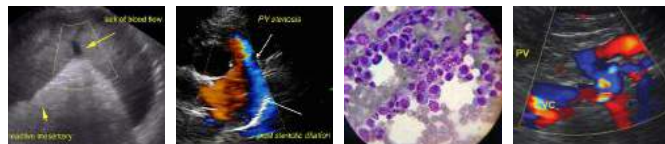
11709kk

Gastrointestinal

The stomach and intestine are free of stasis and exhibit normal peristaltic activity. The gastric lumen is not distended. The gastric wall and pylorus are normal in thickness with a normal layering pattern. The pyloric outflow tract is patent. The small intestinal lumen is not dilated. The small intestinal wall

DATE

8/27/21



PATIENT

Holly Miraowski

thickness is normal with a normal layering pattern and appropriate mural detail. Discreet masses are not identified. The colonic wall is normal. No obstructive disease is noted.

SPECIES

Canine

Pancreas

The region of the pancreas is isoechoic relative to surrounding omental fat. No obvious parenchymal abnormalities are observed. There is no evidence of regional inflammation or effusion.

BREED

Catahoula Leopard
Mix

Free Abdomen

The peritoneal cavity is normal. There is no evidence of inflammation or effusion. The abdominal lymph nodes are normal/not visible.

SEX

Female spayed

- Unremarkable abdomen.

**An obvious cause for the patient's clinical signs is not identified in this study.

AGE

3 Years

INTERPRETATION OF THE FINDINGS & FURTHER RECOMMENDATIONS

1. Supportive care for acute gastroenteritis is recommended. If clinical signs do not improve with supportive care, a more advanced gastrointestinal work up may be warranted.

WEIGHT

45.5 lbs.

INTERPRETED BY

Andrea Nicastro, DVM,
Diplomate ACVIM
(Small Animal Internal
Medicine)

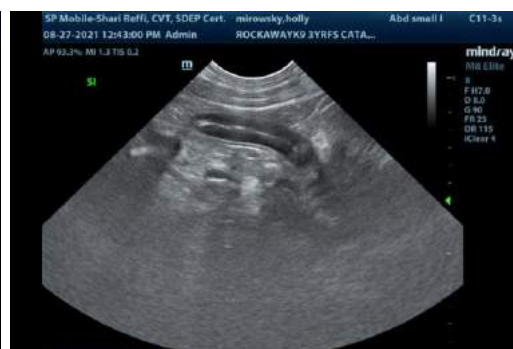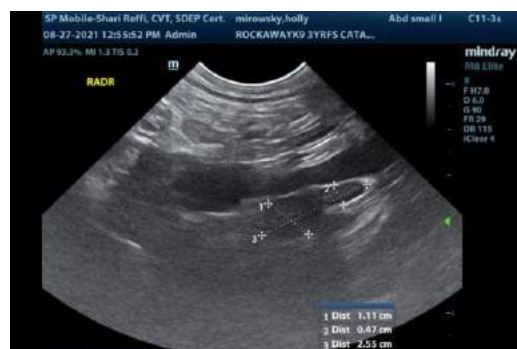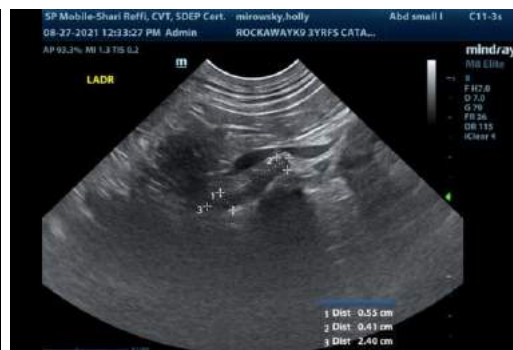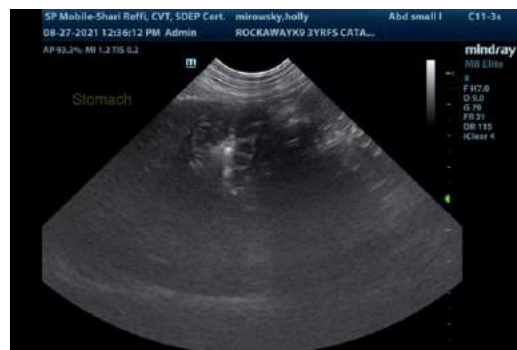IMAGING PERFORMED BY

Andrea Nicastro, DVM

HOSPITAL NAME

Rockaway Animal
Hospital

REFERRING VET



INVOICE

11709kk

DATE

8/27/21



PATIENT

Holly Miraowski

SPECIES

Canine

BREED

Catahoula Leopard
Mix

SEX

Female spayed

AGE

3 Years

WEIGHT

45.5 lbs.

INTERPRETED BY

Andrea Nicastro, DVM,
Diplomate ACVIM
(*Small Animal Internal
Medicine*)

IMAGING PERFORMED BY

Andrea Nicastro, DVM

HOSPITAL NAME

Rockaway Animal
Hospital

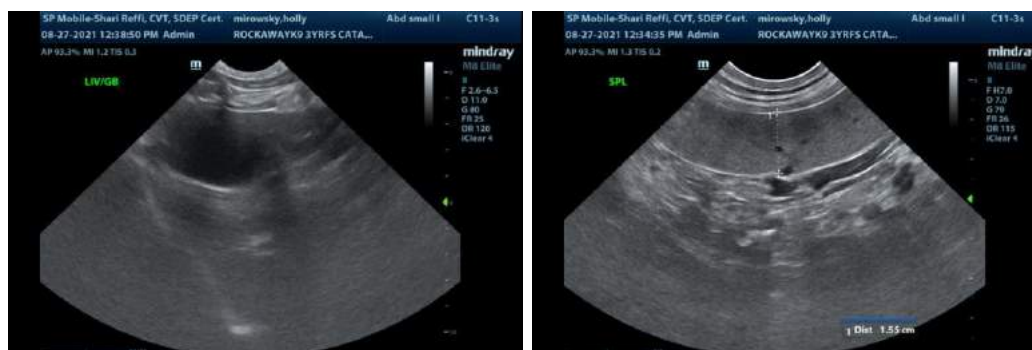
REFERRING VET

INVOICE

11709kk

DATE

8/27/21



The information and recommendations provided are based on the images presented by the referring veterinarian. No evaluation can be communicated regarding pathology that was not visible in the image/video clips provided.

Thank you for this referral. If the clinical or image interpretation does not parallel your findings or if I can be of any further assistance, please contact me.

Andrea Nicastro, DVM, Diplomate ACVIM (*Small Animal Internal Medicine*)
Andrea.nicastro@sonopath.com