

**DATE PRESENTING CLINICAL SIGNS**

8.24.2022 Vomiting at least once per day, diarrhea.

PATIENT

Morrigan Kalmanovich

Current Medications: Metronidazole BID, Revolution plus applied q30d.

Lab Results: Hypoglobulinemia 2.8. CBC T4 UA unremarkable.

Date of Previous IntraPet Ultrasound: No previous.

Sedation: Alfaxan/Torbugesic.

Stat Report: Not requested.

SPECIES

Imaging Performed By: Stephanie Warga RDCS, RVT.

Feline

BREED

DSH

SEX

Spayed Female

AGE

3/18/2009

WEIGHT

9.38lbs

INTERPRETED BY

Andrea Nicastro,
DMV, Diplomate
DACVIM (Small
Animal
Internal Medicine)

HOSPITAL NAME

Cat Hospital at Towson

REFERRING VET

Dr. Brunt

INVOICE

11477

PRESENTING CLINICAL SIGNS

Vomiting at least once per day, diarrhea.

Current Medications: Metronidazole BID, Revolution plus applied q30d.

Lab Results: Hypoglobulinemia 2.8. CBC T4 UA unremarkable.

Date of Previous IntraPet Ultrasound: No previous.

Sedation: Alfaxan/Torbugesic.

Stat Report: Not requested.

Imaging Performed By: Stephanie Warga RDCS, RVT.

ULTRASONOGRAPHIC EXAMINATION OF THE ABDOMEN**Urinary System**The **urinary bladder** and visible portion of the pelvic urethra are normal for the degree of luminal distension.

The urine is anechoic with no evidence of debris. Cystic calculi and discrete masses are not observed. The region of the trigone and the visible portion of the proximal urethra are normal.

The **left kidney** is normal size (3.95 cm in length); with a slightly irregular shape. The cortex is mildly hypoechoic. There is a normal 1:3 cortex to medulla ratio with moderate loss of corticomedullary distinction. There is no evidence of pyelectasia, nephroliths, infarcts or hydronephrosis. Renal vasculature is normal. The mesentery surrounding the kidney is mildly hyperechoic.

The **right kidney** is normal size (3.79 cm in length); with a slightly irregular shape. The cortex is mildly hypoechoic. There is a normal 1:3 cortex to medulla ratio with moderate loss of corticomedullary distinction. There is no evidence of pyelectasia, nephroliths, infarcts or hydronephrosis. Renal vasculature is normal. The mesentery surrounding the kidney is mildly hyperechoic.

Adrenal GlandsThe **left adrenal gland** is normal size (0.43 cm width). Normal shape and glandular echogenicity. The phrenicoabdominal vein and surrounding vasculature are normal.The **right adrenal gland** is normal size (0.33 cm width). Normal shape and glandular echogenicity. The phrenicoabdominal vein and surrounding vasculature are normal.**Spleen**The **spleen** is normal in size (0.69 cm in width at the level of the hilus) with a normal capsular contour. There is appropriate echogenicity and echotexture. No focal lesions are observed. Splenic vasculature is normal.**Liver**The **liver** is subjectively normal in size with normal contours and structure. There is appropriate echogenicity and echotexture. No overt structural evidence of inflammatory, infiltrative, or regenerative pathology is evident. Vascular and biliary tracts are of normal volume with no evidence of congestion. No pathological hepatic lymphadenopathy observed.

The **gall bladder** lumen is moderately distended. The wall is thin and smooth. A small amount of aggregated, echogenic, partially dependent, debris/sludge is observed within the lumen. The cystic and common bile ducts are normal. The cystic and proximal common bile duct contain a small amount of echogenic debris.

GastrointestinalThe **stomach and intestine** are free of stasis and exhibit normal peristaltic activity. The gastric lumen is not distended. The gastric wall and pylorus are normal in thickness with a normal layering pattern. The pyloric

outflow tract is patent. The small intestinal lumen is not dilated. The small intestinal wall thickness is normal with a normal layering pattern and appropriate mural detail. There is disruption in the normal 1:3 muscularis: mucosal ratio in most segments. Discreet masses are not identified. The ileocecal colic junction and colonic wall are normal. No obstructive disease is noted.

Pancreas

The region of the **pancreas** is isoechoic relative to surrounding omental fat. No obvious parenchymal abnormalities are observed. There is no evidence of regional inflammation or effusion.

Free Abdomen

The mesentery in the midabdominal region is hyperechoic. There is no obvious evidence of free fluid. A 0.78 cm gastric **lymph node** is visualized. Several prominent mesenteric lymph nodes are also seen. The mesentery surrounding the nodes is hyperechoic.

ULTRASONOGRAPHIC FINDINGS

Primary Findings

- Bowel pattern consistent with inflammatory bowel disease with some potential for emerging lymphoma.
- The abdominal lymphadenopathy could be consistent with lymphoid hyperplasia, reactive lymphadenitis or infiltrative neoplasia (i.e., lymphoma). Regional peritonitis is present.

Secondary Findings

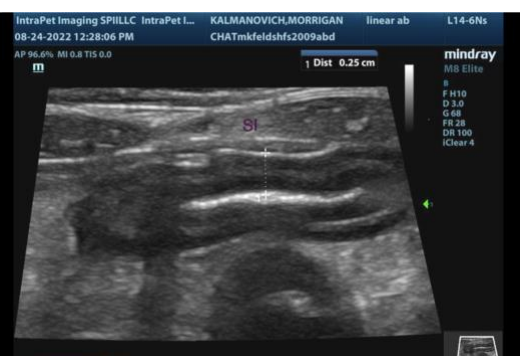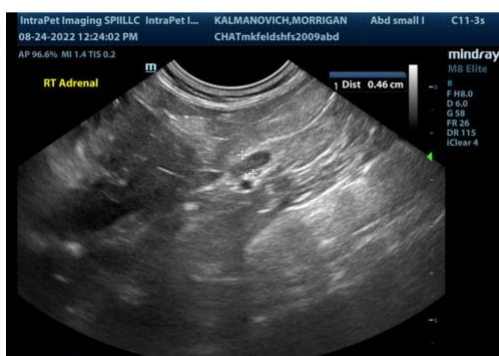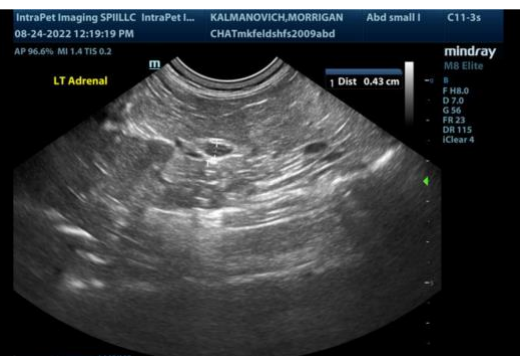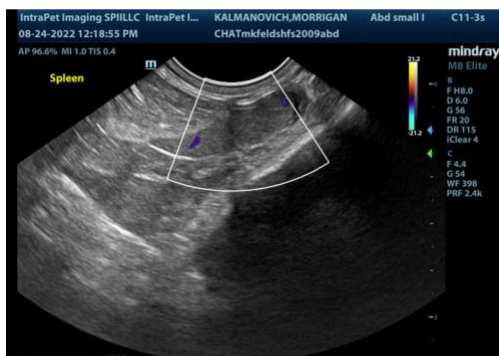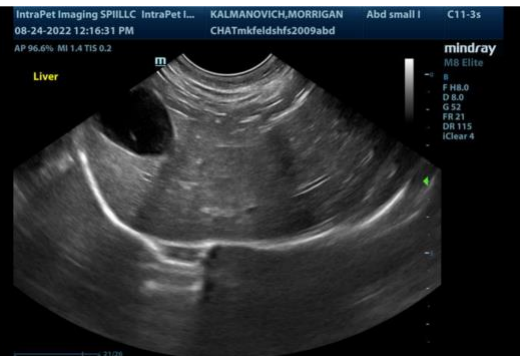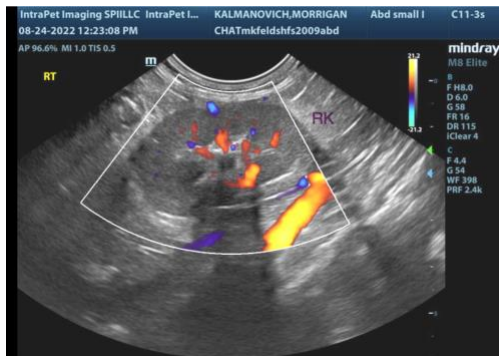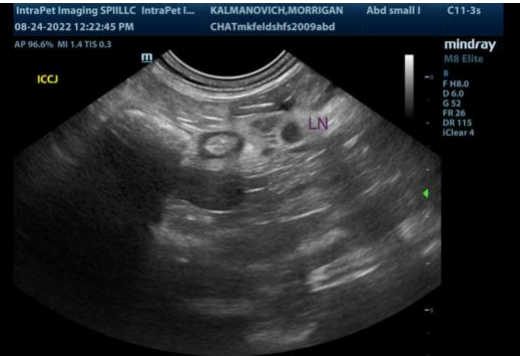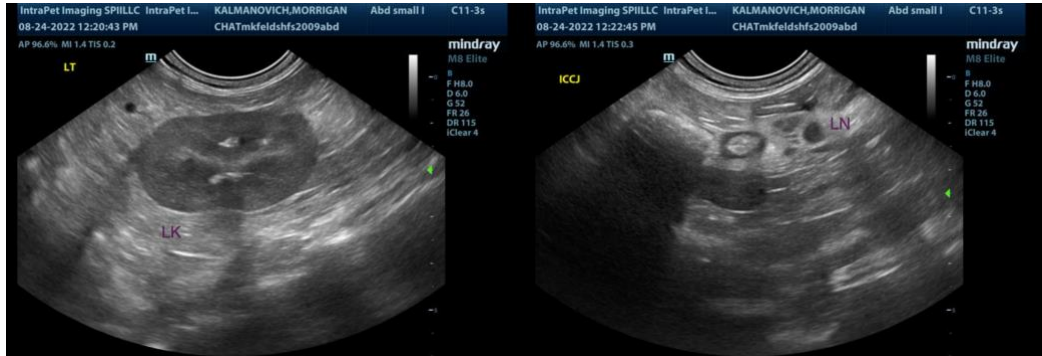
- Bilateral chronic degenerative renal changes. There is evidence of cranial retroperitonitis, the significance of which is unclear.

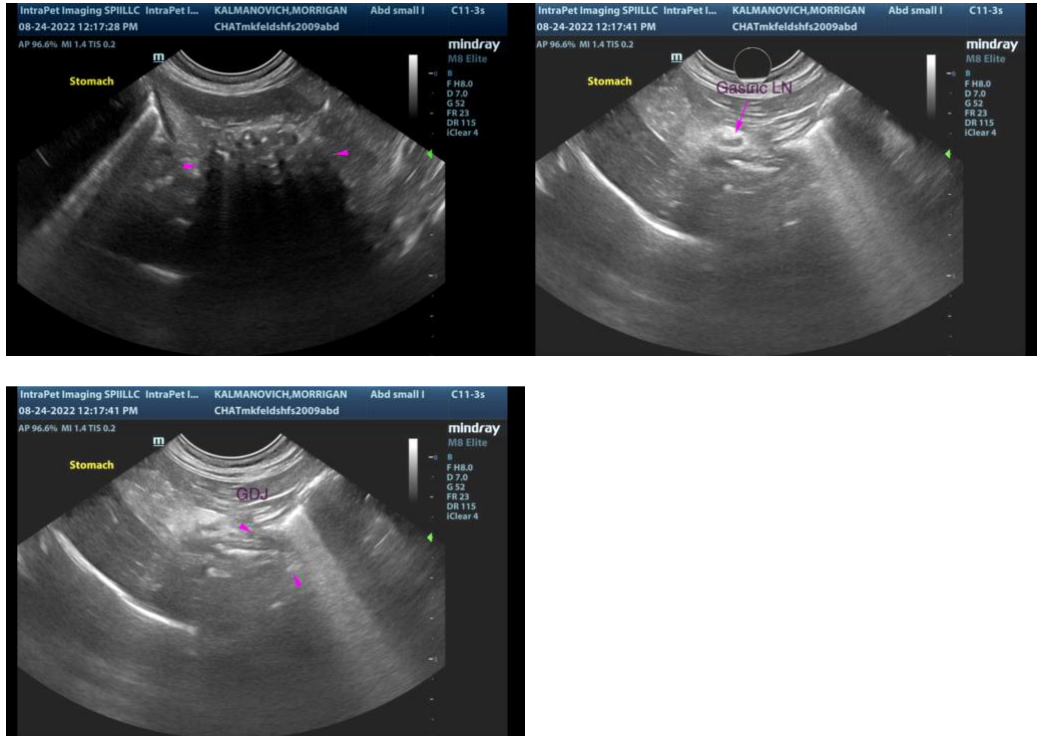
INTERPRETATION OF THE FINDINGS & FURTHER RECOMMENDATIONS

Regarding the GI signs, the following diagnostics/treatments can be considered:

1. GI panel (send to Texas A&M).
2. 6-week novel protein diet trial
3. A fecal evaluation for ova and Giardia
4. Empirical treatment for small intestinal bacterial overgrowth with a 2–4-week course of Tylosin
5. Supplementation with a probiotic with a high colony count (i.e., Provable Forte)
6. Depending on the results of the above diagnostics/therapeutics, GI biopsies (i.e., endoscopic or surgical) may be necessary to get a definitive diagnosis. Three-view thoracic radiographs should be performed prior to any anesthetic event.

Regarding the cranial retroperitonitis, consider a urine culture and sensitivity to assess for occult pyelonephritis.





The information and recommendations provided are based on the images presented by the referring veterinarian/sonographer. No evaluation can be communicated regarding pathology that was not visible in the image/video clips provided.

Thank you for this referral. If the clinical or image interpretation does not parallel your findings or if I can be of any further assistance, please contact me.

Andrea Nicastro, MPH, DVM, Diplomate DACVIM (Small Animal Internal Medicine)
info@SonoPath.com