

**DATE PRESENTING CLINICAL SIGNS**

8/23/21

History: has pancreatitis 6 weeks ago, losing weight, not eating, ADR was treated and recovered has been find since then. Blaze who had similar symptoms passed away so now that Link is acting strange, not eating, ADR O is very worried. Icteric on exam with gr 2/6 heart murmur, bcs 3/9.

**PATIENT**

Link Coker

Current Medications: IVF at 1.5x maintenance, Metronidazole @ 5mg/ml - 53mg [11mL] IV over 30 min, Cerenia @ 10mg/mL - 3.5mg [0.35mL] IV, Ampicillin @ 250mg/mL - 50mg [0.2mL] IV, Mirtax transdermal.

**SPECIES**

Feline

Lab Results: CBC- HCT 25%, PCV 33% NO change to WBC. Chem- ALT 166, ALP 755, GGT 13, Tbili 5.8, fPL- Normal.

**BREED**

Domestic Shorthair

Radiographs/US: brief abdominal us showed no free fluid, obvious masses.

Date of Previous IntraPet Ultrasound: No previous IntraPet scans.

**SEX**

Female Spayed

Sedation: Not needed.

Stat Report: Not requested.

**AGE**

8/21/07

**ULTRASONOGRAPHIC EXAMINATION OF THE ABDOMEN****Urinary System**

The urinary bladder, trigone, and pelvic urethra are normal in thickness and the mucosal surface is smooth. The bladder lumen is moderately distended with anechoic urine. No masses, inflammatory changes or calculi are observed. Ureteral papillae and visualized portion of the proximal urethra, visible to a depth of 2 cm, are normal.

**WEIGHT**

7.8 lbs.

The left kidney is normal size (3.52 cm in length); normal shape and architecture with smooth peripheral margins. There is a normal 1:3 cortex to medulla ratio with minimal to mild loss of corticomedullary distinction. Mild pyelectasia is present (0.16 cm in the longitudinal plane). There is no evidence of nephroliths, infarcts or hydroureter. Renal vasculature is normal.

**INTERPRETED BY**

Andrea Nicastro, DVM,  
Diplomate ACVIM  
(Small Animal Internal  
Medicine)

The right kidney is normal size (3.74 cm in length); normal shape and architecture with smooth peripheral margins. There is a normal 1:3 cortex to medulla ratio with minimal to mild loss of corticomedullary distinction. Trace pyelectasia is present (0.12 cm in the longitudinal plane). There is no evidence of nephroliths, infarcts or hydroureter. Renal vasculature is normal.

**HOSPITAL NAME**

Everhart Veterinary  
Center

**Adrenal Glands**

The left adrenal gland is upper limits of normal size (0.56 cm width). Normal shape and glandular echogenicity. The phrenicoabdominal vein and surrounding vasculature are normal.

**REFERRING VET**

Dr. Betta

The right adrenal gland is normal size (0.38 cm width). Normal shape and glandular echogenicity. The phrenicoabdominal vein and surrounding vasculature are normal.

**INVOICE**

11693kk

**Spleen**

The spleen is contracted (0.47 cm in width at the level of the hilus) with normal curvilinear peripheral contours. The parenchyma is homogeneous. No focal lesions are observed. Splenic vasculature is normal with no evidence of thrombosis.

**Liver**

The liver is subjectively enlarged with slightly swollen peripheral contours. The parenchyma is hyperechoic relative to the spleen and diffusely homogeneous in appearance. No distinct focal lesions are

observed. Vascular and biliary tracts are of normal volume with no evidence of congestion. The gall bladder is mildly distended. The wall is normal in thickness. A small amount of echogenic, gravity-dependent debris is observed. The cystic and common bile ducts are visible but not overtly dilated (the common bile duct lumen measures 0.28 cm at the distal aspect). The walls are mildly thickened. There is no obvious evidence of a luminal obstruction. The duodenal papilla is normal in thickness (0.53 cm in width).

### ***Gastrointestinal***

The gastric lumen is moderately fluid distended and hypomotile. The gastric wall is normal in thickness with a normal layering pattern. The lumen of the proximal duodenum is mildly fluid-distended. The remaining small intestinal lumen is not dilated. The small intestinal wall is normal in thickness with a normal layering pattern and appropriate mural detail. Discreet masses are not identified. The ileocolic junction and colonic wall are normal.

### ***Pancreas***

A portion of the pancreas is not visualized due to the gastric distension. In the visualized portions, no obvious pathology is observed.

### ***Free Abdomen***

The peritoneal cavity is normal. There is no evidence of inflammation or effusion. The abdominal lymph nodes are normal/not visible.

## **ULTRASONOGRAPHIC FINDINGS**

### **Primary Findings:**

- Hepatic changes are non-specific and could be consistent with hepatic lipidosis, inflammatory/infectious disease, infiltrative neoplasia, or other hepatopathy.
- The cystic/common bile duct wall changes are most consistent with cholangitis and/or age-related hyperplasia.
- The gastric luminal distension is most likely secondary to functional ileus with a lower possibility of a pyloric outflow tract obstruction.

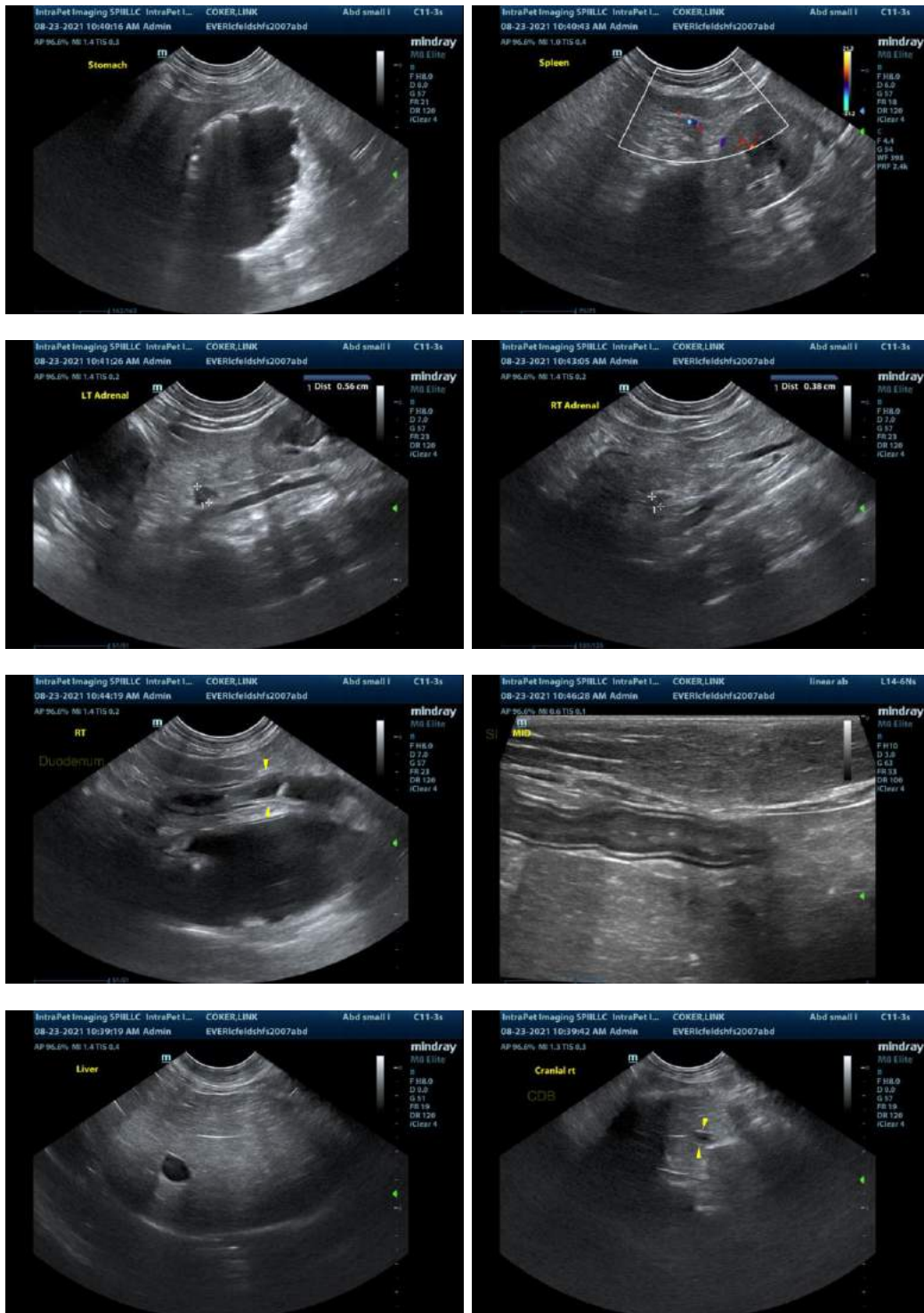
### **Secondary Findings:**

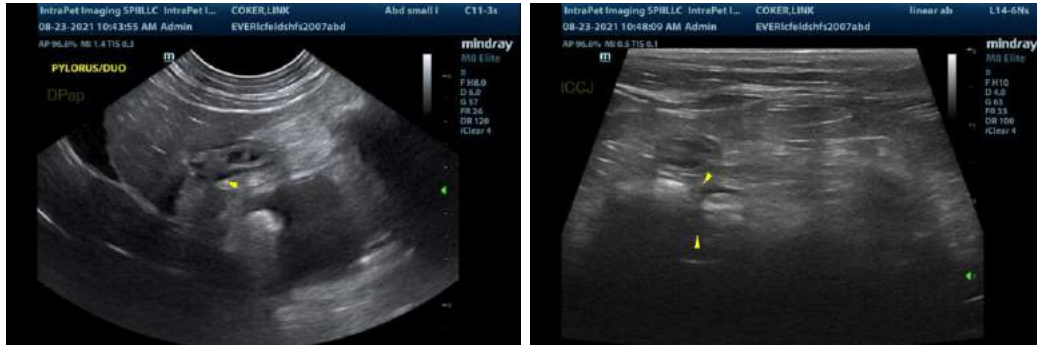
- The splenic contraction is likely secondary to dehydration.
- Bilateral, age-related renal changes with mild pyelectasia.

## **INTERPRETATION OF THE FINDINGS & FURTHER RECOMMENDATIONS**

1. A fine needle aspirate of the liver is recommended (if clotting status is appropriate). A 25-gauge needle should be used. If cytologic evaluation is inconclusive, a surgical liver biopsy with aerobic and anerobic bile cultures can be considered.
2. Continued empirical treatment for cholangiohepatitis/cholangitis is recommended along with nutritional support (i.e., temporary feeding tube) to help prevent/treat hepatic lipidosis.
3. Consider a malabsorption panel to assess for concurrent microscopic gastrointestinal and/or pancreatic disease.

4. Three-view thoracic radiographs are recommended to assess cardiopulmonary status.





The information and recommendations provided are based on the images presented by the referring veterinarian. No evaluation can be communicated regarding pathology that was not visible in the image/video clips provided.

Thank you for this referral. If the clinical or image interpretation does not parallel your findings or if I can be of any further assistance, please contact me.

Andrea Nicastro, DVM, Diplomate ACVIM (*Small Animal Internal Medicine*)  
Andrea.nicastro@sonopath.com