

**DATE PRESENTING CLINICAL SIGNS**

8/23/21 History: Weight loss and dysphagia - Trouble swallowing kibble.

**PATIENT** Current Medications: No current medications.

Jet Lachman Lab Results: CBC/Chemistry results:

**SPECIES** HCT-23%(28.2-52.7), Reticulocyte-16(3-50) consistent with non-regenerative anemia. SDMA-19(0-14), BUN-34(16-37), CR-2.1(0.9-2.3) consistent with CKD. Hypokalemia-3.3(3.7-5.2) has been previously noted, 3.1(5/2019), 3.5(4/2021). T4-3.2 has increased from 2.7 on 4/5/21.  
Feline**BREED** Radiographs: Not provided by the veterinarian.

Domestic Shorthair Date of Previous IntraPet Ultrasound: 4-14-2017 (Echo).

**SEX** Sedation: not needed

Male Neutered Stat Report: not requested

**AGE ULTRASONOGRAPHIC EXAMINATION OF THE ABDOMEN**4/5/05 **Urinary System****WEIGHT** The urinary bladder, trigone, and pelvic urethra are normal in thickness and the mucosal surface is smooth. The bladder lumen is moderately distended with anechoic urine. No masses, inflammatory changes or calculi are observed. Ureteral papillae and visualized portion of the proximal urethra, visible to a depth of 2 cm, are normal.  
10.25 lbs.**INTERPRETED BY** The left kidney is normal size (4.20 cm in length) with a normal shape, smooth peripheral margins, and normal internal architecture. There is moderate loss of corticomedullary distinction. A hyperechoic medullary band is observed adjacent to the corticomedullary junction. Trace pyelectasia is present. There is no evidence of infarcts or hydroureter. Renal vasculature is normal.Andrea Nicastro, DVM,  
Diplomate ACVIM  
(Small Animal Internal  
Medicine)

The right kidney is normal size (4.05 cm in length) with a normal shape, smooth peripheral margins, and normal internal architecture. There is moderate loss of corticomedullary distinction. A hyperechoic medullary band is observed adjacent to the corticomedullary junction. Trace pyelectasia is present. There is no evidence of infarcts or hydroureter. Renal vasculature is normal.

**HOSPITAL NAME**Veterinary Housecall  
Services**Adrenal Glands**

The region of the adrenal glands is evaluated. No obvious pathology is observed.

**REFERRING VET**

Dr. Golden

**Spleen**

The spleen is normal in size (0.87 cm in width at the level of the hilus) with a normal capsular contour. There is appropriate echogenicity and echotexture. No focal lesions are observed. Splenic vasculature is normal.

**INVOICE**

11691kk

**Liver**

The liver is subjectively normal in size with normal curvilinear peripheral contours. The parenchyma is isoechoic relative to the spleen. A few, ill-defined, hypoechoic nodules are observed throughout the parenchyma. The largest one measures 0.86 x 0.77 cm deep on the right side. Hepatic vasculature and intrahepatic biliary tracts are of normal volume with no evidence of congestion. The gall bladder is distended. The wall is normal in thickness. A small amount of suspended echogenic debris is observed within the lumen. The cystic and common bile ducts are visible/tortuous but not overtly dilated. There was no obvious evidence of a luminal obstruction. The duodenal papilla is normal in thickness (0.40 cm).

### ***Gastrointestinal***

The stomach and intestine are free of stasis and exhibit normal peristaltic activity. The gastric lumen is not distended. The gastric wall and pylorus are normal in thickness with a normal layering pattern. The pyloric outflow tract is patent. The small intestinal lumen is not dilated. The small intestinal wall thickness is normal with a normal layering pattern and appropriate mural detail. Discreet masses are not identified. The colonic wall is normal. No obstructive disease is noted.

### ***Pancreas***

The pancreas is diffusely enlarged with slightly irregular peripheral contours. The parenchyma is hypoechoic relative to surrounding omental fat. Several irregular, hypoechoic nodules (the largest measuring 1.19 x 0.55 cm) are observed throughout the parenchyma. The pancreatic duct is visible but not overtly dilated (0.19 cm in diameter). The mesentery effacing the serosal surface is slightly hyperechoic.

### ***Free Abdomen***

There is no evidence of free fluid. The abdominal lymph nodes are normal/not visible.

### ***Other***

A brief echocardiogram reveals no evidence of pericardial effusion. An intermittent arrhythmia is suspected.

## **ULTRASONOGRAPHIC FINDINGS**

### **Primary Findings:**

- The pancreatic changes are suggestive of chronic, active pancreatitis. The nodular lesions may represent benign nodular hyperplasia. However, an early neoplastic process cannot be completely excluded.
- The hepatic changes could be consistent with inflammatory/immune-mediated disease, hepatic lipidosis, infiltrative neoplasia, or other hepatopathy.

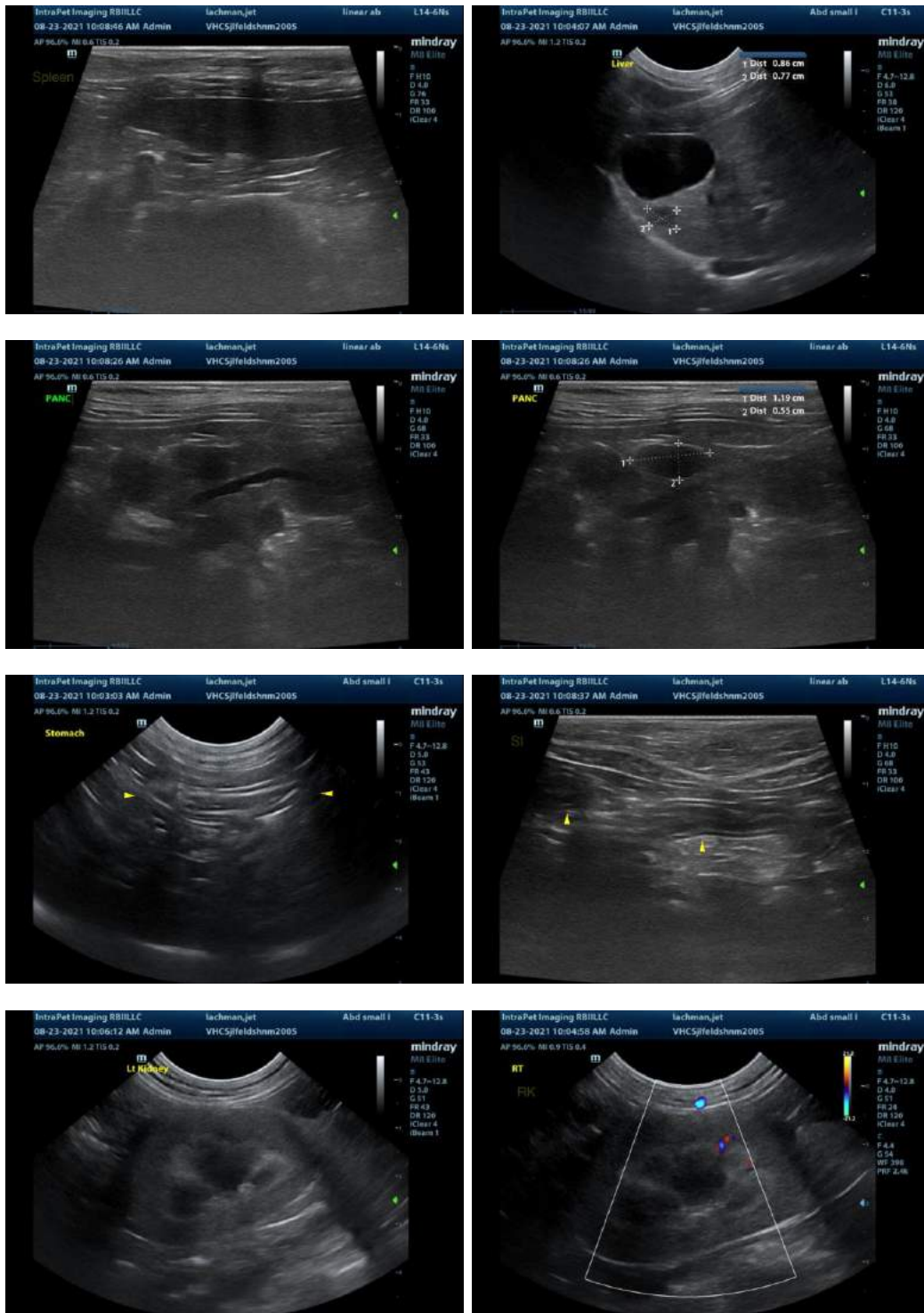
### **Secondary Findings:**

- Bilateral age-related renal pathology.

## **INTERPRETATION OF THE FINDINGS & FURTHER RECOMMENDATIONS**

1. Three-view thoracic radiographs are recommended to assess the esophagus, if not already performed. A barium esophagram, preferably via fluoroscopy, may be warranted depending on the survey radiograph results.
2. Other diagnostic considerations include:
  - a. A malabsorption panel including serum cobalamin, folate, PLI and TLI.
  - b. A fecal evaluation for ova/Giardia
  - c. A 6-week limited antigen diet trial to assess for food allergies
  - d. +/- gastrointestinal and pancreatic biopsies.
3. Given the previous echocardiogram recommendations and the possibility of an intermittent

arrythmia, a repeat full echocardiogram, ECG, and baseline blood pressure measurement are recommended.



**The information and recommendations provided are based on the images presented by the referring veterinarian. No evaluation can be communicated regarding pathology that was not visible in the image/video clips provided.**

Thank you for this referral. If the clinical or image interpretation does not parallel your findings or if I can be of any further assistance, please contact me.

Andrea Nicastro, DVM, Diplomate ACVIM (*Small Animal Internal Medicine*)  
Andrea.nicastro@sonopath.com