**PATIENT**

Lucy Burnett 52971A

SPECIES

Canine

BREED

Soft-coated Wheaton

SEX

Spayed Female

AGE

2 years, 6 mos

WEIGHT

17.2 kg

INTERPRETED BY

Andrea Nicastro, DVM,
 Diplomate ACVIM
 (Small Animal Internal
 Medicine)

IMAGING PERFORMED BY

Tom McNeill

HOSPITAL NAME

SVS Imaging CT

REFERRING VET

Madison Vet Spec Dr
 McDaniel

INVOICE

11469

DATE

8.22.22

PRESENTING CLINICAL SIGNS

History: Lucy has had decreased appetite, lethargy, and nausea noted since last Tuesday. She was evaluated by her primary veterinarian at that time at which time was sent home with a bland diet and anti-nausea medications. She didn't improve and was re-evaluated on Thursday at which time blood work revealed significantly increase renal values protein in her urine, negative urine culture and 4DX SNAP. She was hospitalized from 8/18-8/20 for IV fluids antibiotics, and supportive care. Lucy was noted to have severe systemic hypertension while hospitalized and was also started on benazepril and amlodipine. Her abdominal ultrasound on Friday did not reveal any significant abnormalities. Lucy's renal values did not improve despite her supportive care and started gaining weight. Lucy's renal values did not improve with her antibiotics (unasin) that she was placed on; however, she was switched to baytril on presentation to MVS to attempt to get better penetration to her kidneys. Her renal values have decreased with supportive care.

Abnormal PE/Chem/CBC/UA Results: pDVM bloodwork 8/18/22: Hct = 34 % RBC = 4.58 WBC ct WNL. Plt = 149. BUN > 180, Creat = 10.2, Phos = 15.2, Alb = 2.3, TP = 4.9 USG of 1030, protein, WBC 8/hpf, RBC>50/HPF and poss cocci, rods present. Baseline cortisol was high. Urine culture was submitted and returned as negative. 8/19/22: BUN 190 crea 10.8 PHOS 14.9 K 3.9 8/20/22: BUN 179 CREA 12.4 Phos 15.5 K 4.1 8/22/22: Creat - 6.7 (0.5 - 1.8) BUN - 112 (7-27) Phos- 11.9 (2.5-6.8) Ca- 9.0 (7.9-12.0) Na- 156 (144-160) K- 2.8 (3.5-5.8) Cl- 113 (109-122) ALB- 1.8 (2.3-4.0) PCV- 42% TS- 5.0

Fifty-nine still images and 4 video clips are available for interpretation.

ULTRASONOGRAPHIC EXAMINATION OF THE ABDOMEN**Urinary System**

The **urinary bladder** is mildly to moderately distended. The wall is normal in thickness with a smooth mucosal surface. Luminal contents are anechoic. A small amount of gas is seen within the bladder lumen. A Foley catheter is observed within the lumen. No cystic calculi are seen.

The **left kidney** is normal size (5.75 cm in length); normal shape and architecture with smooth peripheral margins. There is a normal 1:3 cortex to medulla ratio with mild to moderate loss of corticomedullary distinction. There is no evidence of pyelectasia, nephroliths, infarcts or hydronephrosis. Renal vasculature is normal.

The **right kidney** is normal size (6.04 cm in length); normal shape and architecture with smooth peripheral margins. There is a normal 1:3 cortex to medulla ratio with mild to moderate loss of corticomedullary distinction. There is no evidence of pyelectasia, nephroliths, infarcts or hydronephrosis. Renal vasculature is normal. Trace retroperitoneal fluid is seen.

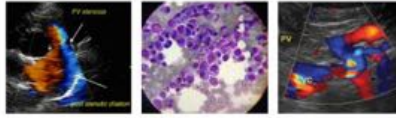
Adrenal Glands

The **left adrenal gland** is normal size (0.60 cm at cranial pole) (0.46 cm at caudal pole); normal shape; homogenous parenchyma. The glandular echogenicity and detail are unremarkable. Capsule, cortex, and medullary definition are normal. The phrenicoabdominal vein and surrounding vasculature are normal.

The **right adrenal gland** is normal size (0.63 cm at cranial pole) (0.51 cm at caudal pole); normal shape; homogenous parenchyma. The glandular echogenicity and detail are unremarkable. Capsule, cortex, and medullary definition are normal. The phrenicoabdominal vein and surrounding vasculature are normal.

Spleen

The **spleen** is normal in size (1.70 cm in width at the level of the hilus) with a normal capsular contour. There is appropriate echogenicity and echotexture. No focal lesions are observed. Splenic vasculature is normal.

**PATIENT**

Lucy Burnett 52971A

SPECIES

Canine

BREED

Soft-coated Wheaten

SEX

Spayed Female

AGE

2 years, 6 mos

WEIGHT

17.2 kg

INTERPRETED BY

Andrea Nicastro, DVM,
Diplomate ACVIM
(Small Animal Internal
Medicine)

IMAGING PERFORMED BY

Tom McNeill

HOSPITAL NAME

SVS Imaging CT

REFERRING VET

Madison Vet Spec Dr
McDaniel

INVOICE

11469

DATE

8.22.22

Liver

The **liver** is subjectively normal in size with normal contours and structure. There is appropriate echogenicity and echotexture. No overt structural evidence of inflammatory, infiltrative, or regenerative pathology is evident. Vascular and biliary tracts are of normal volume with no evidence of congestion. No pathological hepatic lymphadenopathy observed.

The **gall bladder** lumen is moderately distended. The wall is thin and smooth. Luminal contents are anechoic. The cystic and common bile ducts are normal/not seen.

Gastrointestinal

The gastric wall in the region of the fundus is mildly thickened (up to 1.29 cm) with retention of the normal layering pattern. The gastric lumen is not distended. The pyloric outflow tract is patent. The small intestinal lumen is not dilated. One segment of jejunum is mildly thickened (up to 0.46 cm) with retention of the normal layering pattern. The remaining small intestinal segments are normal in thickness with a normal layering pattern and appropriate mural detail. Discreet masses are not identified. The colonic wall is normal. There is no evidence of an obstructive pattern.

Pancreas

The **pancreas** is diffusely prominent in size with minimal deviation from the normal peripheral contours. The parenchyma is mildly hypoechoic relative to surrounding omental fat and appears mildly edematous. No focal lesions are observed. The pancreatic duct is not overtly dilated.

Free Abdomen

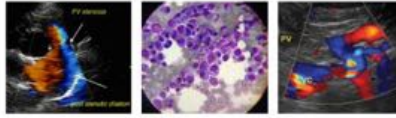
The **mesentery** throughout the abdomen is mildly hyperechoic. Trace free fluid is observed. The medial iliac **lymph nodes** are prominent (the left measures 2.03 x 0.79, the right measures 1.68 x 0.76 cm) with a normal echogenicity. Prominent hepatic and gastric lymph nodes are also seen. In addition, at least 2 prominent mesenteric lymph nodes are visualized, the largest measuring 3.39 cm in length.

ULTRASONOGRAPHIC FINDINGS**Primary Findings**

- Based on the clinical history and sonographic changes, acute on chronic renal failure is suspected. Differentials include infection (i.e., pyelonephritis, Leptospirosis), toxic insult, other. Trace retroperitoneal fluid is seen, likely secondary to underlying renal pathology.

Secondary Findings

- The pancreatic changes could be consistent with mild pancreatitis, increased hydrostatic pressure (i.e., due to fluid overload), other.
- The prominent abdominal lymph nodes are most consistent with reactive lymphadenitis or lymphoid hyperplasia. Neoplastic infiltration is considered less likely.
- The gastric wall changes could be consistent with inflammation, edema, hypertrophy, or less likely, emerging neoplasia.
- The gas within the urinary bladder lumen may have been introduced iatrogenically with placement of the Foley catheter. However, gas-producing bacteria cannot be completely excluded.



PATIENT

Lucy Burnett 52971A

SPECIES

Canine

BREED

Soft-coated Wheaten

SEX

Spayed Female

AGE

2 years, 6 mos

WEIGHT

17.2 kg

INTERPRETED BY

Andrea Nicastro, DVM,
Diplomate ACVIM
(Small Animal Internal
Medicine)

IMAGING PERFORMED BY

Tom McNeill

HOSPITAL NAME

SVS Imaging CT

REFERRING VET

Madison Vet Spec Dr
McDaniel

INVOICE

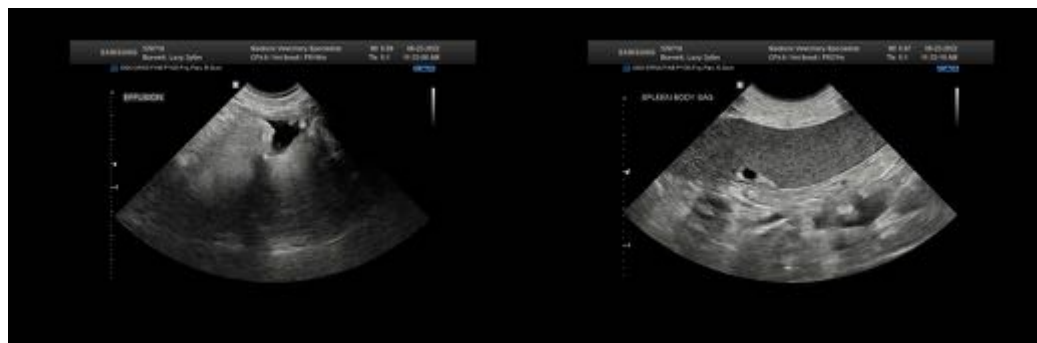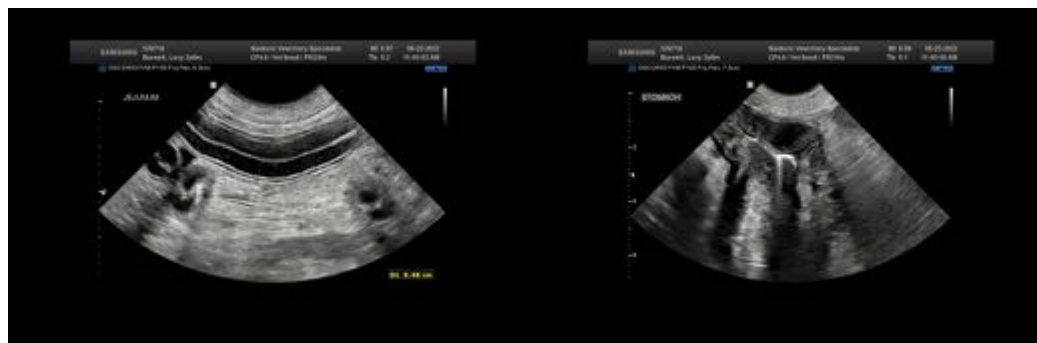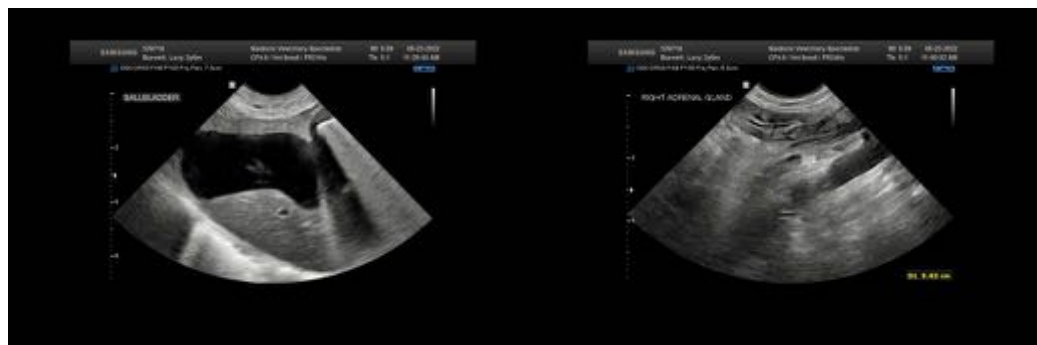11469

DATE

8.22.22

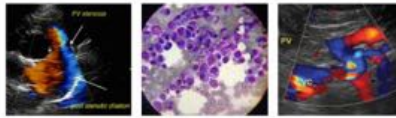
INTERPRETATION OF THE FINDINGS & FURTHER RECOMMENDATIONS

- Leptospirosis testing (i.e., blood and urine PCR, serology) is recommended, if not already performed.
- Also consider a UPC, if the urine culture and sensitivity is negative for infection.
- Continued supportive care for acute on chronic renal failure is recommended including IV fluid diuresis, broad-spectrum antibiotic therapy and symptomatic care. If the renal values do not continue to improve, referral for hemodialysis may be warranted.
- Three-view thoracic radiographs are recommended to assess cardiopulmonary status, particularly if aggressive fluid diuresis is to be continued.
- Fine-needle aspirates of the prominent mesenteric lymph nodes can be considered to assess for round cell neoplasia. However, their sonographic appearance is more consistent with reactive change.



IMAGING PERFORMED BY

svsimagingqc.net 309-737-3070



Clinical Sonography & Telecytology

EDUCATIONAL TELECONSULTATION SERVICES™

1-800-838-4268 info@sonopath.com SonoPath.com

PATIENT

Lucy Burnett 52971A

SPECIES

Canine

BREED

Soft-coated Wheaten

SEX

Spayed Female

AGE

2 years, 6 mos

WEIGHT

17.2 kg

INTERPRETED BY

Andrea Nicastro, DVM,
Diplomate ACVIM
(Small Animal Internal
Medicine)

IMAGING PERFORMED BY

Tom McNeill

HOSPITAL NAME

SVS Imaging CT

REFERRING VET

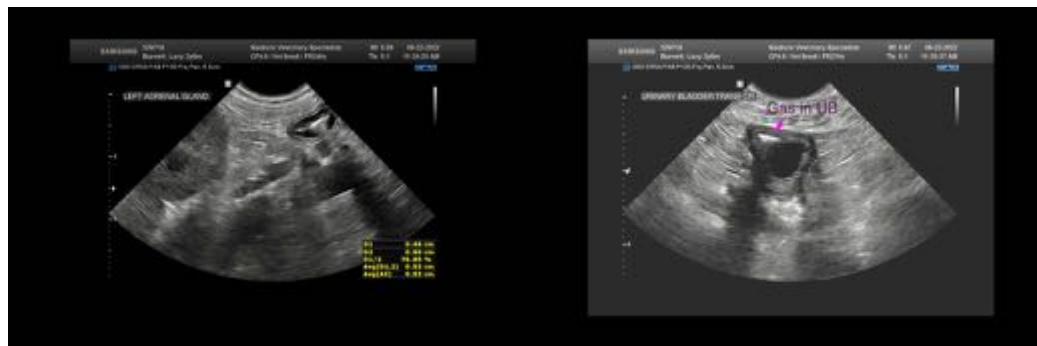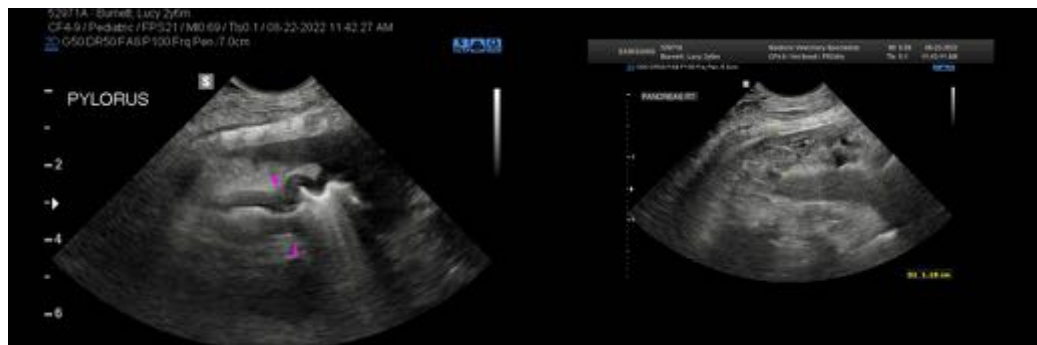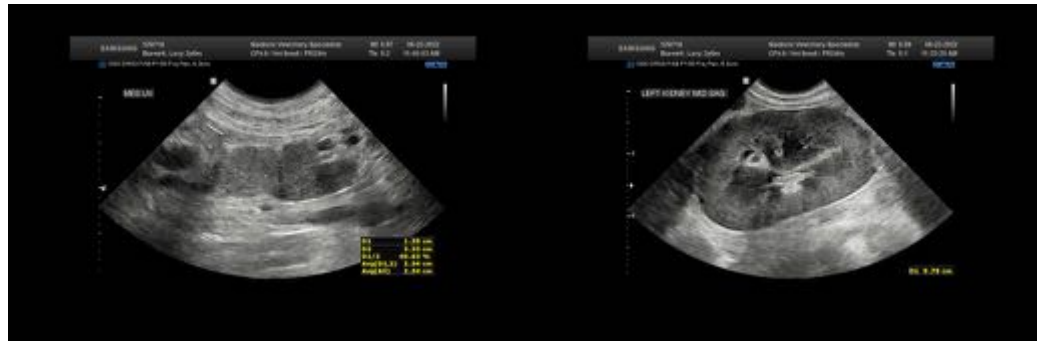Madison Vet Spec Dr
McDaniel

INVOICE

11469

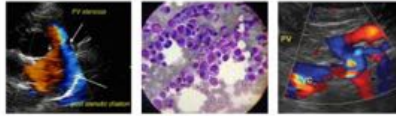
DATE

8.22.22



IMAGING PERFORMED BY

svsimagingqc.net 309-737-3070



Clinical Sonography & Telectology

EDUCATIONAL TELECONSULTATION SERVICES™

1-800-838-4268 info@sonopath.com SonoPath.com

PATIENT

Lucy Burnett 52971A

SPECIES

Canine

BREED

Soft-coated Wheaten

SEX

Spayed Female

AGE

2 years, 6 mos

WEIGHT

17.2 kg

INTERPRETED BY

Andrea Nicastro, DVM,
Diplomate ACVIM
(Small Animal Internal
Medicine)

IMAGING PERFORMED BY

Tom McNeill

HOSPITAL NAME

SVS Imaging CT

REFERRING VET

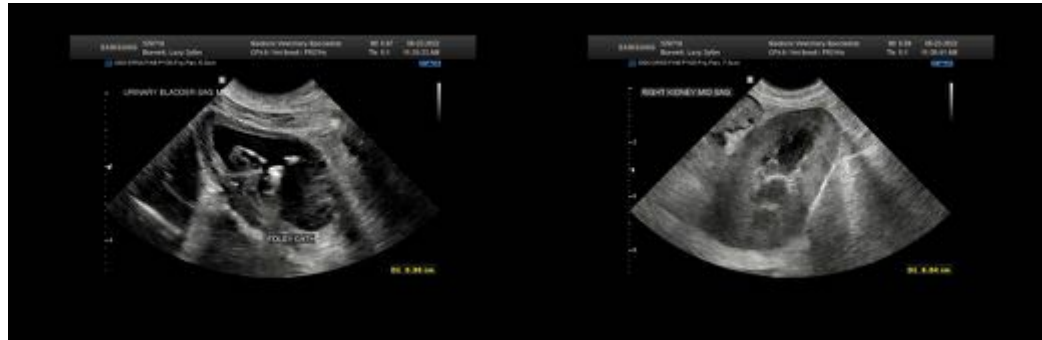Madison Vet Spec Dr
McDaniel

INVOICE

11469

DATE

8.22.22



The information and recommendations provided are based on the images presented by the referring veterinarian/sonographer. No evaluation can be communicated regarding pathology that was not visible in the image/video clips provided.

Thank you for this referral. If the clinical or image interpretation does not parallel your findings or if I can be of any further assistance, please contact me.

Andrea Nicastro, MPH, DVM, Diplomate DACVIM (Small Animal Internal Medicine)
info@SonoPath.com