



PATIENT

Lily Sheehan

PRESENTING CLINICAL SIGNS

History: vomiting profusely.

SPECIES

Canine

ULTRASONOGRAPHIC EXAMINATION OF THE ABDOMEN

Urinary System

The urinary bladder, trigone, and pelvic urethra are normal in thickness and the mucosal surface is smooth. The bladder lumen is moderately distended with anechoic urine. No masses, inflammatory changes or calculi are observed. Ureteral papillae and visualized portion of the proximal urethra, visible to a depth of 2 cm, are normal.

BREED

Yorkie

The left kidney is normal size (3.97 cm in length); normal shape and architecture with smooth peripheral margins. There is a normal 1:3 cortex to medulla ratio with normal corticomedullary distinction. There is no evidence of pyelectasia, nephroliths, infarcts or hydronephrosis. Renal vasculature is normal.

SEX

Female spayed

The right kidney is normal size (4.01 cm in length); normal shape and architecture with smooth peripheral margins. There is a normal 1:3 cortex to medulla ratio with normal corticomedullary distinction. There is no evidence of pyelectasia, nephroliths, infarcts or hydronephrosis. Renal vasculature is normal.

AGE

7 Years

Adrenal Glands

The left adrenal gland is normal size (0.55 cm at cranial pole) (0.50 cm at caudal pole) (1.09 cm in length); normal shape; homogenous parenchyma. The glandular echogenicity and detail are unremarkable. Capsule, cortex, and medullary definition are normal. The phrenicoabdominal vein and surrounding vasculature are normal.

WEIGHT

14 lbs.

The right adrenal gland is normal size (0.74 cm at cranial pole) (0.55 cm at caudal pole) (1.67 cm in length); normal shape; homogenous parenchyma. The glandular echogenicity and detail are unremarkable. Capsule, cortex, and medullary definition are normal. The phrenicoabdominal vein and surrounding vasculature are normal.

INTERPRETED BY

Andrea Nicastro, DVM,
Diplomate ACVIM
(Small Animal Internal
Medicine)

Spleen

The spleen is normal in size (0.88 cm in width at the level of the hilus) with a normal capsular contour. There is appropriate echogenicity and echotexture. No focal lesions are observed. Splenic vasculature is normal.

IMAGING PERFORMED BY

Jenn

Liver

The liver is subjectively normal in size with normal contours and structure. There is appropriate echogenicity and echotexture. No overt structural evidence of inflammatory, infiltrative, or regenerative pathology is evident. Vascular and biliary tracts are of normal volume with no evidence of congestion. No pathological hepatic lymphadenopathy observed. The gall bladder lumen is moderately distended. The wall is thin and smooth. Luminal contents are anechoic. The cystic and common bile ducts are normal/not seen.

HOSPITAL NAME

Rockaway Animal
Hospital

REFERRING VET

Dr. Maniar

INVOICE

11688kk

DATE

8/21/21

Gastrointestinal

The stomach and intestine are free of stasis and exhibit normal peristaltic activity. The gastric lumen is not distended. The gastric wall and pylorus are normal in thickness with a normal layering pattern. The pyloric outflow tract is patent. The small intestinal lumen is not dilated. The small intestinal wall thickness is normal with a normal layering pattern and appropriate mural detail. Discreet masses are not identified. The colonic wall is normal. No obstructive disease is noted.



PATIENT

Pancreas

Lily Sheehan

The region of the pancreas is isoechoic relative to surrounding omental fat. No obvious parenchymal abnormalities are observed. There is no evidence of regional inflammation or effusion.

SPECIES

Free Abdomen

Canine

The peritoneal cavity is normal. There is no evidence of inflammation or effusion. The abdominal lymph nodes are normal/not visible.

BREED

Other

Yorkie

A brief echocardiogram reveals no evidence of pericardial effusion.

SEX

- Unremarkable abdomen.

Female spayed

**An obvious cause for the patient's clinical signs is not identified in this study. There is no obvious evidence of foreign body/obstruction. Acute gastroenteritis is suspected. However, low-grade pancreatitis or underlying metabolic disease cannot be completely excluded.

AGE

7 Years

INTERPRETATION OF THE FINDINGS & FURTHER RECOMMENDATIONS

WEIGHT

14 lbs.

1. Baseline lab work including a CBC chemistry panel and urinalysis is recommended if not already performed as well as a fecal evaluation for ova and giardia. Also consider a malabsorption panel including serum cobalamin, folate, PLI and TLI.
2. Supportive care for acute gastroenteritis is recommended.
3. If clinical signs do not improve within 48-72 hours of supportive care, consider a more advanced GI work up.

INTERPRETED BY

Andrea Nicastro, DVM,
Diplomate ACVIM
(Small Animal Internal
Medicine)

IMAGING PERFORMED BY

Jenn

HOSPITAL NAME

Rockaway Animal
Hospital

REFERRING VET

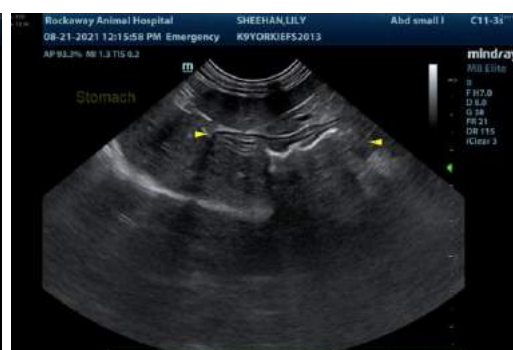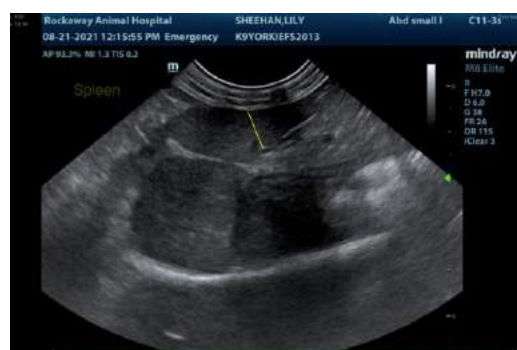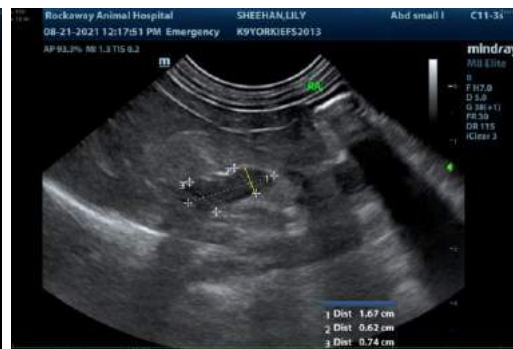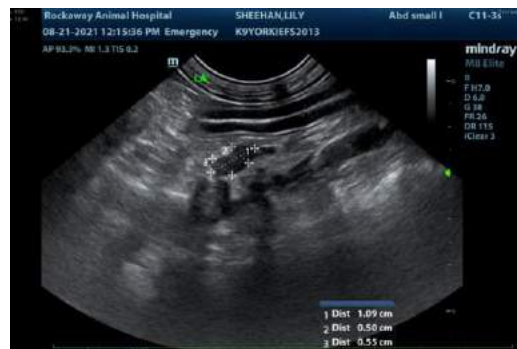Dr. Maniar

INVOICE

11688kk

DATE

8/21/21





PATIENT

Lily Sheehan

SPECIES

Canine

BREED

Yorkie

SEX

Female spayed

AGE

7 Years

WEIGHT

14 lbs.

INTERPRETED BY

Andrea Nicastro, DVM,
Diplomate ACVIM
(Small Animal Internal
Medicine)

IMAGING PERFORMED BY

Jenn

HOSPITAL NAME

Rockaway Animal
Hospital

REFERRING VET

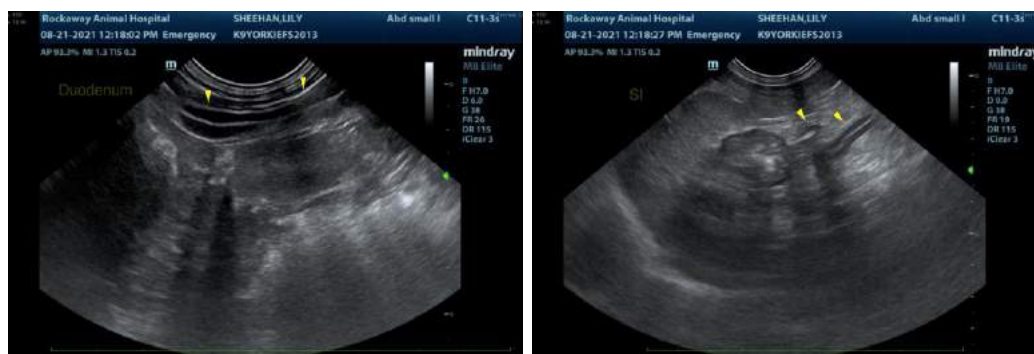
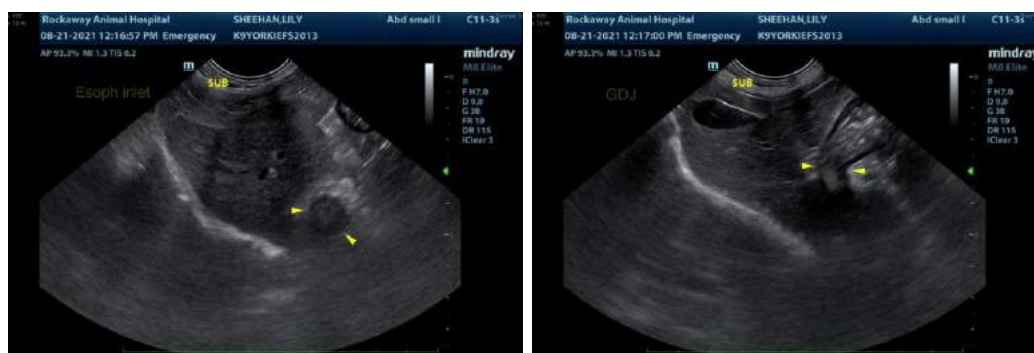
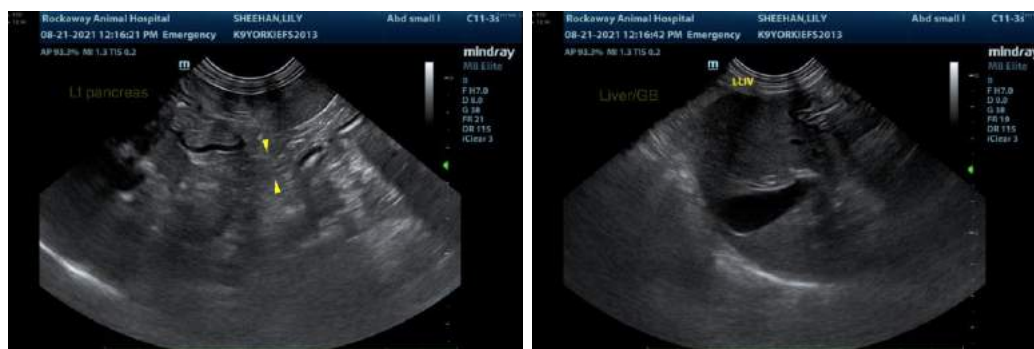
Dr. Maniar

INVOICE

11688kk

DATE

8/21/21



The information and recommendations provided are based on the images presented by the referring veterinarian. No evaluation can be communicated regarding pathology that was not visible in the image/video clips provided.

Thank you for this referral. If the clinical or image interpretation does not parallel your findings or if I can be of any further assistance, please contact me.

Andrea Nicastro, DVM, Diplomate ACVIM (Small Animal Internal Medicine)
Andrea.nicastro@sonopath.com