



PATIENT PRESENTING CLINICAL SIGNS

Cruncher Guerre **History:** Patient is anorexic, extremely lethargic, has enlarged liver silhouette on radiographs. Abnormal blood work - WBC 71.51.

SPECIES **Abnormal PE/Chem/CBC/UA Results:** WBC 71.51, neu. 67.69, mono 2.48, BUN 49.3, creatinine 3.1, glob. 4.4, chol. 450, ALP 254.

Canine

ULTRASONOGRAPHIC EXAMINATION OF THE ABDOMEN

BREED *Urinary System*

Pitbull Terrier

The **urinary bladder** wall is normal in thickness and the mucosal surface is smooth. The bladder lumen is moderately distended with anechoic urine. No masses, inflammatory changes or calculi are observed. Ureteral papillae and visualized portion of the proximal urethra, visible to a depth of 2 cm, are normal.

SEX

Intact Male

The **prostate** is severely enlarged (4.94 cm in width) with irregular peripheral contours, which are difficult to discern. The parenchyma is hyperechoic relative to surrounding omental fat and heterogenous in appearance, with several, varying-sized parenchymal and paraprostatic cysts. At least one of the paraprostatic cysts contains echogenic material. Subcapsular fluid is observed. The surrounding mesentery is hyperechoic. The prostatic urethra is not overtly dilated.

AGE

11 years

The **left kidney** is normal size (7.42 cm in length); normal shape and smooth peripheral margins. The cortex is heterogenous. There is mild loss of corticomedullary distinction. Severe pyelectasia/hydronephrosis is present (1.90 cm in the transverse plane). There is suspected proximal ureteral dilation. There is no evidence of nephroliths. Surrounding mesentery is mildly hyperechoic.

WEIGHT

71.8 lbs

The **right kidney** is normal size (7.61 cm in length); normal shape and smooth peripheral margins. The cortex is heterogenous. There is mild loss of corticomedullary distinction. Severe pyelectasia/hydronephrosis is present (0.99 cm in the transverse plane). The proximal ureteral is dilated (0.82 cm in diameter). There is no evidence of nephroliths. Surrounding mesentery is mildly hyperechoic.

INTERPRETED BY

Andrea Nicastro,
DVM, Diplomate
ACVIM (*Small Animal
Internal Medicine*)

IMAGING PERFORMED BY

Kelly Vazquez

HOSPITAL NAME

Animal Paradise Hosp

Spleen

The **spleen** is normal in size (1.54 cm in width at the level of the hilus) with a normal capsular contour. There is appropriate echogenicity and echotexture. No focal lesions are observed. Splenic vasculature is normal.

REFERRING VET

Dr. Bravo

Liver

The **liver** is subjectively normal in size with normal contours and structure. There is appropriate echogenicity and echotexture. No overt structural evidence of inflammatory, infiltrative, or regenerative pathology is evident. Vascular and biliary tracts are of normal volume with no evidence of congestion. No pathological hepatic lymphadenopathy observed.

INVOICE

11461

DATE

8.19.22

The **gall bladder** lumen is moderately distended. The wall is thin and smooth. A small to moderate amount of aggregated, echogenic, gravity dependent, debris/sludge is observed within the lumen. The cystic and common bile ducts are normal/not seen.

Gastrointestinal

The **gastric lumen** is not distended. The gastric wall and pylorus are normal in thickness with a normal layering pattern. The pyloric outflow tract is patent. The small intestinal lumen is not overtly dilated. A section of thickened bowel (0.48 cm) is observed just caudal to the spleen. It is unclear whether this segment represents small intestine or colon. The remaining small intestinal loops are normal in thickness with a normal layering pattern and appropriate mural detail. There is no evidence of an obstructive pattern.

Pancreas

The base and right limb **pancreas** are prominent to enlarged with slightly irregular peripheral contours. The parenchyma is hypoechoic relative to surrounding omental fat and slightly mottled in appearance. No distinct focal lesions are observed. The pancreatic duct is not overtly dilated. The Surrounding mesentery is mildly hyperechoic.

Free Abdomen

There are areas of mesentery throughout the organ that are hyperechoic. Suspected free fluid is observed in the caudal abdomen. Several enlarged, rounded, hypoechoic to heterogenous mesenteric **lymph nodes** are seen, the largest measuring 3.60 cm in length.

Other

Two still images are available for interpretation. The testicles are subjectively normal in size and shape with slightly heterogenous parenchyma. The left testicle measures 3.28 x 1.61 cm. The right testicle measures 3.42 x 1.83.

ULTRASONOGRAPHIC FINDINGS

Primary Findings

- The prostate changes are consistent with benign prostatic hyperplasia with parenchymal and periprostatic cysts +/- abscessation. Concurrent bacterial prostatitis is also possible.
- Bilateral hydronephrosis/hydroureter, possibly secondary to distal ureteral obstruction, resulting from prostatic pathology. Other differentials include distal ureteroliths, strictures, or neoplasia. The bilateral renal parenchymal changes could be consistent with inflammatory or degenerative disease, or less likely, infiltrative neoplasia.
- The abdominal lymphadenopathy is concerning for infiltrative neoplasia (i.e., round cell tumor). However, lymphadenitis or lymphoid hyperplasia cannot be excluded.
- The pancreatic changes are suggestive of mild, acute or chronic active pancreatitis.
- Retroperitonitis is present, likely secondary to prostatic and renal pathology.

Secondary Findings

- The testicular parenchymal changes are most consistent with age-related remodeling.
- Suspected thickened segment of bowel (small intestine versus colon). Differentials include infiltrative neoplasia, inflammatory disease, hypertrophy, other.

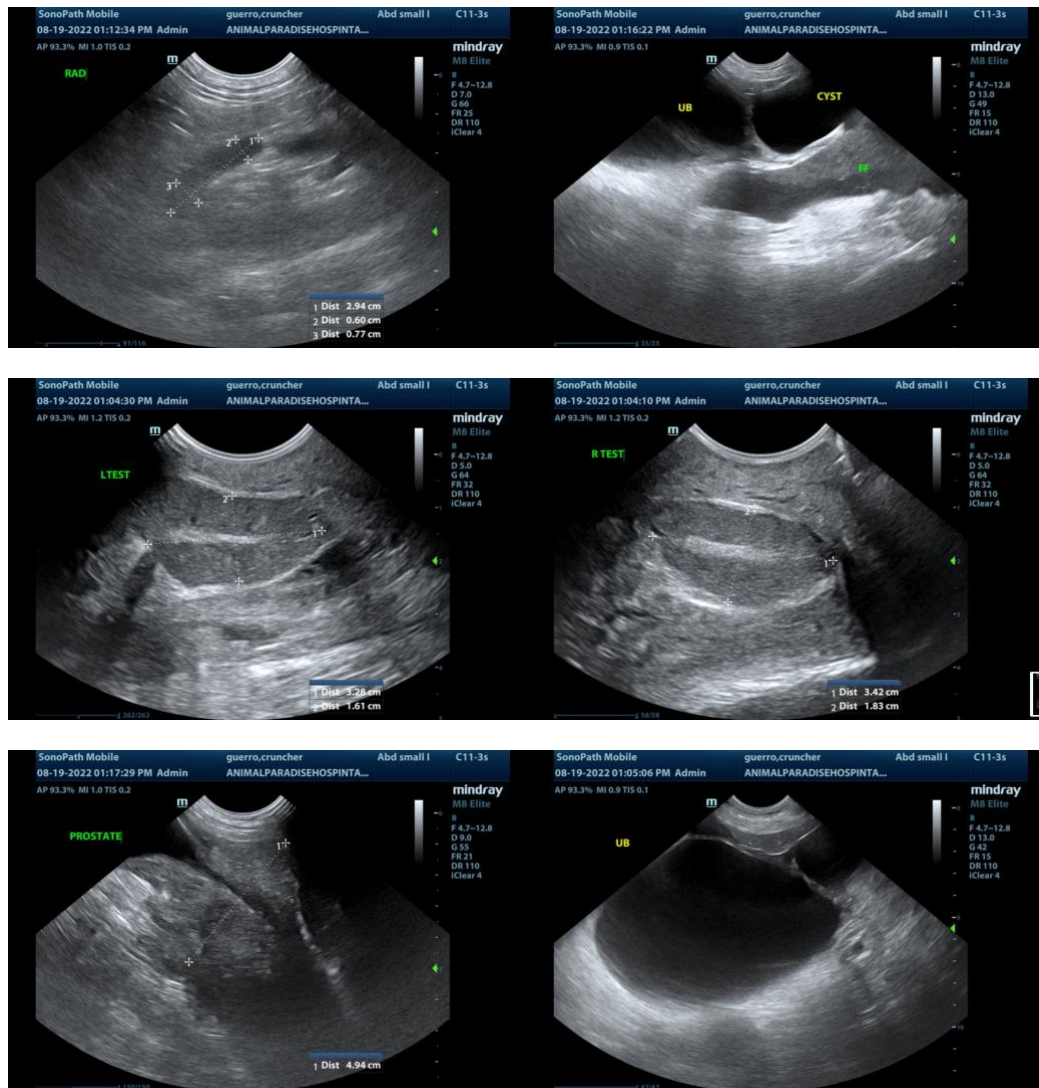
INTERPRETATION OF THE FINDINGS & FURTHER RECOMMENDATIONS

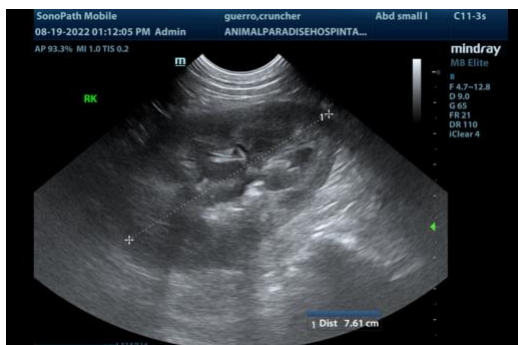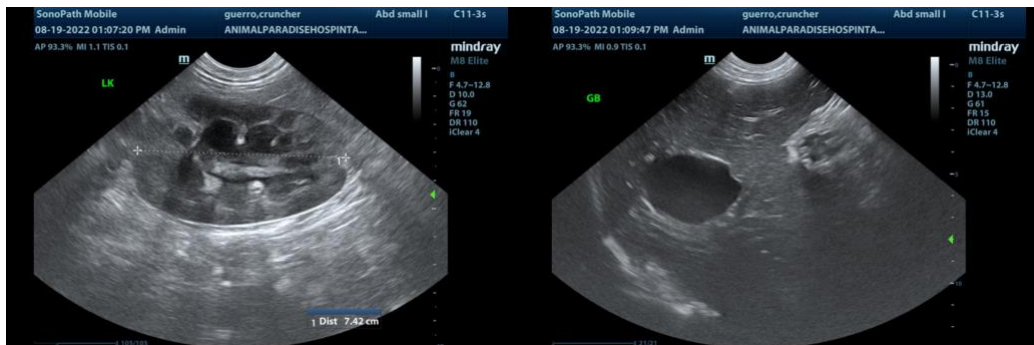
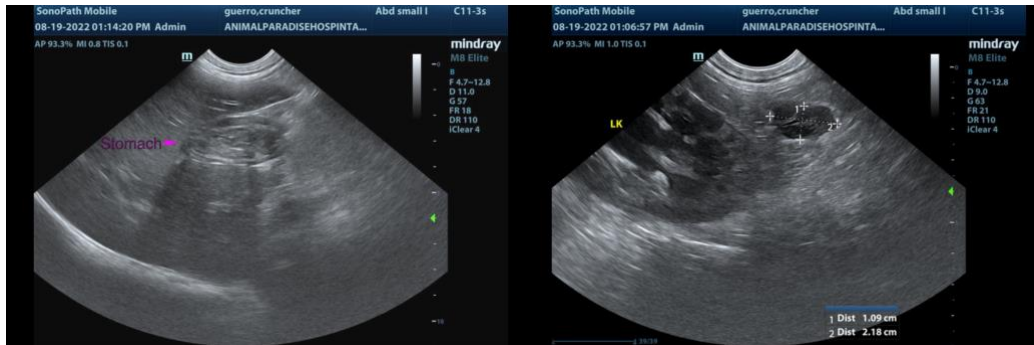
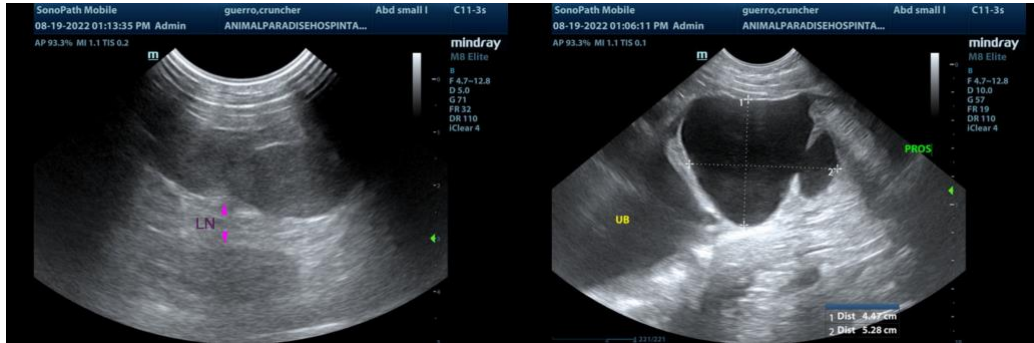
A urine culture and sensitivity is recommended to indirectly assess for bacterial prostatitis.

Also consider fine-needle aspirates of the enlarged mesenteric lymph nodes, if clotting status is appropriate. Twenty-five gauge-needles should be used.

Three-view thoracic radiographs are recommended to assess cardiopulmonary status.

If there is no evidence of neoplasia in the chest or abdomen, consider consultation with a board-certified surgeon to discuss castration along with possible prostatic omentalization. If pursued, consider biopsy of the thickened bowel loop at the time of surgery.





The information and recommendations provided are based on the images presented by the referring veterinarian/sonographer. No evaluation can be communicated regarding pathology that was not visible in the image/video clips provided.

Thank you for this referral. If the clinical or image interpretation does not parallel your findings or if I can be of any further assistance, please contact me.

Andrea Nicastro, MPH, DVM, Diplomate DACVIM (Small Animal Internal Medicine)
info@SonoPath.com