

**DATE PRESENTING CLINICAL SIGNS**

8/19/21

Diarrhea, vomiting, previous u/s reported gastrointestinal disease, rec recheck. ALP 2198, ALT 253, elevated Spec cPL, elevated folate, normal B12, normal T4 and resting cortisol level.

PATIENT

Birdie Turner

Current Medications: Prednisone 10 mg SID, Ursodiol, Probiotics, Metronidazole 125 mg SID

Date of Previous IntraPet Ultrasound: 07/01/2021

SPECIES

Canine

Sedation: not needed

Stat Report: not requested

BREED

Beagle Mix

ULTRASONOGRAPHIC EXAMINATION OF THE ABDOMEN**Urinary System**

The urinary bladder, trigone, and pelvic urethra are normal in thickness and the mucosal surface is smooth. The bladder lumen is moderately distended with anechoic urine. No masses, inflammatory changes or calculi are observed. Ureteral papillae and visualized portion of the proximal urethra, visible to a depth of 2 cm, are normal.

AGE

2013

The left kidney is normal size (5.50 cm in length); normal shape and architecture with smooth peripheral margins. There is a normal 1:3 cortex to medulla ratio with minimal to mild loss of corticomedullary distinction. Moderate pyelectasia is present (0.43 cm in the longitudinal plane). There is no evidence of nephroliths, infarcts or hydroureter. Renal vasculature is normal.

WEIGHT

22.2 lbs.

The right kidney is normal size (5.72 cm in length); normal shape and architecture with smooth peripheral margins. There is a normal 1:3 cortex to medulla ratio with minimal to mild loss of corticomedullary distinction. There is no evidence of pyelectasia, nephroliths, infarcts or hydroureter. Renal vasculature is normal.

INTERPRETED BY

Andrea Nicastro, DVM,
Diplomate ACVIM
(Small Animal Internal
Medicine)

Adrenal Glands

The left adrenal gland is normal size (0.66 cm at cranial pole) (0.64 cm at caudal pole) (1.97 cm in length); normal shape; homogenous parenchyma. The glandular echogenicity and detail are unremarkable. Capsule, cortex, and medullary definition are normal. The phrenicoabdominal vein and surrounding vasculature are normal.

HOSPITAL NAME

Animal Hospital at
Southgate

The right adrenal gland is normal size (0.91 cm at cranial pole) (0.64 cm at caudal pole) (2.19 cm in length); normal shape; homogenous parenchyma. The glandular echogenicity and detail are unremarkable. Capsule, cortex, and medullary definition are normal. The phrenicoabdominal vein and surrounding vasculature are normal.

REFERRING VET

Dr. Jones

Spleen

The spleen is subjectively normal in size (1.33 cm in width at the level of the hilus) with normal curvilinear peripheral contours. The parenchyma is subtly mottled in appearance. A 1.36 x 1.24 cm hypoechoic to heterogeneous +/- cavitated nodule is observed at the cranial lateral aspect. The lesion causes slight capsular expansion. Splenic vasculature appears normal with no evidence of thrombosis.

INVOICE

11670kk

Liver

The liver is subjectively prominent in size with swollen curvilinear peripheral contours. The parenchyma is isoechoic relative to the spleen and exhibits mild heterogeneity. No distinct focal lesions are

observed. Hepatic vasculature and biliary tracts are of normal volume with no evidence of congestion. The gall bladder is moderately distended. The wall is normal in thickness. A moderate to large amount of aggregated, echogenic to mineralized debris/sludge is observed within the lumen, some of which is partially dependent and some of which is suspended and/or adherent. The partially stellate pattern is observed in the region of the gallbladder neck. The cystic and common bile ducts are normal/not seen.

Gastrointestinal

The stomach and intestine are free of stasis and exhibit normal peristaltic activity. The gastric lumen is not distended. The gastric wall and pylorus are normal in thickness with a normal layering pattern. The pyloric outflow tract is patent. The small intestinal lumen is segmentally dilated with chyme. The small intestinal wall thickness is normal with a normal layering pattern and appropriate mural detail. Discreet masses are not identified. The colonic wall is normal. No obstructive disease is noted.

Pancreas

The left limb of the pancreas is prominent to enlarged with slightly irregular peripheral contours. The parenchyma is hypoechoic relative to surrounding omental fat. No focal lesions are observed. The pancreatic duct is not overtly dilated. Surrounding mesentery is slightly hyperechoic. There is no evidence of peripancreatic inflammation or effusion.

Free Abdomen

There is no evidence of free fluid. The abdominal lymph nodes are normal/not visible.

ULTRASONOGRAPHIC FINDINGS

Primary Findings:

- The splenic nodule is a new lesion and is concerning for infiltrative neoplasia. However, benign pathology cannot be completely excluded.
- The pancreatic changes are consistent with acute or chronic, active pancreatitis.
- The gall bladder changes are most consistent with a developing mucocele. However, cholestasis is also a differential. Changes are similar to the previous scan
- The diffuse hepatic changes are non-specific and could be consistent with vacuolar hepatopathy, regenerative nodular hyperplasia, and/or age-related remodeling. Inflammatory and infiltrative disease are considered less likely. Changes are similar to the previous scan.

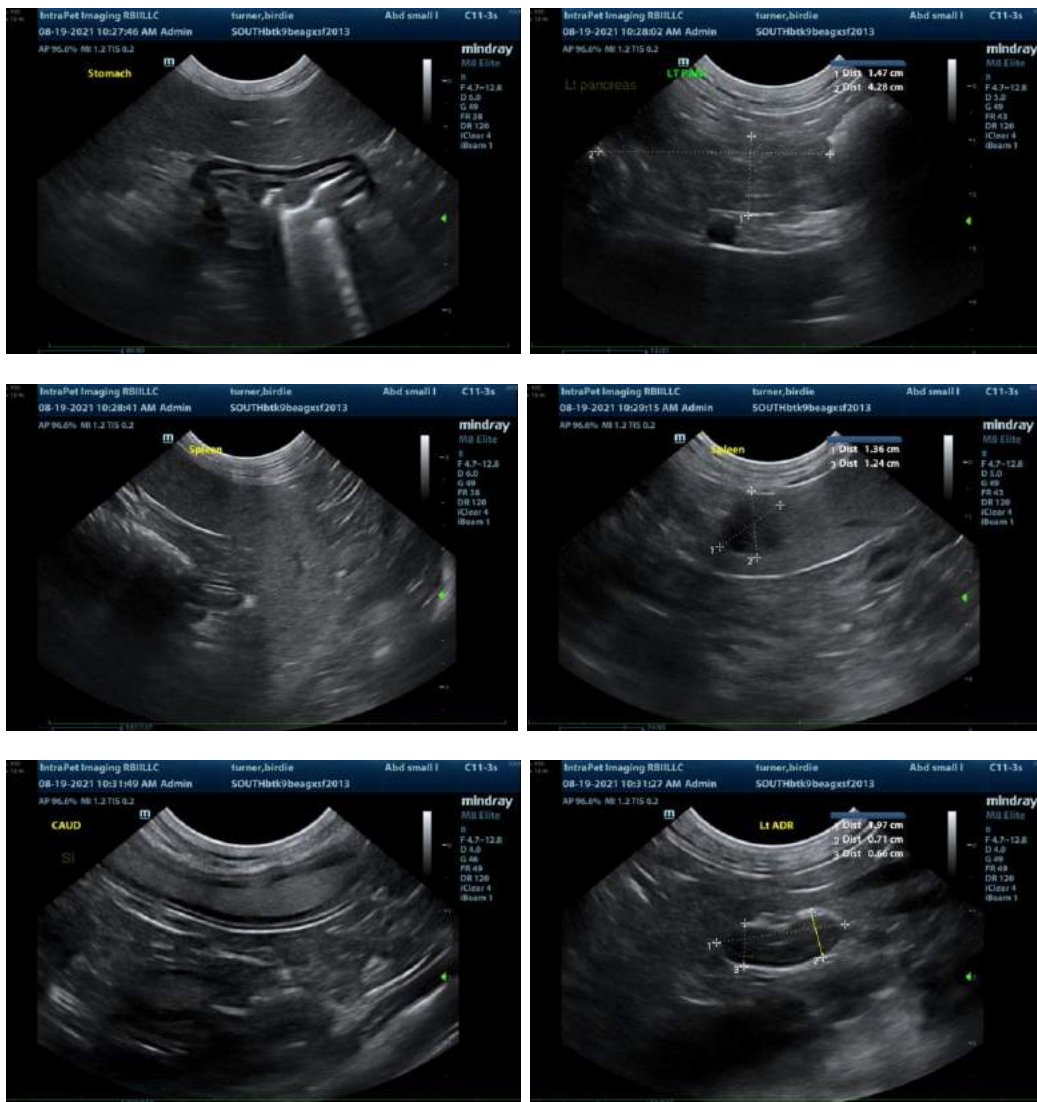
Secondary Findings:

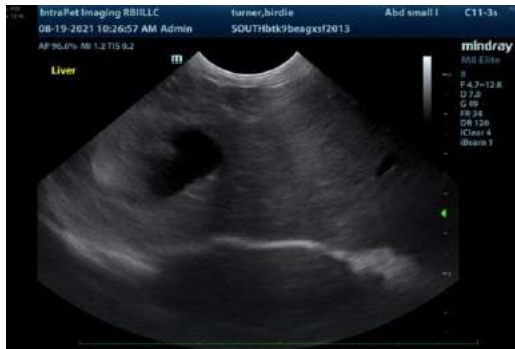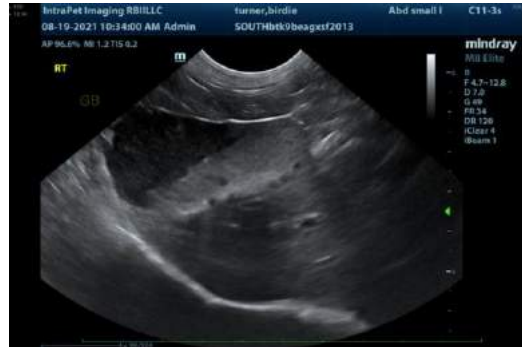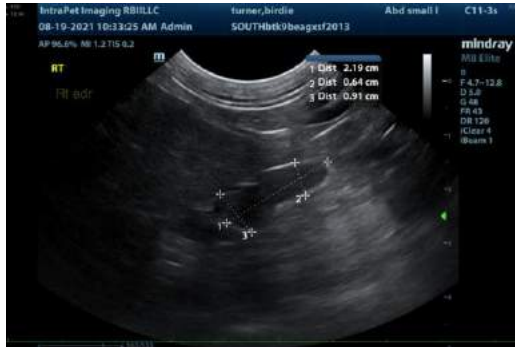- Bilateral, age-related renal changes with left pyelectasia (previously observed).

INTERPRETATION OF THE FINDINGS & FURTHER RECOMMENDATIONS

1. Supportive care for pancreatitis is recommended including gastroprotectants, antiemetics, pain medication, and fluid therapy as needed.
2. Continued Ursodiol therapy is also recommended for the gall bladder sludge. Serial sonographic monitoring (i.e., every 6-8 weeks) is recommended to assess for progression to a fully formed mucocele.
3. Given the pancreatic and gall bladder changes, a prescription low-fat diet should be considered.

4. Given the new splenic nodule, consider the following:
 - a. Three-view thoracic radiographs are recommended to assess for pulmonary metastases.
 - b. Fine needle aspirate of the nodule (if clotting status is appropriate). A 25-gauge needle should be used. Care should be taken to avoid the cavitated areas. If cytologic evaluation is inconclusive, a splenectomy with submission of the spleen for histopathology can be considered. If surgery is pursued, gastrointestinal biopsies are also recommended as well as evaluation of the gall bladder for mucocele formation.
5. Given the elevated folate level, consider empirical treatment for small intestinal bacterial overgrowth (i.e., Tylosin).
6. Also consider initiation of a 6-week limited antigen diet trial.





The information and recommendations provided are based on the images presented by the referring veterinarian. No evaluation can be communicated regarding pathology that was not visible in the image/video clips provided.

Thank you for this referral. If the clinical or image interpretation does not parallel your findings or if I can be of any further assistance, please contact me.

Andrea Nicastro, DVM, Diplomate ACVIM (*Small Animal Internal Medicine*)
Andrea.nicastro@sonopath.com