



**PATIENT PRESENTING CLINICAL SIGNS**

**PATIENT** Brandy Dysart  
**SPECIES** History: Minimal appetite and vomiting. Drinking a lot more water and vomiting it up. O's have not noticed any polyuria - can go all night. Exam unremarkable

**BREED** Canine  
Abnormal PE/Chem/CBC/UA Results: WBC 23.33 Neut 17.39 SDMA 24 CREA 180 ALT 803 ALMP 327 TBIL 21

**BREED** Doodle  
**ULTRASONOGRAPHIC EXAMINATION OF THE ABDOMEN**

**SEX** Female Spayed  
**Urinary System**

The urinary bladder wall is normal in thickness. The mucosal surface in the region of the apex is slightly irregular. The bladder is moderately distended. Luminal contents are anechoic. No cystic calculi are observed. The region of the trigone and the proximal urethra, visible to a depth of 2 cm, are normal.

**AGE**

15 years

The left kidney is normal in size (5.39 cm in length) normal shape and architecture with smooth peripheral margins. The cortex is isoechoic relative to the spleen and mildly thickened with moderate loss of corticomedullary distinction. There is no evidence of pyelectasia, nephroliths, infarcts or hydroureter. Renal vasculature is normal.

**WEIGHT**

25.8 kg

The right kidney is normal in size (6.41 cm in length) with a normal shape, architecture and smooth peripheral margins. The cortex is isoechoic relative to the spleen. There is a normal 1:3 cortex to medulla ratio with mild to moderate loss of corticomedullary distinction. There is no evidence of pyelectasia, nephroliths, infarcts or hydroureter. Renal vasculature is normal.

**INTERPRETED BY**

Andrea Nicastro, DVM,  
Diplomate ACVIM (*Small Animal Internal Medicine*)

**IMAGING PERFORMED BY**

Kelly Reschny

**Adrenal Glands**

The left adrenal gland is mildly enlarged (0.83 cm at cranial pole) (0.82 cm at caudal pole) (2.69 cm in length) with a slightly irregular shape. The parenchyma is mildly heterogenous with some loss of glandular detail. Surrounding vasculature appears normal.

**HOSPITAL NAME**

Buck AH

The right adrenal gland is in normal size (1.92 cm at cranial pole) (0.49 cm at caudal pole) (2.53 cm in length) with a normal shape and homogenous parenchyma. The glandular echogenicity and detail are unremarkable. Capsule, cortex, and medullary definition are normal. The phrenicoabdominal vein and surrounding vasculature appears normal.

**REFERRING VET**

Sommers

**Spleen**

The spleen is normal in size (1.47 cm in width at the level of the hilus) with a normal capsular contour. There is appropriate echogenicity and echotexture. No focal lesions are observed. Splenic vasculature appears normal.

**INVOICE**

14167

**Liver**

The liver is subjectively normal in size with normal curvilinear peripheral contours. The parenchyma is hypoechoic relative to the spleen and slightly mottled in appearance. No distinct focal lesions are observed. Hepatic vasculature and intrahepatic biliary tracts are of normal volume with no evidence of congestion.

**DATE**

8.18.23

The gall bladder is of normal contours and contains some dependent echogenic debris. The wall is normal in thickness. No choleliths are observed. The cystic and common bile ducts are normal/not seen.



**PATIENT**

Brandy Dysart

**SPECIES**

Canine

**BREED**

Doodle

**SEX**

Female Spayed

**AGE**

15 years

**WEIGHT**

25.8 kg

**INTERPRETED BY**

Andrea Nicastro, DVM,  
Diplomate ACVIM (*Small  
Animal Internal Medicine*)

**IMAGING  
PERFORMED BY**

Kelly Reschny

**HOSPITAL NAME**

Buck AH

**REFERRING VET**

Sommers

**INVOICE**

14167

**DATE**

8.18.23

**Gastrointestinal**

The lumen is not distended. The gastric wall is normal in thickness with a normal layering pattern. The small intestinal lumen is not dilated. The small intestinal wall thickness is normal with a normal layering pattern and appropriate mural detail. Discreet masses are not identified. The colonic wall is normal. There is no evidence of an obstructive pattern.

**Pancreas**

The region of the pancreas is isoechoic relative to surrounding omental fat. No obvious parenchymal abnormalities are observed. There is no evidence of regional inflammation or effusion.

**Free Abdomen**

The peritoneal cavity is normal. There is no evidence of inflammation or effusion. The abdominal lymph nodes are normal/not visible.

**ULTRASONOGRAPHIC FINDINGS**

**Primary Findings**

- An obvious cause for the elevated liver enzymes is not identified in the study. However, a microscopic hepatopathy (i.e., bacterial cholangiohepatitis, Leptospirosis, chronic active hepatitis, copper-associated hepatotoxicity, infiltrative neoplasia (less likely)) is suspected.
- Gall bladder debris, non-mucocele

**Secondary Findings**

- Bilateral chronic age-related renal changes
- The left adrenal changes are most consistent with hyperplasia with a lower possibility of emerging neoplasia.

**INTERPRETATION OF THE FINDINGS & FURTHER RECOMMENDATIONS**

- Leptospirosis testing (i.e., blood and urine PCR, serology)
- Cytologic evaluation of the liver should be considered in this patient if clotting status is appropriate. A fine needle aspirate using a 25-gauge needle is recommended. If cytologic evaluation is inconclusive, consider a surgical liver biopsy with aerobic and anaerobic bile cultures and acquisition of additional hepatic tissue samples for copper quantitation.
- If a more conservative approach is desired, consider empirical treatment for cholangiohepatitis/Leptospirosis with amoxicillin-clavulanic acid along with hepatic antioxidants. If liver values do not begin to improve within 7-10 days of initiating therapy, antibiotics should be discontinued and hepatic tissue sampling reconsidered. If values do improve, a 4-6-week course of treatment is recommended.
- Given the patient's age, three-view thoracic radiographs are recommended to assess cardiopulmonary status.



**PATIENT**

Brandy Dysart

**SPECIES**

Canine

**BREED**

Doodle

**SEX**

Female Spayed

**AGE**

15 years

**WEIGHT**

25.8 kg

**INTERPRETED BY**

Andrea Nicastro, DVM,  
Diplomate ACVIM (*Small Animal Internal Medicine*)

**IMAGING PERFORMED BY**

Kelly Reschny

**HOSPITAL NAME**

Buck AH

**REFERRING VET**

Sommers

**INVOICE**

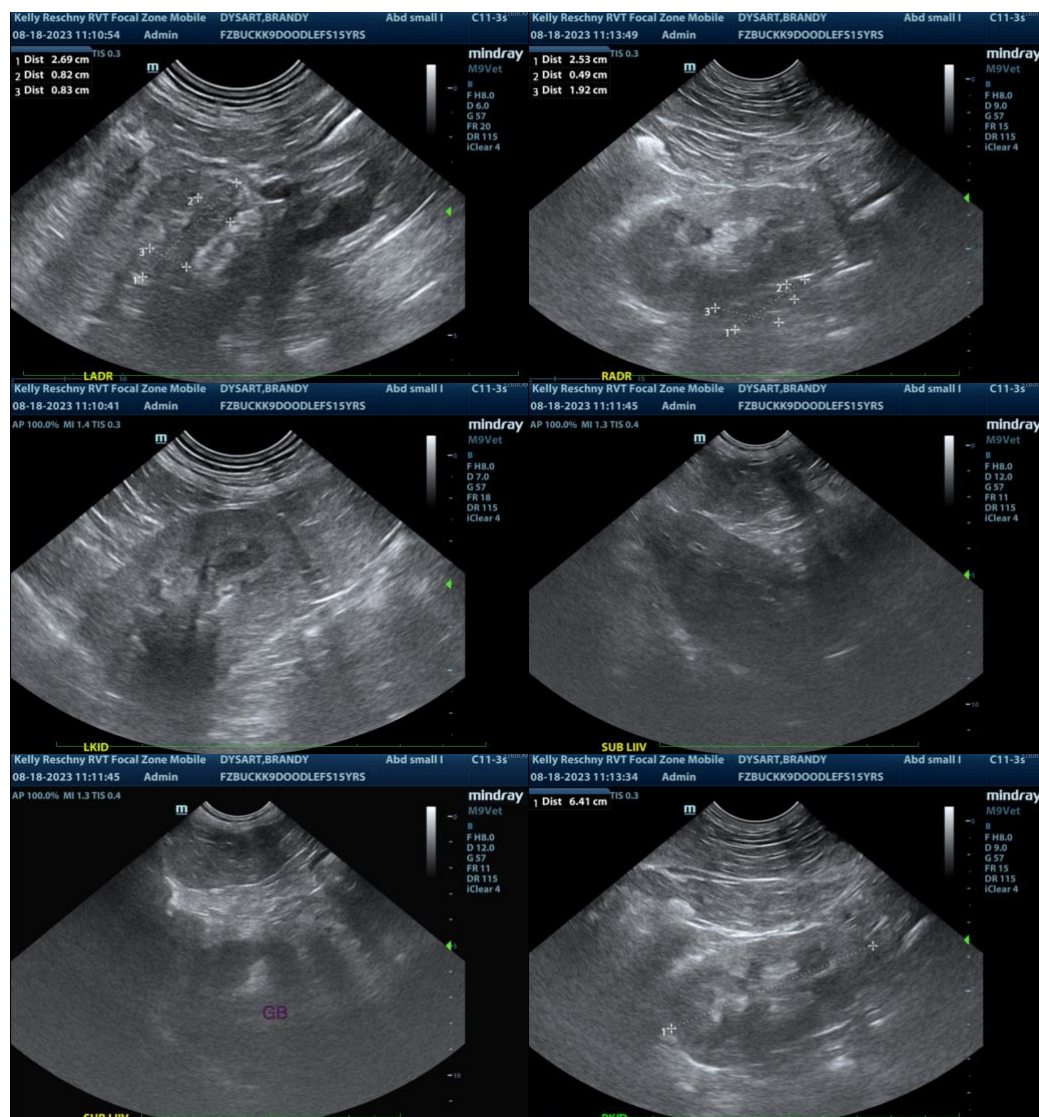
14167

**DATE**

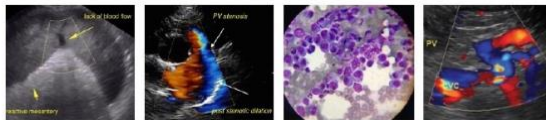
8.18.23

- Regarding the azotemia, consider the following:

1. Urinalysis
2. Urine culture and sensitivity
3. UPC (if proteinuria is present in the absence of infection)
4. Baseline blood pressure measurement
5. Fluid therapy as needed
6. Transition to a prescription renal diet when the patient is eating well



The information and recommendations provided are based on the images presented by the referring veterinarian/sonographer. No evaluation can be communicated regarding pathology that was not visible in the image/video clips provided.



#### PATIENT

Brandy Dysart

Thank you for this referral. If the clinical or image interpretation does not parallel your findings or if I can be of any further assistance, please contact me.

#### SPECIES

Canine

**Andrea Nicastro, MPH, DVM, Diplomate DACVIM (Small Animal Internal Medicine)**  
[info@SonoPath.com](mailto:info@SonoPath.com)

#### BREED

Doodle

#### SEX

Female Spayed

#### AGE

15 years

#### WEIGHT

25.8 kg

#### INTERPRETED BY

Andrea Nicastro, DVM,  
Diplomate ACVIM (*Small  
Animal Internal Medicine*)

#### IMAGING PERFORMED BY

Kelly Reschny

#### HOSPITAL NAME

Buck AH

#### REFERRING VET

Sommers

#### INVOICE

14167

#### DATE

8.18.23