

**DATE PRESENTING CLINICAL SIGNS**

8.18.23 8/14/23 visit: Lethargic for 4-5 days; not walking around as much. When fed, does not get up for food, but if it is brought to P it will eat the food. Unsteady and weak on feet. drinking great, slight decreased appetite. no v/d/c/s. Temp 102.8F CBC/Chem in-house appeared suspicious for IMHA, started P on prednisone 1mg/lb/day. 8/17 visit: P doing better, more active. PE unremarkable. HCT improved from 25 to 29%, WBC increased to 25K from 20K.

PATIENT

Bear Guerrieri

SPECIES

Canine

BREED

Mixed Breed

SEX

Neutered Male

AGE

10/20/2011

WEIGHT

65 lbs

INTERPRETED BY

Andrea Nicastro, DMV,
 Diplomate DACVIM
 (Small Animal
 Internal Medicine)

HOSPITAL NAME

Fullerton AH

REFERRING VET

Dr. Greenfield

INVOICE

14159

Current Medications: Prednisone 30mg BID.

Lab Results: See attached.

Date of Previous IntraPet Ultrasound: No previous.

Sedation: Not required to complete full diagnostic ultrasound.

Stat Report: Requested.

Imaging Performed By: Andi Parkinson, BS, RDMS.

ULTRASONOGRAPHIC EXAMINATION OF THE ABDOMEN**Urinary System**

The urinary bladder wall is normal in thickness and the mucosal surface is smooth. The bladder is mildly distended. Luminal contents are anechoic. No cystic calculi are observed. The region of the trigone and the proximal urethra, visible to a depth of 2 cm, are normal.

The prostate is normal in size (0.84 cm in width) and shape. Parenchyma is homogenous. The prostatic urethra appears normal without evidence of dilation or obstruction.

The left kidney is normal in size (7.41 cm in length) with a normal shape, smooth peripheral margins, and normal internal architecture. The cortex is isoechoic relative to the spleen. There is mild loss of corticomedullary distinction. Several hyperechoic shadowing diverticular foci are observed. There is no evidence of pyelectasia, infarcts or hydronephrosis.

The right kidney is normal in size (6.38 cm in length) with a normal shape, smooth peripheral margins, and normal internal architecture. The cortex is isoechoic relative to the spleen. There is mild loss of corticomedullary distinction. Several hyperechoic shadowing diverticular foci are observed. There is no evidence of pyelectasia, infarcts or hydronephrosis.

Adrenal Glands

The left adrenal gland is borderline enlarged with a slightly irregular shape. A 1.07 x 0.66 cm irregular, hyperechoic nodule is observed at the cranial pole. Glandular echogenicity and detail at the caudal pole are normal. The phrenicoabdominal vein and surrounding vasculature are normal.

The right adrenal gland is in normal size (0.84 cm at cranial pole) (0.62 cm at caudal pole) (2.39 cm in length) with a normal shape and homogenous parenchyma. The glandular echogenicity and detail are unremarkable. Capsule, cortex, and medullary definition are normal. The phrenicoabdominal vein and surrounding vasculature are normal.

Spleen

The spleen is enlarged with irregular peripheral contours. A >7.00 cm irregular heterogenous, cavitated vascular mass is arising from the cranial aspect. Attached to this lesion, a >6.00 cm irregular, avascular fluid-filled structure with echogenic material is also observed. This may represent an extension of the mass itself or an associated hematoma. Surrounding mesentery is hyperechoic. In the remainder of the spleen, the

margins are curvilinear, and the parenchyma is relatively homogenous. Splenic vasculature is normal with no evidence of thrombosis..

Liver

The liver is normal to slightly-prominent in size. The peripheral margin at the left lateral lobe is rounded. The caudal margin is also slightly irregular. The parenchyma is isoechoic relative to the spleen and mildly heterogenous in appearance. A 2.53 x 1.29 cm irregular, slightly hypoechoic nodule with a small amount of associated encapsulated fluid is observed at the caudal aspect. The lesion causes capsular expansion. Hepatic vasculature and intrahepatic biliary tracts are of normal volume with no evidence of congestion.

The gall bladder lumen is moderately distended. The wall is thin and smooth. Luminal contents are mostly anechoic. The cystic and common bile ducts are normal/not seen.

Gastrointestinal

The lumen is not distended. The gastric wall is normal in thickness with a normal layering pattern. The small intestinal lumen is not dilated. The small intestinal wall thickness is normal with a normal layering pattern and appropriate mural detail. Discreet masses are not identified. The colonic wall is normal. There is no evidence of an obstructive pattern.

Pancreas

The region of the pancreas is isoechoic relative to surrounding omental fat. No obvious parenchymal abnormalities are observed. There is no evidence of regional inflammation or effusion.

Free Abdomen

There is no obvious evidence of free fluid. abdominal lymph nodes are normal/not visible.

Other

A brief echocardiogram reveals no evidence of pericardial effusion or obvious right atrial/auricular mass. There is no obvious evidence of pleural effusion in the visible window.

ULTRASONOGRAPHIC FINDINGS

Primary Findings

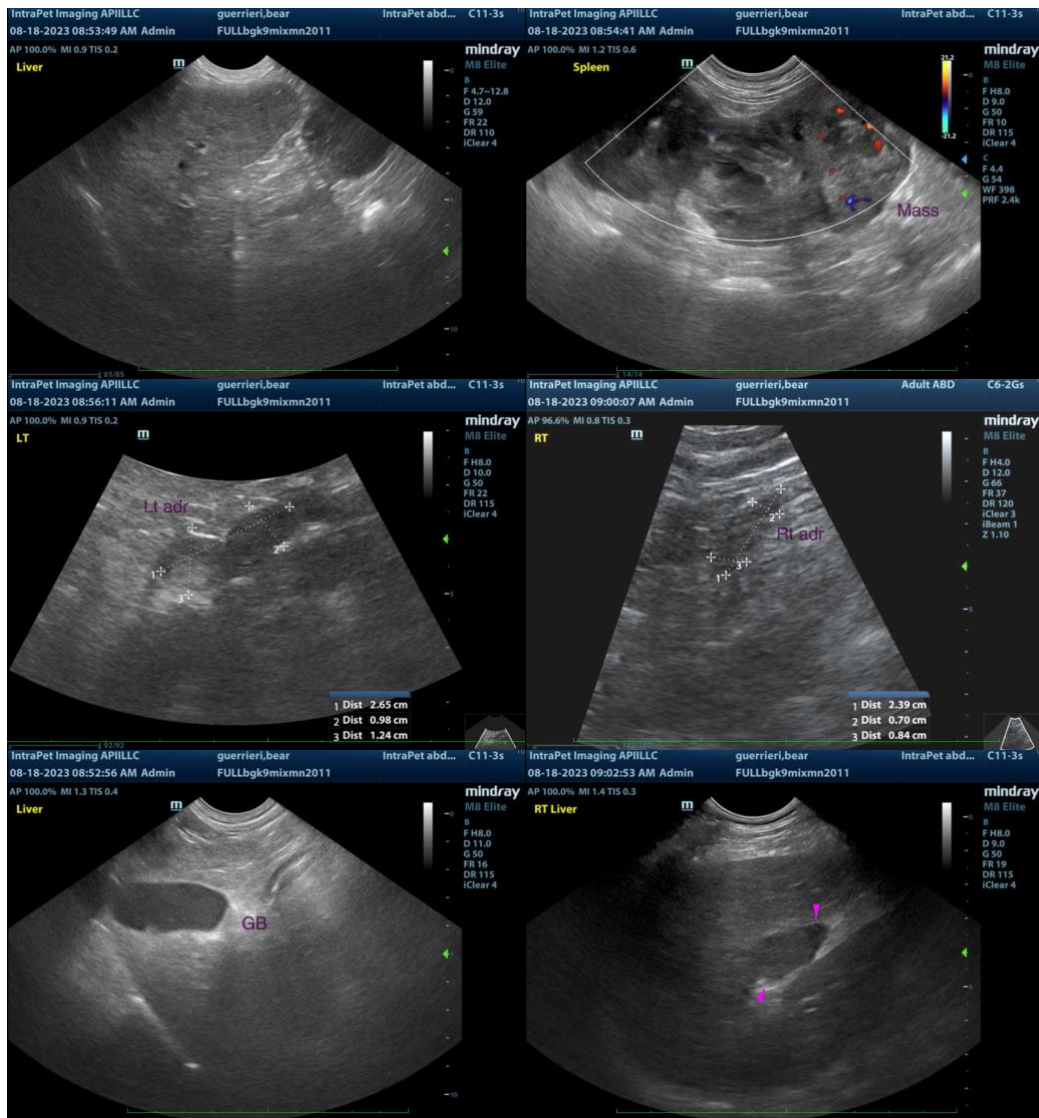
- Large splenic mass with suspected associated hematoma. Neoplasia (i.e., hemangiosarcoma, hemangioma) is suspected with a lower of a non-neoplastic process. Adjacent peritonitis is present.
- The hepatic lesion at the caudal margin may represent a metastasis from the splenic mass. Alternatively, a benign focus (i.e., inflammation, granuloma, regenerative nodule) is possible, but considered less likely. The diffuse hepatic parenchymal changes are nonspecific and may be secondary to regenerative nodular hyperplasia, inflammatory disease, infiltrative neoplasia, or other hepatopathy.

Secondary Findings

- Minor bilateral chronic renal changes with subtle dystrophic mineralization.
- The left adrenal nodule could be consistent with a focus of hyperplasia, emerging adenoma, adenocarcinoma or pheochromocytoma. A benign process is favored.

INTERPRETATION OF THE FINDINGS & FURTHER RECOMMENDATIONS

- Three-view thoracic radiographs are recommended to assess cardiopulmonary status.
- If an aggressive approach is desired and there is no evidence of metastatic disease, consider a splenectomy with submission of the spleen for histopathology, along with biopsies of the liver, including the nodule at the caudal margin. If surgery is pursued, the client should be warned of the possibility of metastasis within the abdomen prior to surgery. If surgery is not pursued, palliative care (including Yunnan Bayaio, pain medication and other supportive measures) should be considered.



The information and recommendations provided are based on the images presented by the referring veterinarian/sonographer. No evaluation can be communicated regarding pathology that was not visible in the image/video clips provided.

Thank you for this referral. If the clinical or image interpretation does not parallel your findings or if I can be of any further assistance, please contact me.

Andrea Nicastro, MPH, DVM, Diplomate DACVIM (Small Animal Internal Medicine)
info@SonoPath.com