



PATIENT PRESENTING CLINICAL SIGNS

Tido Kradey
 History of episodes that last 24 hours with lip-licking, nausea and abdominal pain. No vomiting or diarrhea. On Cerenia 1.7 mg/kg q24 PRN.
SPECIES
 Abnormal PE/Chem/CBC/UA Results: ALP 272, Elevated cPL 249.

Canine ULTRASONOGRAPHIC EXAMINATION OF THE ABDOMEN

BREED *Urinary System*

Chihuahua
 The urinary bladder wall is normal in thickness and the mucosal surface is smooth. The bladder is moderately distended. Luminal contents are anechoic. No cystic calculi are observed. The region of the trigone and the proximal urethra, visible to a depth of 2-3.50 cm, are normal.

SEX
 Neutered Male
 The prostate is normal in size (0.74 cm in width) and shape. Parenchyma is homogenous. The prostatic urethra appears normal without evidence of dilation or obstruction.

AGE
 10 years, 8 mos
 The left kidney is normal in size (4.32 cm in length) with a normal shape, architecture and smooth peripheral margins. The cortex is isoechoic relative to the spleen. There is a normal 1:3 cortex to medulla ratio with minimal loss of corticomedullary distinction. Pinpoint hyperechoic foci are observed within the cortex. One-to-two small cortical cysts are seen. There is no evidence of pyelectasia, nephroliths, infarcts or hydroureter. Renal vasculature is normal.

WEIGHT
 20.4 lbs
 The right kidney is normal in size (4.67 cm in length) with a normal shape, architecture and smooth peripheral margins. The cortex is isoechoic relative to the spleen. There is a normal 1:3 cortex to medulla ratio with minimal loss of corticomedullary distinction. Pinpoint hyperechoic foci are observed within the cortex. One-to-two small cortical cysts are seen. There is no evidence of pyelectasia, nephroliths, infarcts or hydroureter. Renal vasculature is normal.

INTERPRETED BY

Andrea Nicastro, DVM,
 Diplomate ACVIM (Small
 Animal Internal Medicine)

IMAGING PERFORMED BY

Pamela Harrigan, RDCS

Adrenal Glands

The left adrenal gland is normal in size (0.52 cm at cranial pole) (0.59 cm at caudal pole) with a normal shape and homogenous parenchyma. The glandular echogenicity and detail are unremarkable. Capsule, cortex, and medullary definition are normal. The phrenicoabdominal vein and surrounding vasculature are normal.

HOSPITAL NAME

Anchor AH

The right adrenal gland is upper limits of normal size (0.60 cm at cranial pole) (0.54 cm at caudal pole) with a normal shape and homogenous parenchyma. The glandular echogenicity and detail are unremarkable. Capsule, cortex, and medullary definition are normal. The phrenicoabdominal vein and surrounding vasculature are normal.

REFERRING VET

Nicole Mulready

Spleen

The spleen is normal in size (1.05 cm in width at the level of the hilus) with a normal capsular contour. There is appropriate echogenicity and echotexture. A 0.69 x 0.42 cm ill-defined hypoechoic to heterogenous, nodule/area is observed mid-body. Splenic vasculature is normal.

INVOICE

14145

Liver

The liver is subjectively prominent in size with swollen curvilinear peripheral contours. The parenchyma is isoechoic relative to the spleen and exhibits mild heterogeneity. No distinct focal lesions are observed. Hepatic vasculature and biliary tracts are of normal volume with no evidence of congestion.

DATE

8.17.23

The gall bladder lumen is moderately distended. The wall is thin and smooth. A moderate amount of aggregated, echogenic debris/sludge is observed within the lumen, some of which is partially dependent and some of which is adhered to the luminal surface. The cystic and common bile ducts are normal/not seen.



PATIENT

Tido Kradey

SPECIES

Canine

BREED

Chihuahua

SEX

Neutered Male

AGE

10 years, 8 mos

WEIGHT

20.4 lbs

INTERPRETED BY

Andrea Nicastro, DVM,
Diplomate ACVIM (Small
Animal Internal Medicine)

IMAGING PERFORMED BY

Pamela Harrigan, RDCS

HOSPITAL NAME

Anchor AH

REFERRING VET

Nicole Mulready

INVOICE

14145

DATE

8.17.23

Gastrointestinal

The gastric lumen is moderately distended with ingesta. The gastric wall and pylorus are normal in thickness with a normal layering pattern. The pyloric outflow tract is patent. The small intestinal lumen is not dilated. The small intestinal wall is normal in thickness with a normal layering pattern and appropriate mural detail. Discreet masses are not identified. The ileoceocolic junction and colonic wall are normal. The colonic lumen contains shadowing fecal material. There is no evidence of an obstructive pattern.

Pancreas

The right limb of the pancreas is visible with normal curvilinear peripheral contours. The parenchyma is largely isoechoic relative to surrounding omental fat and slightly mottled in appearance. The pancreatic duct is visible but not overtly dilated. There is no evidence of peripancreatic inflammation or effusion.

Free Abdomen

The peritoneal cavity is normal. There is no evidence of inflammation or effusion. The abdominal lymph nodes are normal/not visible.

ULTRASONOGRAPHIC FINDINGS

Primary Findings

- The pancreatic changes are most consistent with age-related parenchymal remodeling, potentially secondary to a prior inflammatory episode, early fibrosis or chronic pancreatitis.
- If the patient was fasted for this study, the presence of ingesta within the gastric lumen could suggest delayed gastric emptying.

Secondary Findings

- The diffuse hepatic changes are non-specific and could be consistent with vacuolar hepatopathy, regenerative nodular hyperplasia, and/or age-related remodeling. Inflammatory and infiltrative disease are considered less likely.
- Minor bilateral chronic renal changes with subtle dystrophic mineralization
- The splenic nodule could be consistent with a benign focus (i.e., lymphoid hyperplasia or similar). Alternatively, an emerging tumor is possible. A benign process is favored.

INTERPRETATION OF THE FINDINGS & FURTHER RECOMMENDATIONS

- Given the chronicity of the patient's clinical signs, consider the following:
 1. Fecal evaluation for internal parasites
 2. Texas GI panel including serum cobalamin and folate, TLI, PLI and resting cortisol level.
 3. Limited antigen or hydrolyzed protein diet trial
 4. Initiation of a probiotic
 5. Three-view thoracic radiographs to assess for occult esophageal disease.
 6. +/- endoscopic or surgical biopsies



PATIENT

Tido Kradey

SPECIES

Canine

BREED

Chihuahua

SEX

Neutered Male

AGE

10 years, 8 mos

WEIGHT

20.4 lbs

INTERPRETED BY

Andrea Nicastro, DVM,
 Diplomate ACVIM (Small
 Animal Internal Medicine)

IMAGING PERFORMED BY

Pamela Harrigan, RDMS

HOSPITAL NAME

Anchor AH

REFERRING VET

Nicole Mulready

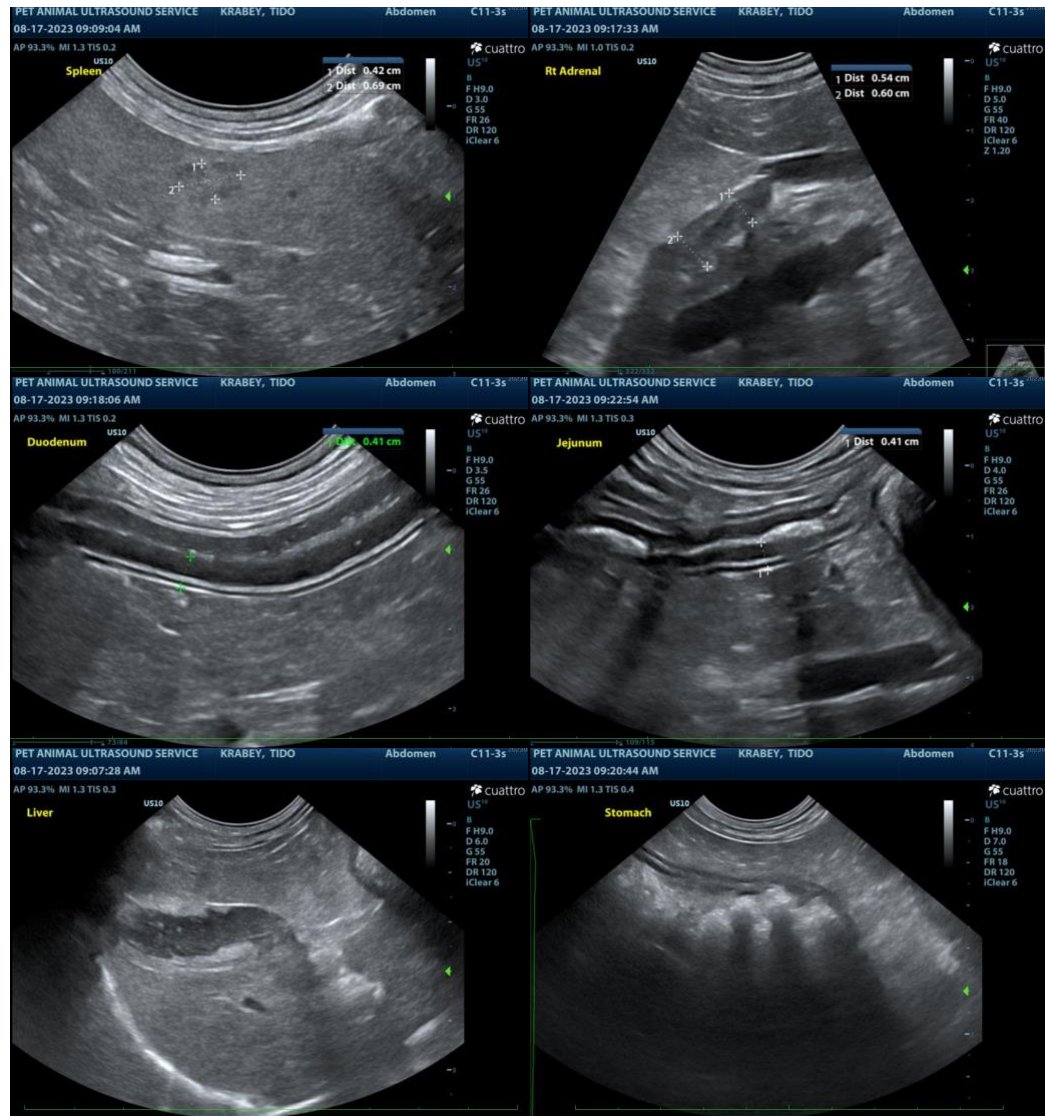
INVOICE

14145

DATE

8.17.23

- Serial monitoring (i.e., every 3-4 months) of the patient's liver values is recommended. If values continue to increase, a repeat abdomen ultrasound +/- a more advanced hepatic work-up (i.e., tissue sampling) may be warranted.
- Consider testing for hyperadrenocorticism with a low-dose dexamethasone suppression test or ACTH stimulation test if clinical signs (i.e., PU/PD) develop in the future.
- Regarding the splenic nodule, consider a fine-needle aspirate (if clotting status is normal). If aspiration is not pursued at this time, consider a recheck ultrasound in 4-6 weeks to assess for growth.





PATIENT

Tido Kradey

SPECIES

Canine

BREED

Chihuahua

SEX

Neutered Male

AGE

10 years, 8 mos

WEIGHT

20.4 lbs

INTERPRETED BY

Andrea Nicastro, DVM,
 Diplomate ACVIM (Small
 Animal Internal Medicine)

IMAGING PERFORMED BY

Pamela Harrigan, RDCS

HOSPITAL NAME

Anchor AH

REFERRING VET

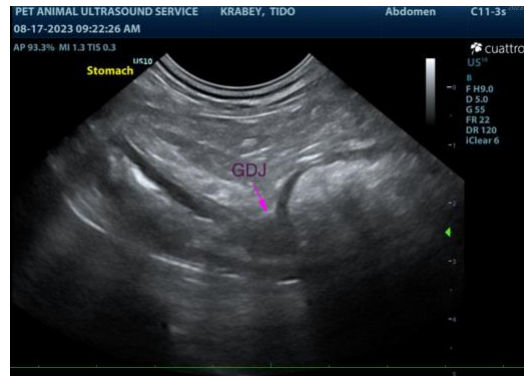Nicole Mulready

INVOICE

14145

DATE

8.17.23



The information and recommendations provided are based on the images presented by the referring veterinarian/sonographer. No evaluation can be communicated regarding pathology that was not visible in the image/video clips provided.

Thank you for this referral. If the clinical or image interpretation does not parallel your findings or if I can be of any further assistance, please contact me.

Andrea Nicastro, MPH, DVM, Diplomate DACVIM (Small Animal Internal Medicine)
info@SonoPath.com