

**DATE PRESENTING CLINICAL SIGNS**

8.17.23 Pet presents for concern with distended abdomen and excessive drinking and panting. PE revealed distended abdomen, more on right side; weight gain, muscle atrophy in hind limbs and along spine.

PATIENT

Brutus Robinson

Current Medications: None listed.
 Lab Results: BW in March and May 2023 revealed elevated ALKP and lipase. Rest WNL.
 Date of Previous IntraPet Ultrasound: No previous.
 Sedation: IV Torb and Midazolam.
 Stat Report: Not requested.
 Imaging Performed By: Rachel Brillhart, RDMS.

SPECIES

Canine

BREED

Pitbull Mix

SEX

Neutered Male

AGE

3/21/2009

WEIGHT

88.2 lbs

INTERPRETED BY

Andrea Nicastro, DMV,
 Diplomate DACVIM
 (Small Animal
 Internal Medicine)

HOSPITAL NAME

Essex Middle
 River VC

REFERRING VET

Dr Franchini

INVOICE

14156

ULTRASONOGRAPHIC EXAMINATION OF THE ABDOMEN**Urinary System**

The urinary bladder is mildly distended. The wall is appropriate thickness for the level of repletion. The mucosal surface in the region of the apex is slightly irregular. A few, tiny cystic calculi are visualized. The region of the trigone and visible portion of the proximal urethra are normal.

The region of the prostate is not visualized due to its pelvic location.

The left kidney is normal in size (7.15 cm in length) with a normal shape, architecture and smooth peripheral margins. There is a normal 1:3 cortex to medulla ratio with mild loss of corticomedullary distinction. Several, small, nonobstructive nephroliths are visualized. There is no evidence of pyelectasia,, infarcts or hydroureter. Renal vasculature is normal.

The right kidney is normal in size (7.05 cm in length) with a normal shape, architecture and smooth peripheral margins. There is a normal 1:3 cortex to medulla ratio with mild to moderate loss of corticomedullary distinction. Several, small, nonobstructive nephroliths are visualized. There is no evidence of pyelectasia,, infarcts or hydroureter. Renal vasculature is normal.

Adrenal Glands

The left adrenal gland is normal in size (0.67 cm at cranial pole) (0.79 cm at caudal pole) (2.75 cm in length) with a normal shape and homogenous parenchyma. The glandular echogenicity and detail are unremarkable. Capsule, cortex, and medullary definition are normal. The phrenicoabdominal vein and surrounding vasculature are normal.

The right adrenal gland is in normal size (0.67 cm at cranial pole) (0.69 cm at caudal pole) (2.87 cm in length) with a normal shape and homogenous parenchyma. The glandular echogenicity and detail are unremarkable. Capsule, cortex, and medullary definition are normal. The phrenicoabdominal vein and surrounding vasculature are normal.

Spleen

The spleen is normal in size (1.86 cm in width at the level of the hilus) with a normal capsular contour. The parenchyma is subtly mottled in appearance. No focal lesions are observed. Splenic vasculature is normal.

Liver

The liver is subjectively normal in size with normal curvilinear peripheral contours. The parenchyma is hypoechoic relative to the spleen and slightly mottled in appearance. A 1.30 cm cyst is observed on the right side, adjacent to the diaphragm. Hepatic vasculature and intrahepatic biliary tracts are of normal volume with no evidence of congestion.

The gall bladder is of normal contours and contains some dependent echogenic debris. The wall is normal

in thickness. No choleliths are observed. The cystic and common bile ducts are normal/not seen.

Gastrointestinal

The stomach and intestine are free of stasis and exhibit normal peristaltic activity. The gastric lumen is not distended. The gastric wall and pylorus are normal in thickness with a normal layering pattern. The pyloric outflow tract is patent. The small intestinal lumen is not dilated. The small intestinal wall is normal in thickness with a normal layering pattern and appropriate mural detail. Discreet masses are not identified. The colonic wall is normal. There is no evidence of an obstructive pattern.

Pancreas

The right limb of the pancreas is visible with normal curvilinear peripheral contours. The parenchyma is largely isoechoic relative to surrounding omental fat and slightly mottled in appearance. The pancreatic duct is visible but not overtly dilated. There is no evidence of peripancreatic inflammation or effusion.

Free Abdomen

The peritoneal cavity is normal. There is no evidence of inflammation or effusion. The abdominal lymph nodes are normal/not visible.

Other

A brief echocardiogram reveals no evidence of pericardial effusion or obvious right atrial/auricular mass. There is no obvious evidence of pleural effusion in the visible window.

ULTRASONOGRAPHIC FINDINGS

Primary Findings

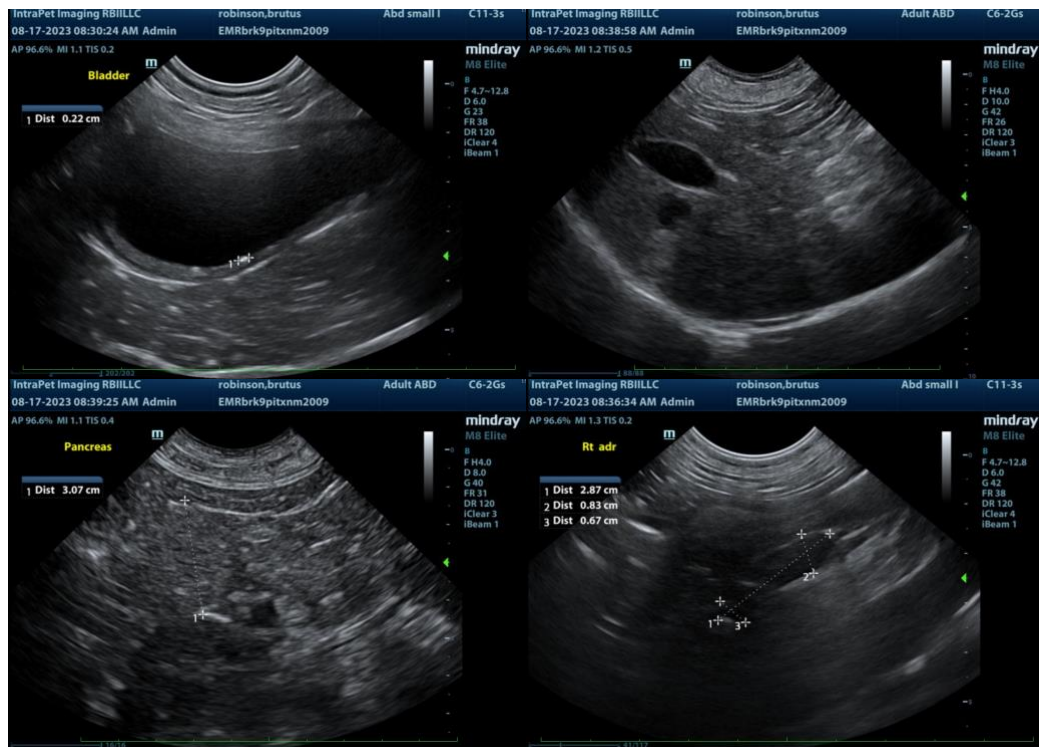
- Cystic calculi
- Bilateral chronic renal changes with nonobstructive nephrolithiasis
- The splenic parenchymal changes are most consistent with a benign process such as lymphoid hyperplasia, extramedullary hematopoiesis, splenitis or antigenic stimulation with a low possibility of infiltrative neoplasia (i.e., lymphoma, mast cell neoplasia).
- The hepatic parenchymal changes are nonspecific may be secondary to benign age-related remodeling or regenerative nodular hyperplasia. Other more insidious hepatopathies (i.e., inflammatory disease, infiltrative neoplasia) are considered less likely, particularly in light of the liver enzyme pattern. The right hepatic cyst is likely benign in nature, with a low possibility of and emerging vascular tumor.
- The pancreatic changes are most consistent with age-related parenchymal remodeling, potentially secondary to a prior inflammatory episode, early fibrosis or chronic pancreatitis.

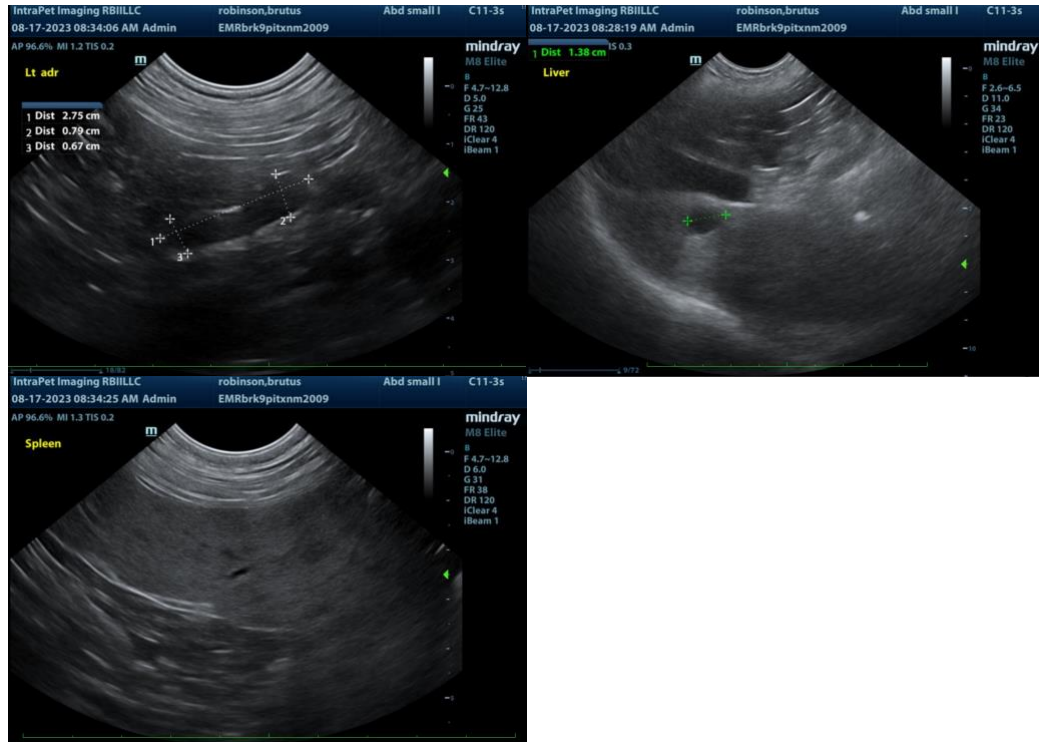
*An obvious cause for the patient's clinical signs is not definitively identified in this study. Considerations include endocrine disease, occult urinary tract infection, other.

INTERPRETATION OF THE FINDINGS & FURTHER RECOMMENDATIONS

- A urine culture and sensitivity is recommended.
- Also consider further testing for endocrinopathies (i.e., Cushing's disease, hypothyroidism).

- Given the PU/PD, Leptospirosis testing (i.e., blood and urine PCR, serology) can also be considered, particularly if the clinical suspicion for disease is high.
- Evaluation of the patient's daily caloric intake is also recommended to determine if excessive calories may be contributing to the patient's weight gain.
- Given the muscle wasting along the spine, orthopedic and neurologic evaluations are also recommended.
- Regarding the splenic changes, consider a fine-needle aspirate (if clotting status is appropriate) to further assess for round cell neoplasia.
- A cystotomy with stone removal, analysis and culture is recommended. Alternatively, medical dissolution of the stones can be considered with a prescription renal diet and broad-spectrum antibiotic therapy. If there is no improvement in stone size after 4 weeks of therapy, a cystotomy should be reconsidered. If the stone size is reduced, continue therapy until complete dissolution has been achieved.





The information and recommendations provided are based on the images presented by the referring veterinarian/sonographer. No evaluation can be communicated regarding pathology that was not visible in the image/video clips provided.

Thank you for this referral. If the clinical or image interpretation does not parallel your findings or if I can be of any further assistance, please contact me.

Andrea Nicastro, MPH, DVM, Diplomate DACVIM (Small Animal Internal Medicine)
info@SonoPath.com