



**PATIENT**

Mitch Cutro

**PRESENTING CLINICAL SIGNS**

History: Presented for vomiting vs. regurgitating. Gave 12 mls of barium PO 24 hrs ago to evaluate for possible megaesophagus.

**SPECIES**

Canine

Abnormal PE/Chem/CBC/UA Results: CBC/Chem: WNL.

**ULTRASONOGRAPHIC EXAMINATION OF THE ABDOMEN**

**BREED**

Boxer

**Urinary System**

The **urinary bladder** and visible portion of the pelvic urethra are normal for the degree of luminal distension. The urine is anechoic with no evidence of debris. Cystic calculi and discrete masses are not observed. The cystourethral junction and the visible portion of the proximal urethra are normal.

**SEX**

Neutered Male

The **prostate** is normal in size (1.27 cm in width) and shape. Parenchyma is homogenous. The prostatic urethra appears normal without evidence of dilation or obstruction.

**AGE**

11 years

The **left kidney** is normal size (6.83 cm in length); normal shape and architecture with smooth peripheral margins. There is a normal 1:3 cortex to medulla ratio with minimal to mild loss of corticomedullary distinction. The cortex is mildly hyperechoic. There is no evidence of pyelectasia, nephroliths, infarcts or hydronephrosis. Renal vasculature is normal.

**WEIGHT**

75 lbs

The **right kidney** is normal size (6.64 cm in length); normal shape and architecture with smooth peripheral margins. There is a normal 1:3 cortex to medulla ratio with minimal to mild loss of corticomedullary distinction. The cortex is mildly hyperechoic. There is no evidence of pyelectasia, nephroliths, infarcts or hydronephrosis. Renal vasculature is normal.

**INTERPRETED BY**

Andrea Nicastro,  
DVM, Diplomate  
ACVIM (*Small Animal  
Internal Medicine*)

**Adrenal Glands**

The **left adrenal gland** is normal in length (0.33 cm at cranial pole) (0.54 cm at caudal pole) (2.74 cm in length); with a flattened contour; homogenous parenchyma. The glandular echogenicity and detail are unremarkable. Capsule, cortex, and medullary definition are normal. The phrenicoabdominal vein and surrounding vasculature are normal.

**IMAGING PERFORMED BY**

Kelly Vazquez

The **right adrenal gland** is normal size (1.68 cm at cranial pole) (0.51 cm at caudal pole) (3.14 cm in length); normal shape; homogenous parenchyma. The glandular echogenicity and detail are unremarkable. Capsule, cortex, and medullary definition are normal. The phrenicoabdominal vein and surrounding vasculature are normal.

**HOSPITAL NAME**

Glen Rock VH

**Spleen**

The **spleen** is normal in size (2.38 cm in width at the level of the hilus) with a normal capsular contour. The parenchyma is mottled in appearance. No focal lesions are observed. Splenic vasculature is normal.

**REFERRING VET**

Dr. Scott Stekler

**Liver**

The **liver** is subjectively normal in size with normal contours and structure. There is appropriate echogenicity and echotexture. No overt structural evidence of inflammatory, infiltrative, or regenerative pathology is evident. Vascular and biliary tracts are of normal volume with no evidence of congestion. No pathological hepatic lymphadenopathy observed.

**INVOICE**

11429

The **gall bladder** lumen is moderately distended. The wall is thin and smooth. Luminal contents are mostly anechoic. The cystic and common bile ducts are normal/not seen.

**DATE**

8.17.22

**Gastrointestinal**

The **gastric lumen** is not distended. The gastric wall and pylorus are normal in thickness with a normal layering pattern. The pyloric outflow tract is patent. The small intestinal lumen is segmentally fluid-

distended (mild) and hypomotile. The small intestinal wall is normal in thickness with a normal layering pattern and appropriate mural detail. Discreet masses are not identified. The colonic wall is normal. There is no evidence of an obstructive pattern.

#### ***Pancreas***

The base and right limb of the **pancreas** are visible with normal curvilinear peripheral contours. The parenchyma is slightly hyperechoic relative to surrounding omental fat and slightly mottled in appearance. The pancreatic duct is visible but not overtly dilated. There is no evidence of peripancreatic inflammation or effusion.

#### ***Free Abdomen***

The **peritoneal cavity** is normal. There is no evidence of inflammation or effusion. The abdominal **lymph nodes** are normal/not visible.

### **ULTRASONOGRAPHIC FINDINGS**

#### **Primary Findings**

- Mild intestinal ileus of unknown etiology

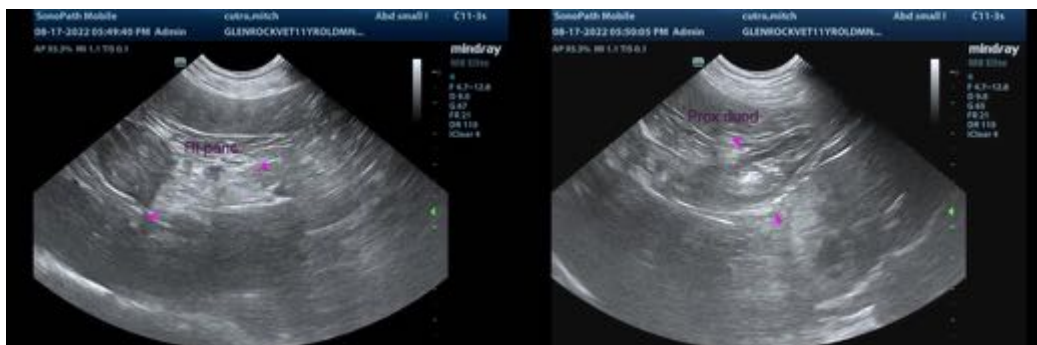
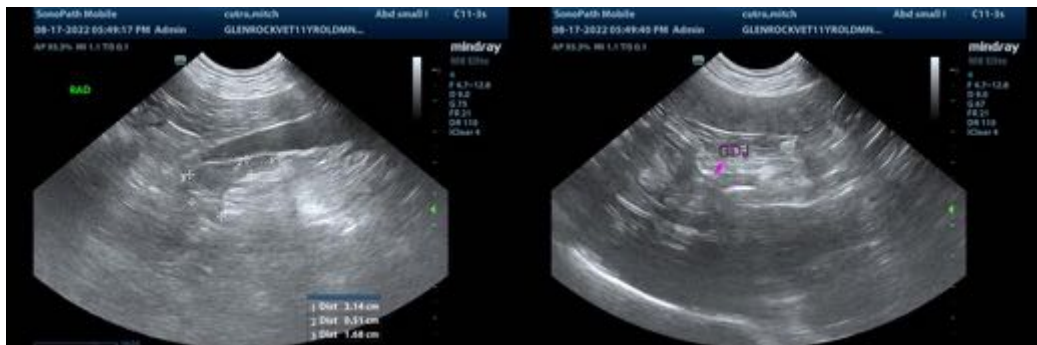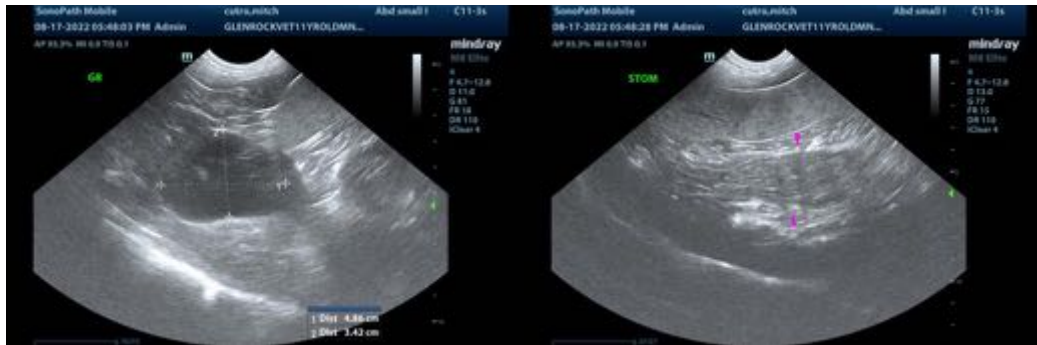
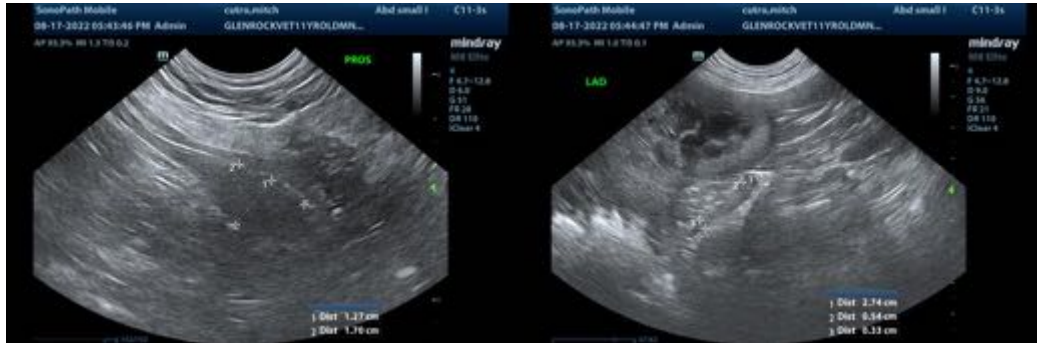#### **Secondary Findings**

- Age-related pancreatic remodeling/fibrosis. Mild, chronic pancreatitis is also possible, particularly if the patient exhibits a positive Murphy's sign.
- The splenic parenchymal changes are most consistent with a benign process such as lymphoid hyperplasia, extramedullary hematopoiesis, splenitis or antigenic stimulation with a low possibility of infiltrative neoplasia (i.e., lymphoma, mast cell neoplasia).
- The flattened left adrenal gland may be a normal variant for this patient or may be secondary to atrophy due to hypoadrenocorticism.
- Minor, age-related renal changes

### **INTERPRETATION OF THE FINDINGS & FURTHER RECOMMENDATIONS**

If regurgitation has been excluded, consider the following work-up:

1. Consider a malabsorption panel (including serum cobalamin and folate, TLI and PLI)
2. A resting cortisol level to screen for hypoadrenocorticism. If resting cortisol level is < 2.0 mcg/dL, an ACTH stimulation test is recommended.
3. A fecal evaluation for ova and Giardia is recommended.
4. A 6-week novel protein diet trial is also recommended.
5. Ultimately, endoscopic or surgical gastrointestinal biopsies may be necessary to get a definitive diagnosis.
6. Given the mild intestinal ileus, consider a promotility agent (i.e., metoclopramide). However, if no improvement is seen within 3-5 days of initiation therapy, the drug should be discontinued.



The information and recommendations provided are based on the images presented by the referring veterinarian/sonographer. No evaluation can be communicated regarding pathology that was not visible in the image/video clips provided.

Thank you for this referral. If the clinical or image interpretation does not parallel your findings or if I can be of any further assistance, please contact me.

**Andrea Nicastro**, MPH, DVM, Diplomate DACVIM (Small Animal Internal Medicine)  
[info@SonoPath.com](mailto:info@SonoPath.com)