



**PATIENT**

Molly Kaplan

**SPECIES**

Canine

**BREED**

Cockapoo

**SEX**

Female Spayed

**AGE**

14 Years

**WEIGHT**

Unknown

**INTERPRETED BY**

Andrea Nicastro, DVM,  
Diplomate ACVIM  
(Small Animal Internal  
Medicine)

**IMAGING  
PERFORMED BY**

Potomac Mobile  
Veterinary Ultrasound

**HOSPITAL NAME**

Silver Spring Animal  
Hospital

**REFERRING VET**

Dr. Jarrett

**INVOICE**

11657kk

**DATE**

8/17/21

**PRESENTING CLINICAL SIGNS**

History: Spayed at 8 mos. of age in 2007. No history of exposure to topical estrogen. July 30 brought in for swollen vulva. Per owner, had been swollen for 2 weeks. Not licking at it. No discharge. Cytology showed nucleated and anucleated cells. Antibiotics were given, no change in size. Today, vulva is very prominent, but no discharge; looks like a dog in heat. No mammary development or nodules. History of chronic kidney disease.

Abnormal PE/Chem/CBC/UA Results: Chem- BUN 62, Creat 2.5, SDMA 27, amyl 1507 blood pressure normal, U/A- USG 1.010, pH 5, a few epithelial cells; normal sediment.

**ULTRASONOGRAPHIC EXAMINATION OF THE ABDOMEN**

*Urinary System*

The urinary bladder is moderately distended with anechoic urine. The wall is normal in thickness with a smooth mucosal surface. No cystic calculi are observed. The region of the trigone and the visible portion of the proximal urethra are normal.

The left kidney is normal size (3.05 cm in length) with a normal shape, smooth peripheral margins, and normal internal architecture. There is mild loss of corticomedullary distinction. Several hyperechoic shadowing diverticular foci are observed. Mild pyelectasia is present (0.26 cm in the longitudinal plane). There is no evidence of infarcts or hydronephrosis. Renal vasculature is normal.

The right kidney is normal size (3.70 cm in length) with a normal shape, smooth peripheral margins, and normal internal architecture. There is mild loss of corticomedullary distinction. Several hyperechoic shadowing diverticular foci are observed. Mild pyelectasia is present (0.25 cm in the longitudinal plane). There is no evidence of infarcts or hydronephrosis. Renal vasculature is normal.

*Adrenal Glands*

The left adrenal gland is normal size (0.29 cm at cranial pole) (0.44 cm at caudal pole) (1.69 cm in length); normal shape; homogenous parenchyma. The glandular echogenicity and detail are unremarkable. Capsule, cortex, and medullary definition are normal. The phrenicoabdominal vein and surrounding vasculature are normal.

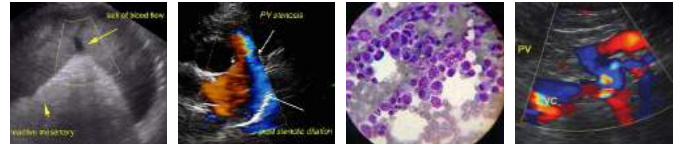
The right adrenal gland is normal size (0.28 cm at cranial pole) (0.42 cm at caudal pole) (1.40 cm in length); normal shape; homogenous parenchyma. The glandular echogenicity and detail are unremarkable. Capsule, cortex, and medullary definition are normal. The phrenicoabdominal vein and surrounding vasculature are normal.

*Spleen*

The spleen is normal in size (1.26 cm in width at the level of the hilus) with a normal capsular contour. There is appropriate echogenicity and echotexture. No focal lesions are observed. Splenic vasculature is normal.

*Liver*

The liver is subjectively normal in size with normal curvilinear peripheral contours. The parenchyma is hypoechoic relative to the spleen with minor changes consistent with age-related remodeling. No focal lesions are observed. Hepatic vasculature and biliary tracts are of normal volume with no evidence of congestion. The gall bladder lumen is moderately distended. The wall is thin and smooth. A small to moderate amount of echogenic debris is observed within the lumen, some of which is gravity-dependent and some of which is suspended. The cystic and common bile ducts are normal/not seen.



**PATIENT**

***Gastrointestinal***

Molly Kaplan

The stomach and intestine are free of stasis and exhibit normal peristaltic activity. The gastric lumen is not distended. The gastric wall and pylorus are normal in thickness with a normal layering pattern. The pyloric outflow tract is patent. The small intestinal lumen is not dilated. The small intestinal wall thickness is normal with a normal layering pattern and appropriate mural detail. Discreet masses are not identified. The colonic wall is normal. No obstructive disease is noted.

**SPECIES**

Canine

***Pancreas***

**BREED**

Cockapoo

The right limb of the pancreas is visible with normal curvilinear peripheral contours. The parenchyma is largely hyperechoic relative to surrounding omental fat and slightly mottled in appearance. The pancreatic duct is visible but not overtly dilated. There is no evidence of peripancreatic inflammation or effusion.

**SEX**

Female Spayed

***Free Abdomen***

Trace free fluid is observed. The abdominal lymph nodes are normal/not visible.

**AGE**

14 Years

***Other***

A uterine stump is visible and is thickened (up to 0.65 cm) and slightly irregular. The surrounding mesentery is hyperechoic.

**WEIGHT**

Unknown

**ULTRASONOGRAPHIC FINDINGS**

**Primary Findings:**

- Based on the clinical history and sonographic findings, a stump pyometra is suspected. Possible causes may include an unknown exposure to exogenous estrogen source, ovarian remnant, or excess adrenal sex hormone release (i.e., atypical Cushing's disease). \*\*Note – it is possible for ovarian remnant syndrome to be present despite the lag time between ovariohysterectomy and the current clinical signs. This can happen if a piece of ovarian tissue remained unattached for an extended period and then re-attaches /re-vascularizes and begins to secrete estrogen/progesterone.

**Secondary Findings:**

- The pancreatic changes are most consistent with age-related parenchymal remodeling, potentially secondary to a prior inflammatory episode, early fibrosis or chronic pancreatitis.
- The hepatic changes are consistent with age-related parenchymal remodeling and are not considered clinically significant at this time.
- Bilateral, age-related pathology with dystrophic mineralization and pyelectasia.

**INTERPRETATION OF THE FINDINGS & FURTHER RECOMMENDATIONS**

- Regarding the uterine stump, consider the following:
  - Anti-mullerian hormone assay
  - Adrenal panel (sent to the university of Tennessee; perform like an ACTH stimulation test).
  - Surgical removal of the uterine stump with a search for an ovarian remnant.

**INTERPRETED BY**

Andrea Nicastro, DVM,  
Diplomate ACVIM  
(*Small Animal Internal  
Medicine*)

**IMAGING  
PERFORMED BY**

Potomac Mobile  
Veterinary Ultrasound

**HOSPITAL NAME**

Silver Spring Animal  
Hospital

**REFERRING VET**

Dr. Jarrett

**INVOICE**

11657kk

**DATE**

8/17/21



## PATIENT

Molly Kaplan

- Regarding the renal changes and azotemia, a urine culture and sensitivity +/- UPC (if proteinuria is present without evidence of a UTI) are recommended.

## SPECIES

Canine

## BREED

Cockapoo

## SEX

Female Spayed

## AGE

14 Years

## WEIGHT

Unknown

## INTERPRETED BY

Andrea Nicastro, DVM,  
Diplomate ACVIM  
(Small Animal Internal  
Medicine)

## IMAGING PERFORMED BY

Potomac Mobile  
Veterinary Ultrasound

## HOSPITAL NAME

Silver Spring Animal  
Hospital

## REFERRING VET

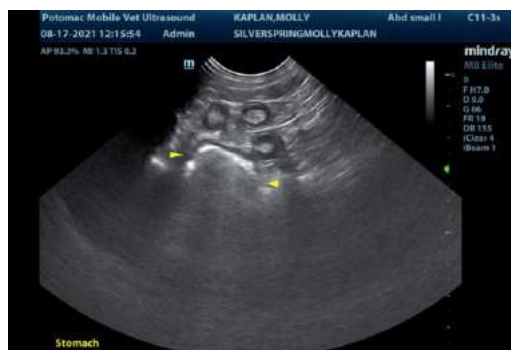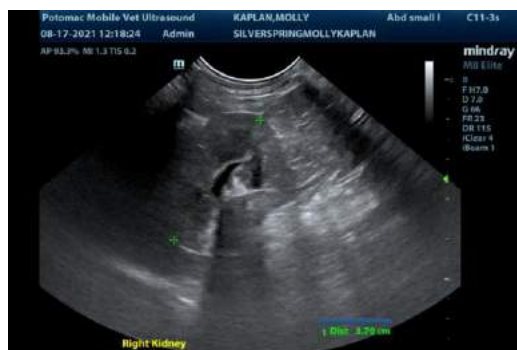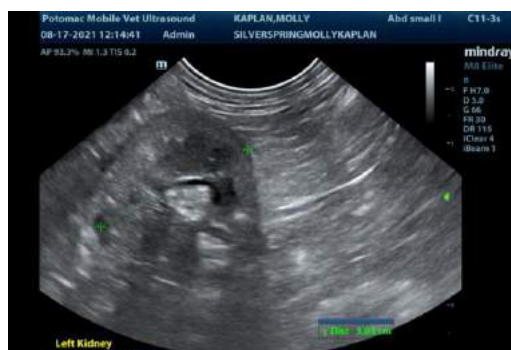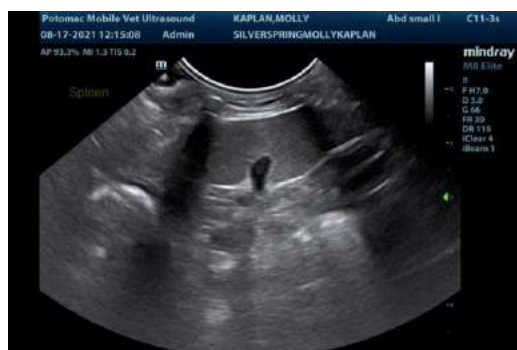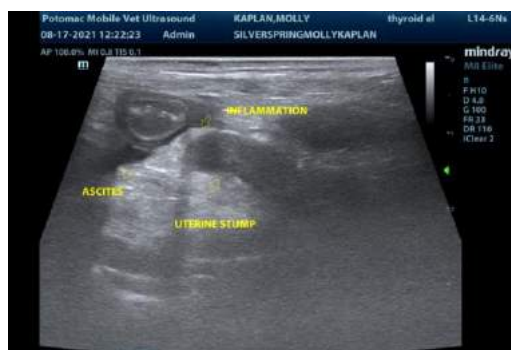
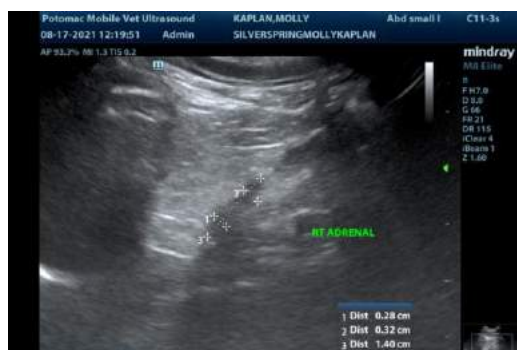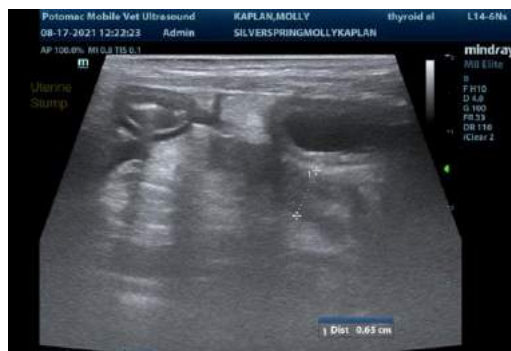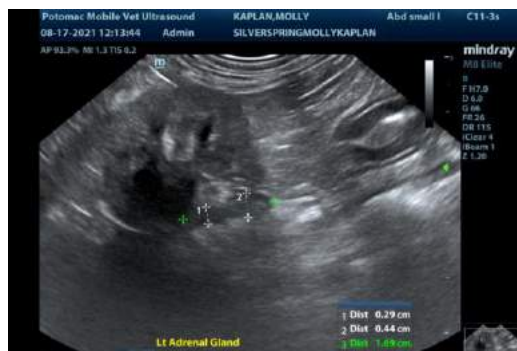Dr. Jarrett

## INVOICE

11657kk

## DATE

8/17/21





## PATIENT

Molly Kaplan

## SPECIES

Canine

## BREED

Cockapoo

## SEX

Female Spayed

## AGE

14 Years

## WEIGHT

Unknown

## INTERPRETED BY

Andrea Nicastro, DVM,  
Diplomate ACVIM  
(*Small Animal Internal  
Medicine*)

## IMAGING PERFORMED BY

Potomac Mobile  
Veterinary Ultrasound

## HOSPITAL NAME

Silver Spring Animal  
Hospital

## REFERRING VET

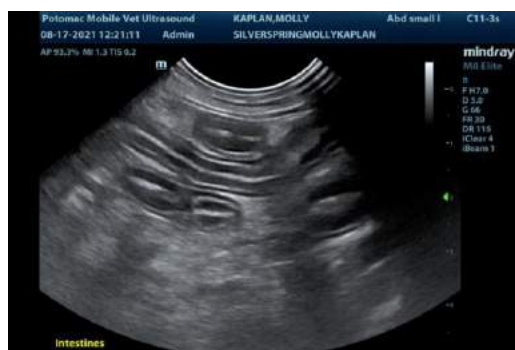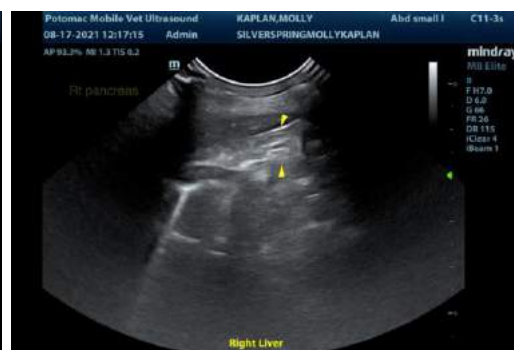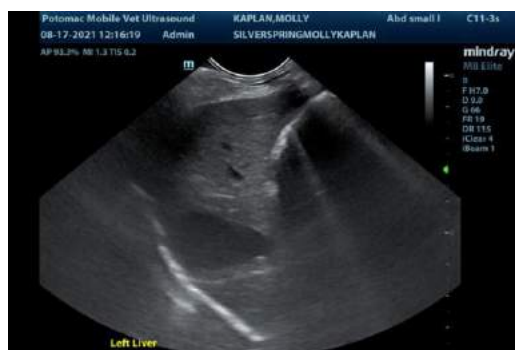Dr. Jarrett

## INVOICE

11657kk

## DATE

8/17/21



The information and recommendations provided are based on the images presented by the referring veterinarian. No evaluation can be communicated regarding pathology that was not visible in the image/video clips provided.

Thank you for this referral. If the clinical or image interpretation does not parallel your findings or if I can be of any further assistance, please contact me.

Andrea Nicastro, DVM, Diplomate ACVIM (*Small Animal Internal Medicine*)  
Andrea.nicastro@sonopath.com