

**DATE PRESENTING CLINICAL SIGNS**

8/17/21 History: Wellness lab results showed some possible concerning abnormalities suggestive of dramatic immune response, multiple myeloma, liver / gall bladder / pancreas problem.

PATIENT

Holly Vezos Current Medications: Gabapentin 100mg 2 pills the evening before and the morning of the blood draw. Diphenhydramine 25mg 2 pills 1 hour before vaccines.

SPECIES

Canine

Lab Results: fecal neg, USG 1.012, protein 1+, pH 5, micro neg, In house serology lyme positive, platelet 607, hct 39, wbc 8.46, BUN 37.8, creat 1.0, TProt >11.0, Alb 3.6, glob 9.5, ALT 195 (4-75), ALK 852, GGT <5, T Bili 1.55, chol 365 (100-330), amy 1567 (500-1400).

BREED

Pug Mix

Date of Previous IntraPet Ultrasound: No previous.

SEX

Female Spayed

Sedation: Not needed.
Stat Report: Not requested.

ULTRASONOGRAPHIC EXAMINATION OF THE ABDOMEN**AGE**

2010

Urinary System

The urinary bladder, trigone, and pelvic urethra are normal in thickness and the mucosal surface is smooth. The bladder lumen is moderately distended with anechoic urine. No masses, inflammatory changes or calculi are observed. Ureteral papillae and visualized portion of the proximal urethra, visible to a depth of 2 cm, are normal.

WEIGHT

37.30 lbs.

The left kidney is normal size (5.41 cm in length); normal shape and architecture with smooth peripheral margins. There is a normal 1:3 cortex to medulla ratio with minimal to mild loss of corticomedullary distinction. There is no evidence of pyelectasia, nephroliths, infarcts or hydroureter. Renal vasculature is normal.

INTERPRETED BY

Andrea Nicastro, DVM,
Diplomate ACVIM
(Small Animal Internal
Medicine)

The right kidney is normal size (4.95 cm in length); normal shape and architecture with smooth peripheral margins. There is a normal 1:3 cortex to medulla ratio with minimal to mild loss of corticomedullary distinction. There is no evidence of pyelectasia, nephroliths, infarcts or hydroureter. Renal vasculature is normal.

HOSPITAL NAME

Friendly Paws
Veterinary Clinic

Adrenal Glands

The left adrenal gland is normal size (0.45 cm at cranial pole) (0.58 cm at caudal pole) (1.68 cm in length); normal shape; homogenous parenchyma. The glandular echogenicity and detail are unremarkable. Capsule, cortex, and medullary definition are normal. The phrenicoabdominal vein and surrounding vasculature are normal.

REFERRING VET

Dr. Price

The right adrenal gland is normal size (0.77 cm at cranial pole) (0.56 cm at caudal pole) (1.96 cm in length); normal shape; homogenous parenchyma. The glandular echogenicity and detail are unremarkable. Capsule, cortex, and medullary definition are normal. The phrenicoabdominal vein and surrounding vasculature are normal.

INVOICE

11655kk

Spleen

The spleen is normal in size (1.07 cm in width at the level of the hilus) with a normal capsular contour. There is appropriate echogenicity and echotexture. No focal lesions are observed. Splenic vasculature is normal.

Liver

The liver is subjectively prominent in size with slightly swollen peripheral contours. The parenchyma is hypoechoic relative to the spleen and severely heterogeneous, bordering on a “moth eaten” appearance. There is a suspected, hyperechoic/heterogeneous mass-effect (6.29 cm) deep in the left to mid-liver. Hepatic vasculature and intrahepatic biliary tracts are of normal volume with no evidence of congestion. The gall bladder lumen is moderately distended. The wall is thin and smooth. A small amount of aggregated, echogenic debris is observed within the lumen. The cystic and common bile ducts are normal/not seen.

Gastrointestinal

The stomach and intestine are free of stasis and exhibit normal peristaltic activity. The gastric lumen is not distended. The gastric wall and pylorus are normal in thickness with a normal layering pattern. The pyloric outflow tract is patent. The small intestinal lumen is not dilated. The small intestinal wall thickness is normal with a normal layering pattern and appropriate mural detail. Discreet masses are not identified. The colonic wall is normal. No obstructive disease is noted.

Pancreas

The pancreas is diffusely prominent in size with slightly irregular peripheral contours. The parenchyma is isoechoic relative to surrounding omental fat and mottled in appearance. No distinct focal lesions are observed. The pancreatic duct is not overtly dilated. There is no evidence of peripancreatic effusion.

Free Abdomen

The peritoneal cavity is normal. There is no evidence of inflammation or effusion. The abdominal lymph nodes are normal/not visible.

ULTRASONOGRAPHIC FINDINGS

Primary Findings:

- The hepatic parenchymal changes, including the mass-effect, are concerning for infiltrative neoplasia (i.e., round cell tumor) especially given the severe hyperglobulinemia. Benign pathology (i.e., diffuse inflammatory disease) is also possible but considered less likely.
- Gall bladder debris - incidental.

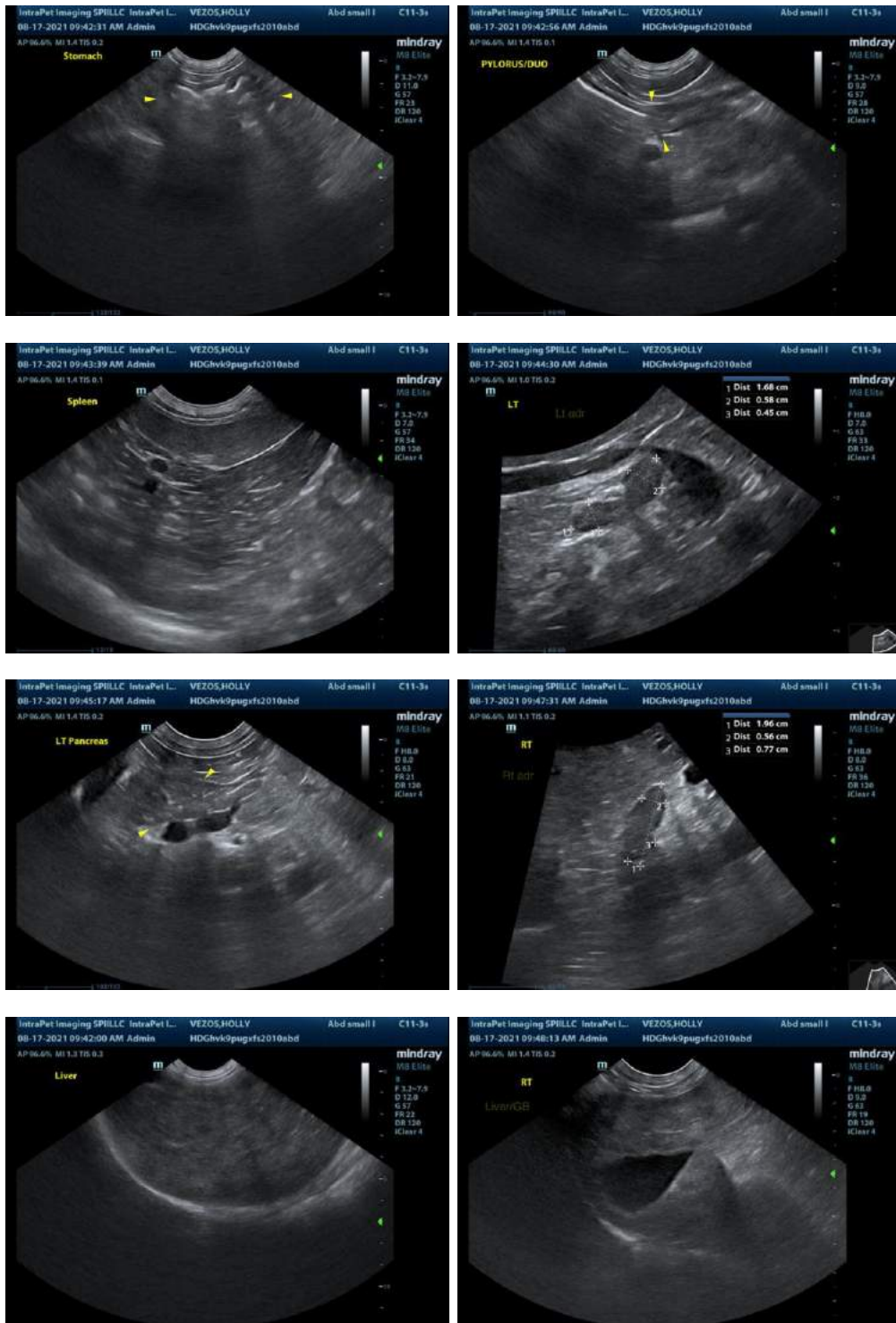
Secondary Findings:

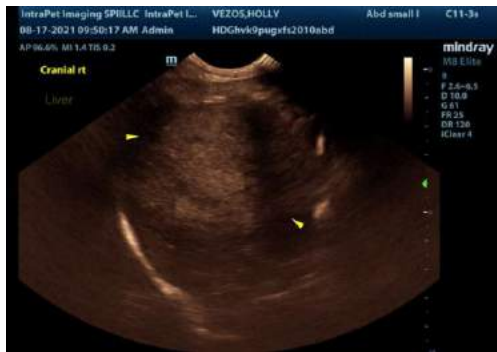- The pancreatic changes are most consistent with age-related parenchymal remodeling, potentially secondary to a prior inflammatory episode, early fibrosis or chronic pancreatitis.
- Age-related renal pathology.

INTERPRETATION OF THE FINDINGS & FURTHER RECOMMENDATIONS

1. Three-view thoracic radiographs are recommended to assess for pulmonary metastases.
2. Fine needle aspirates of the liver are recommended (if clotting status is appropriate). 25-gauge needles should be used. If cytologic evaluations are inconclusive, consider the following:
 - a. Serum protein electrophoresis
 - b. Surgical liver biopsy

- c. +/- bone marrow aspirate to assess for multiple myeloma at the marrow level.
- d. Given the presence of proteinuria, a UPC should also be considered.





The information and recommendations provided are based on the images presented by the referring veterinarian. No evaluation can be communicated regarding pathology that was not visible in the image/video clips provided.

Thank you for this referral. If the clinical or image interpretation does not parallel your findings or if I can be of any further assistance, please contact me.

Andrea Nicastro, DVM, Diplomate ACVIM (*Small Animal Internal Medicine*)
Andrea.nicastro@sonopath.com