

**DATE PRESENTING CLINICAL SIGNS**

8/17/21

History: 7/28/2021 exam, weight loss, decreased appetite.

Lab Results: Liver enzymes elevated. ALKP 1105, albumin 1.5, T-bili 0.5, CBC, T4, 4DX norma/negative, Lepto test negative.

PATIENT

Bella Boggs

Date of Previous IntraPet Ultrasound: No previous

Sedation: Not needed.

Stat Report: Not requested.

SPECIES

Canine

ULTRASONOGRAPHIC EXAMINATION OF THE ABDOMEN**Urinary System**

The urinary bladder is pelvicly positioned. The lumen is mildly dilated. The wall is of appropriate thickness for the level of repletion. A moderate amount of suspended echogenic debris is observed within the lumen. A small amount of gravity-dependent mineralized sand is present. No cystic calculi are observed. The region of the trigone is normal.

BREED

Labrador Mix

SEX

Female, spayed

The left kidney is normal size (5.85 cm in length); normal shape and architecture with smooth peripheral margins. There is a normal 1:3 cortex to medulla ratio with normal corticomedullary distinction. There is no evidence of pyelectasia, nephroliths, infarcts or hydroureter. Renal vasculature is normal.

AGE

2014

The right kidney is normal size (6.00 cm in length); normal shape and architecture with smooth peripheral margins. There is a normal 1:3 cortex to medulla ratio with normal corticomedullary distinction. There is no evidence of pyelectasia, nephroliths, infarcts or hydroureter. Renal vasculature is normal.

WEIGHT

32.4 lbs.

Adrenal Glands

The left adrenal gland is normal size (0.57 cm at cranial pole) (0.57 cm at caudal pole) (2.20 cm in length); normal shape; homogenous parenchyma. The glandular echogenicity and detail are unremarkable. Capsule, cortex, and medullary definition are normal. The phrenicoabdominal vein and surrounding vasculature are normal.

INTERPRETED BY

Andrea Nicastro, DVM,
 Diplomate ACVIM
 (Small Animal Internal
 Medicine)

The right adrenal gland is normal in length (0.46 cm at cranial pole) (0.38 cm at caudal pole) (2.02 cm in length) with a flattened contour. The glandular echogenicity and detail are unremarkable. Capsule, cortex, and medullary definition are normal. The phrenicoabdominal vein and surrounding vasculature are normal.

HOSPITAL NAME

Pet Wellness Center

Spleen

The spleen is normal in size (1.54 cm in width at the level of the hilus) with a normal capsular contour. There is appropriate echogenicity and echotexture. No focal lesions are observed. Splenic vasculature is normal.

REFERRING VET

Dr. Twardus

Liver

The liver is subjectively enlarged with swollen peripheral contours. The parenchyma is hyperechoic relative to the spleen and subtly mottled in appearance. No distinct focal lesions are observed. Vascular and biliary tracts are of normal volume with no evidence of congestion. The gall bladder lumen is moderately distended. The wall is thin and smooth. Luminal contents are anechoic. The cystic and common bile ducts are normal/not seen.

INVOICE

11896

Gastrointestinal

The gastric lumen is mildly distended with ingesta. The gastric wall is normal in thickness with a normal layering pattern. The small intestinal lumen is segmentally dilated with chyme. The small intestinal wall thickness is normal with a normal layering pattern and appropriate mural detail. Discreet masses are not identified. The colonic wall is normal. The colonic lumen contains shadowing fecal material. No obstructive disease is noted.

Pancreas

The region of the pancreas is isoechoic relative to surrounding omental fat. No obvious parenchymal abnormalities are observed. There is no evidence of regional inflammation or effusion.

Free Abdomen

Trace free fluid is observed. Several prominent mesenteric lymph nodes are visualized, the largest measuring 3.74 cm. A large vessel is coursing through the cluster of mesenteric lymph nodes.

ULTRASONOGRAPHIC FINDINGS

Primary Findings:

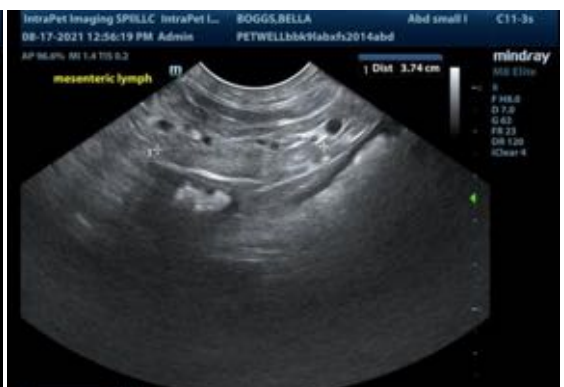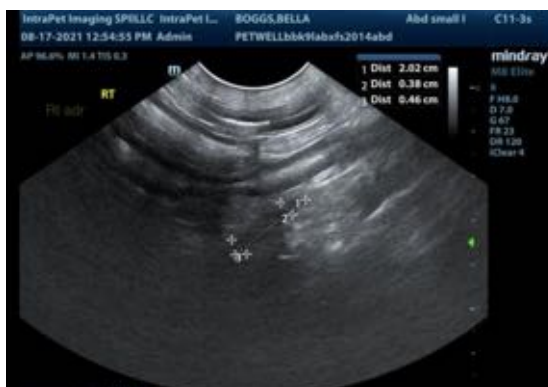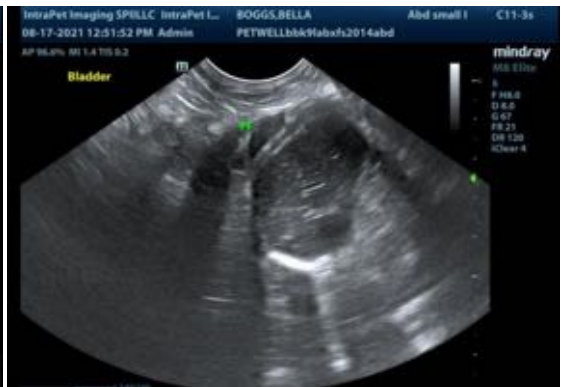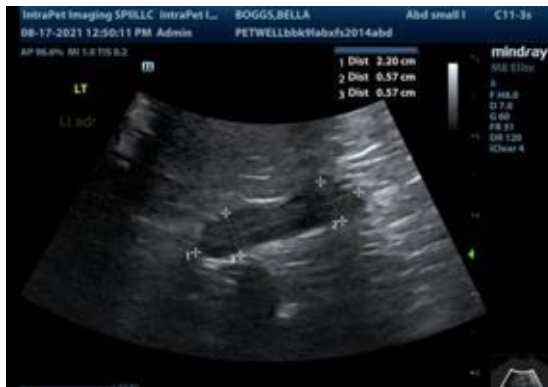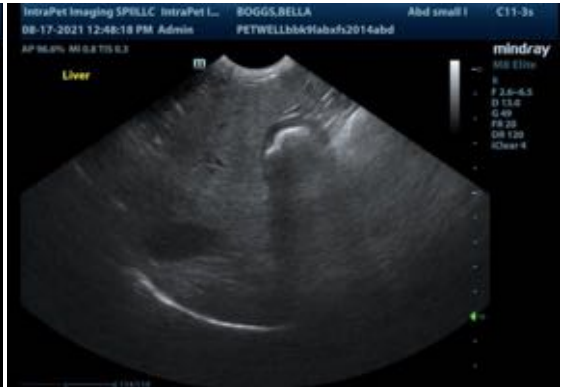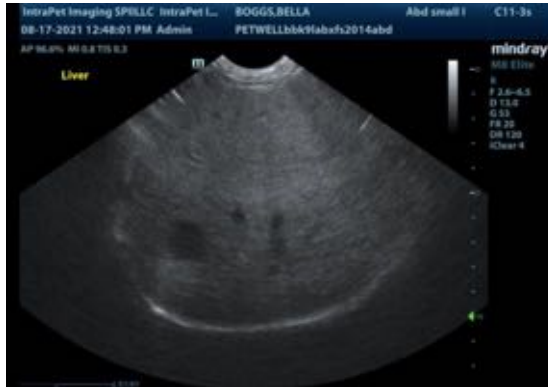- The hepatic parenchymal changes could be consistent with infiltrative neoplasia (i.e., lymphoma), vacuolar hepatopathy, regenerative nodular hyperplasia or other hepatopathy.
- The prominent abdominal lymph nodes are most consistent with reactive lymphadenitis or lymphoid hyperplasia. Neoplastic infiltration is considered less likely.
- The trace ascites may be secondary to low oncotic pressure, portal hypertension (i.e., secondary to hepatic disease), other.

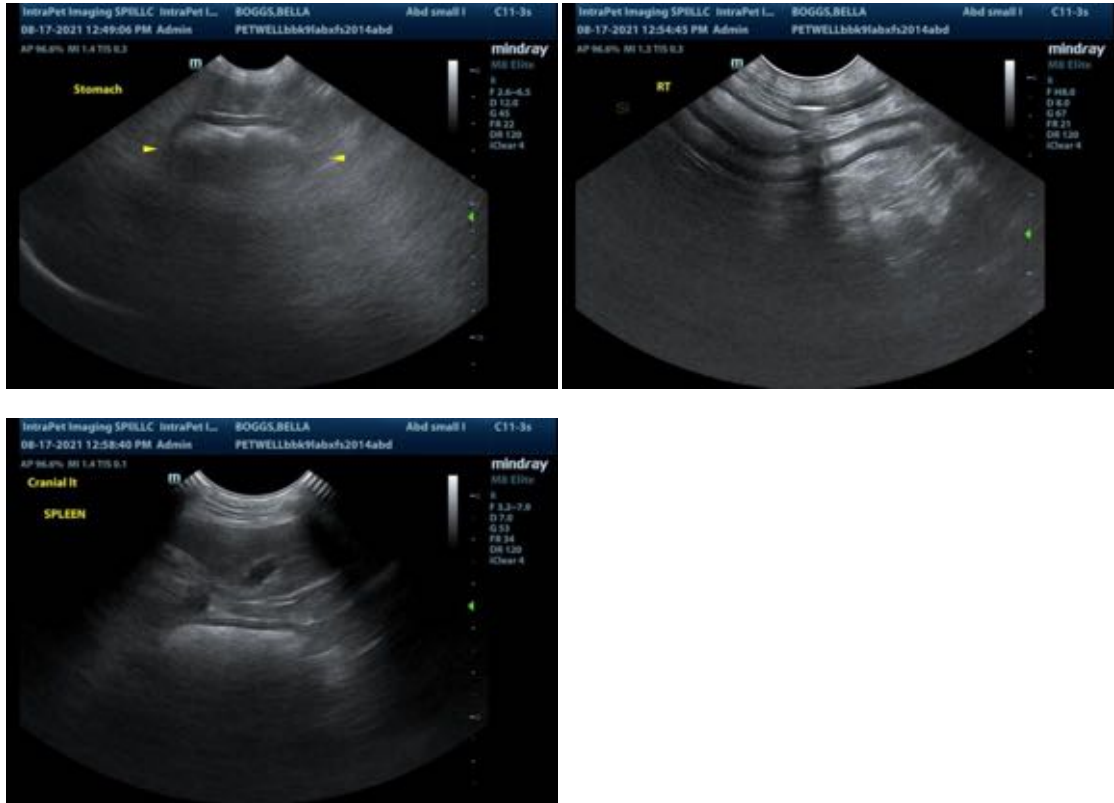
Secondary Findings:

- The urinary bladder debris may represent cells, crystals and/or exfoliated material.
- The flattened right adrenal gland may be a normal variant for this patient or may be secondary to atrophy (i.e., due to hypoadrenocorticism).

INTERPRETATION OF THE FINDINGS & FURTHER RECOMMENDATIONS

- Three-view thoracic radiographs are recommended to assess for occult disease in the chest.
- A fine needle aspirate of the liver can be considered (if clotting status is appropriate). A 25-gauge needle should be used. Also consider pre- and post-prandial serum bile acids. Depending on the results of the above diagnostics, a surgical liver biopsy with aerobic and anaerobic bile cultures and acquisition of additional hepatic tissue samples for potential copper quantitation may be warranted.
- Also consider a malabsorption panel to assess for concurrent gastrointestinal and pancreatic disease.





The information and recommendations provided are based on the images presented by the referring veterinarian. No evaluation can be communicated regarding pathology that was not visible in the image/video clips provided.

Thank you for this referral. If the clinical or image interpretation does not parallel your findings or if I can be of any further assistance please contact me.

Andrea Nicastro, DVM, Diplomate ACVIM (*Small Animal Internal Medicine*)
Andrea.nicastro@sonopath.com