



PATIENT PRESENTING CLINICAL SIGNS

Shadow Boyer

History: Dark brown diarrhea on and off since ~ 7/10, no evidence of melena. Minimal response to metronidazole, I/D. Waxing and waning inappetence.

SPECIES

Canine

Abnormal PE/Chem/CBC/UA Results: EENT: Light pink mm, tacky Thorax: Grade I-II/VI left systolic heart murmur; lungs clear and eupneic Lymph Nodes: WNL Abdomen: Soft, non-painful, doughy with possible nodules (vs. thickened intestines) Rectal: AG soft and non-painful; scant tan liquidy diarrhea on exam glove AFAST @11pm 8/15 revealed scant to mild free fluid; concern for possible caudal abdominal mass Blood work revealed anemia (PCV 20%). GLU- 147 (74-143), SDMA- 15 (0-14)CREA- 0.4 (0.5-1.8), CA- 7.8 (7.9-12.0)

BREED

Miniature Pinscher

ULTRASONOGRAPHIC EXAMINATION OF THE ABDOMEN

SEX

Male, neutered

Urinary System

In the visualized portions of the urinary bladder, the lumen is distended. The wall is normal in thickness with a smooth mucosal surface. A small amount of suspended echogenic debris is observed. No cystic calculi are seen. The cystourethral junction is normal. The proximal/prostatic urethra is moderately dilated without obvious evidence of obstruction.

AGE

6 Yrs.

The prostate is normal in size (0.60 cm in width) and shape. Parenchyma is homogenous. The prostatic urethra appears normal without evidence of dilation or obstruction.

WEIGHT

4 kg.

The left kidney is normal size (4.05 cm in length); normal shape and architecture with smooth peripheral margins. There is a normal 1:3 cortex to medulla ratio with normal corticomedullary distinction. There is no evidence of pyelectasia, nephroliths, infarcts or hydroureter.

INTERPRETED BY

Andrea Nicastro, DVM,
Diplomate ACVIM
(Small Animal Internal
Medicine)

The right kidney is normal size (4.25 cm in length); normal shape and architecture with smooth peripheral margins. There is a normal 1:3 cortex to medulla ratio with normal corticomedullary distinction. There is no evidence of pyelectasia, nephroliths, infarcts or hydroureter.

IMAGING PERFORMED BY

Tom McNeill

Adrenal Glands

The left adrenal gland is borderline enlarged (0.49 cm at cranial pole) (0.57 cm at caudal pole); normal shape; homogenous parenchyma. The glandular echogenicity and detail are unremarkable. Capsule, cortex, and medullary definition are normal. The phrenicoabdominal vein and surrounding vasculature are normal.

HOSPITAL NAME

SVS Imaging CT

The right adrenal gland is normal size (0.69 cm at cranial pole) (0.56 cm at caudal pole); normal shape; homogenous parenchyma. The glandular echogenicity and detail are unremarkable. Capsule, cortex, and medullary definition are normal. The phrenicoabdominal vein and surrounding vasculature are normal.

REFERRING VET

Dr. Graham

Spleen

The spleen is normal in size (xxx cm in width at the level of the hilus) with a normal capsular contour. There is appropriate echogenicity and echotexture. No focal lesions are observed. Splenic vasculature is normal.

INVOICE

13826

Liver

The liver is subjectively normal in size with normal contours and structure. There is appropriate echogenicity and echotexture. No overt structural evidence of inflammatory, infiltrative or regenerative pathology is evident. Vascular and biliary tracts are of normal volume with no evidence of

DATE

8/16/22



PATIENT

Shadow Boyer

congestion. No pathological hepatic lymphadenopathy observed. The gall bladder lumen is moderately distended. The wall is thin and smooth. Luminal contents are mostly anechoic. Surrounding mesentery is hyperechoic. The cystic and common bile ducts are normal/not seen.

SPECIES

Canine

Gastrointestinal

The gastric lumen is gas distended. The gastric wall and pylorus are normal in thickness with a normal layering pattern. The pyloric outflow tract appears patent. The small intestinal lumen is not dilated. An approximately 3.8 cm hypoechoic jejunal mass is visualized. The wall in this region is severely thickened (up to 2.27 cm) and there is complete loss of the normal layering pattern in this region. In the adjacent segments, there is disruption in the normal 1:3 muscularis: mucosal ratio. The remaining small intestinal segments are normal in thickness with a normal layering pattern. The colonic wall is normal. The colonic lumen contains liquid appearing fecal material. No obstructive disease is noted.

BREED

Miniature Pinscher

SEX

Male, neutered

Pancreas

The pancreas is normal in size with normal peripheral contours. The pancreatic duct is normal. The base and limbs of the pancreas are isoechoic to surrounding omental fat. No focal lesions are observed. There is no evidence of peripancreatic inflammation or effusion.

AGE

6 Yrs.

Lymph nodes

In the region of the mesenteric root, there is a mass effect which appears to incorporate the mesenteric nodes. The nodes appear to be rounded and hypoechoic to anechoic in appearance. Surrounding mesentery is hyperechoic.

WEIGHT

4 kg.

Free Abdomen

A moderate amount of echogenic free fluid is present. The mesentery throughout the abdomen is hyperechoic. A few ill-defined hypoechoic areas/nodules are observed within the mesentery in the cranial to mid-abdomen.

INTERPRETED BY

Andrea Nicastro, DVM,
Diplomate ACVIM
(Small Animal Internal
Medicine)

Other

There are questionable thrombi observed in the mesenteric vessels.

IMAGING PERFORMED BY

Tom McNeill

ULTRASONOGRAPHIC FINDINGS

HOSPITAL NAME

SVS Imaging CT

Primary Findings:

- Large jejunal mass. Neoplasia (i.e., adenocarcinoma, lymphoma) is considered likely with a lower possibility of a benign process (i.e., severe focal inflammatory process).
- The mass effect at the mesenteric root is thought to represent a cluster of enlarged lymph nodes, which may be neoplastic or may represent reactive change.
- Diffuse peritonitis is present, likely secondary to bowel and/or lymph node pathology.

REFERRING VET

Dr. Graham

Secondary Findings:

- Non-specific hepatic parenchymal changes could be consistent with inflammatory disease, hepatotoxicosis (i.e., copper), infiltrative neoplasia, age-related remodeling, other.

INVOICE

13826

DATE

8/16/22



PATIENT

Shadow Boyer

- The pancreatic changes are suggestive of mild acute or chronic active pancreatitis.
- The ill-defined hypoechoic nodules/areas within the mesentery may represent metastatic or inflammatory lesions, other

SPECIES

Canine

- Questionable clots within the mesenteric vessels.

BREED

Miniature Pinscher

INTERPRETATION OF THE FINDINGS & FURTHER RECOMMENDATIONS

SEX

Male, neutered

- Three-view thoracic radiographs are recommended to assess for pulmonary metastases.
- A fine needle aspirate of the jejunal mass is recommended (if clotting status is appropriate). If cytology results are inconclusive, an abdominal exploratory with jejunal mass removal or biopsy may be necessary to get a definitive diagnosis. If surgery is pursued, biopsies of the abdominal lymph nodes and any other pathology should also be obtained.

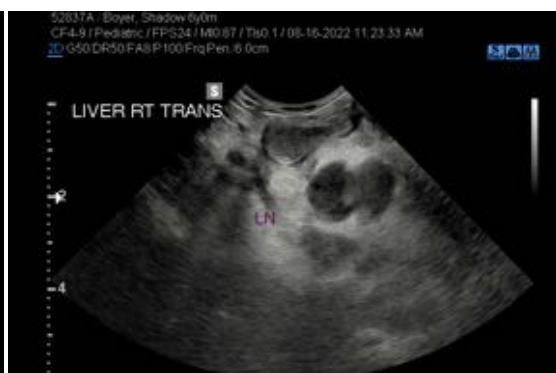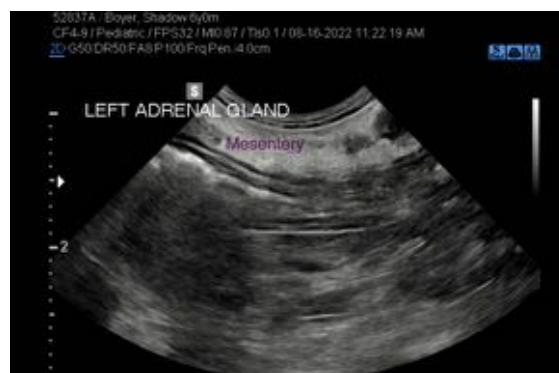AGE

6 Yrs.

- Also consider a malabsorption panel including serum cobalamin, folate, TLI and PLI.

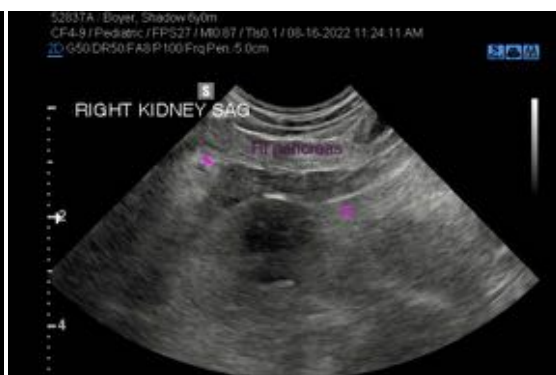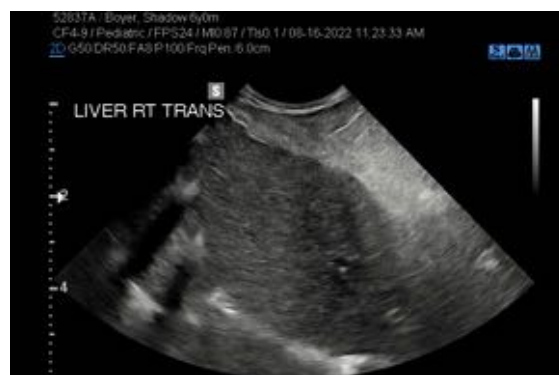WEIGHT

4 kg.



INTERPRETED BY

Andrea Nicastro, DVM,
Diplomate ACVIM
(Small Animal Internal
Medicine)



IMAGING PERFORMED BY

Tom McNeill

HOSPITAL NAME

SVS Imaging CT

REFERRING VET

Dr. Graham

INVOICE

13826

DATE

8/16/22



PATIENT

Shadow Boyer

SPECIES

Canine

BREED

Miniature Pinscher

SEX

Male, neutered

AGE

6 Yrs.

WEIGHT

4 kg.

INTERPRETED BY

Andrea Nicastro, DVM,
Diplomate ACVIM
(Small Animal Internal
Medicine)

**IMAGING
PERFORMED BY**

Tom McNeill

HOSPITAL NAME

SVS Imaging CT

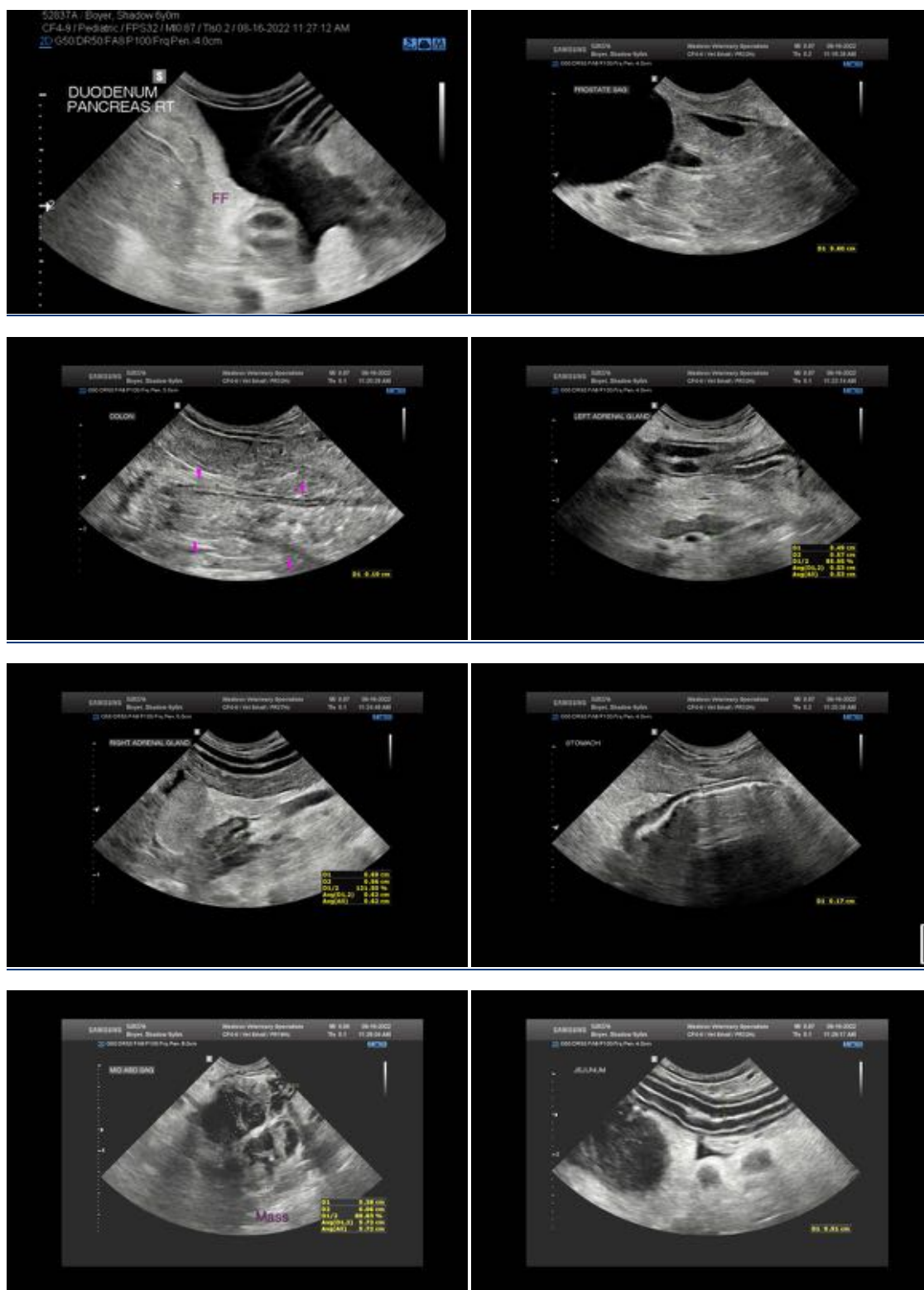
REFERRING VET

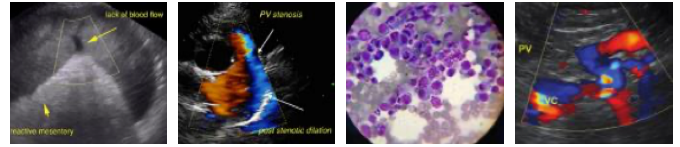
Dr. Graham

INVOICE

13826

DATE
8/16/22





PATIENT

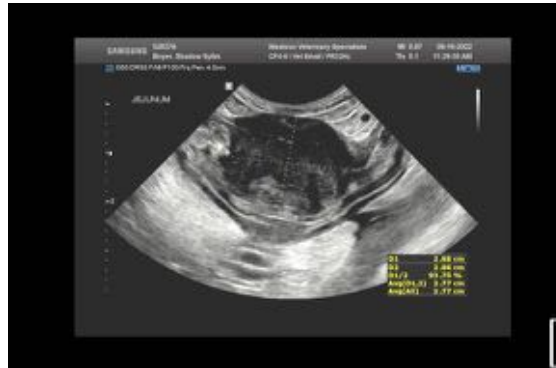Shadow Boyer

SPECIES

Canine

BREED

Miniature Pinscher



SEX

Male, neutered

AGE

6 Yrs.

WEIGHT

4 kg.

INTERPRETED BY

Andrea Nicastro, DVM,
Diplomate ACVIM
(*Small Animal Internal
Medicine*)

**IMAGING
PERFORMED BY**

Tom McNeill

HOSPITAL NAME

SVS Imaging CT

REFERRING VET

Dr. Graham

INVOICE

13826

DATE

8/16/22

The information and recommendations provided are based on the images presented by the referring veterinarian/sonographer. No evaluation can be communicated regarding pathology that was not visible in the image/video clips provided.

Thank you for this referral. If the clinical or image interpretation does not parallel your findings or if I can be of any further assistance please contact me.

Andrea Nicastro, MPH, DVM, Diplomate DACVIM (Small Animal Internal Medicine)
info@SonoPath.com