

**DATE PRESENTING CLINICAL SIGNS**

8/16/21

History: Pet has chronic cough/ throat clearing. Treated first for respiratory issues with minimal to no improvement. Had mild improvement on Pepcid, but still happening. Owner concerned. Chest films in July showed very mild narrowing of trachea and very mild bronchiolar pattern.

**PATIENT**

Yohan Reinecke

Current Medications: Body sore and Double P Chinese herbals prn for lower back pain/disk narrowing. Methocarbamol/Carprofen/Gabapentin prn for back flairs.

Lab Results: Labs not updated since MCT removal in April. Alkp 235 at that time.

**SPECIES**

Canine

Radiographs: possible narrowing of trachea.

Date of Previous IntraPet Ultrasound: No previous IntraPet scans.

Sedation: Not needed.

Stat Report: Not requested.

**BREED**

Brussels Griffon

**ULTRASONOGRAPHIC EXAMINATION OF THE ABDOMEN****Urinary System****SEX**

Male, neutered

The urinary bladder, trigone, and pelvic urethra are normal in thickness and the mucosal surface is smooth. The bladder lumen is moderately distended with anechoic urine. No masses, inflammatory changes or calculi are observed. Ureteral papillae and visualized portion of the proximal urethra, visible to a depth of 2 cm, are normal.

**AGE**

10/8/2009

The prostate is normal in size (0.88 cm in width) and shape. Parenchyma is homogenous. The prostatic urethra appears normal without evidence of dilation or obstruction.

**WEIGHT**

19 lbs.

The left kidney is normal size (4.01 cm in length); normal shape and architecture with smooth peripheral margins. There is a normal 1:3 cortex to medulla ratio with minimal to mild loss of corticomedullary distinction. There is no evidence of pyelectasia, nephroliths, infarcts or hydroureter. Renal vasculature is normal.

**INTERPRETED BY**

Andrea Nicastro, DVM,  
 Diplomate ACVIM  
 (Small Animal Internal  
 Medicine)

The right kidney is normal size (4.21 cm in length); normal shape and architecture with smooth peripheral margins. There is a normal 1:3 cortex to medulla ratio with minimal loss of corticomedullary distinction. There is no evidence of pyelectasia, nephroliths, infarcts or hydroureter. Renal vasculature is normal.

**Adrenal Glands****HOSPITAL NAME**

Everhart WellPet

The left adrenal gland is normal size (0.41 cm at cranial pole) (0.55 cm at caudal pole) (2.69 cm in length); normal shape; homogenous parenchyma. The glandular echogenicity and detail are unremarkable. Capsule, cortex, and medullary definition are normal. The phrenicoabdominal vein and surrounding vasculature are normal.

**REFERRING VET**

Dr. Key

The right adrenal gland is normal size (0.60 cm at cranial pole) (0.49 cm at caudal pole) (1.43 cm in length); normal shape; homogenous parenchyma. The glandular echogenicity and detail are unremarkable. Capsule, cortex, and medullary definition are normal. The phrenicoabdominal vein and surrounding vasculature are normal.

**INVOICE**

11885

**Spleen**

The spleen is normal in size (0.89 cm in width at the level of the hilus) with a normal capsular contour. There is appropriate echogenicity and echotexture. A 0.83 x 0.75 cm irregular hypoechoic to slightly heterogeneous nodule is observed at the medial aspect near the hilus. Splenic vasculature is normal.

**Liver**

The liver is subjectively normal in size with normal curvilinear peripheral contours. The parenchyma is hypoechoic relative to the spleen and slightly heterogeneous in appearance. No distinct focal lesions are

observed. Vascular and biliary tracts are of normal volume with no evidence of congestion. No pathological hepatic lymphadenopathy observed. A small to moderate amount of aggregated echogenic gravity-dependent debris/sludge is observed within the lumen. The wall is normal in thickness. No choleliths are observed. The cystic and common bile ducts are normal.

### ***Gastrointestinal***

The stomach and intestine are free of stasis and exhibit normal peristaltic activity. The gastric lumen is not distended. The gastric wall and pylorus are normal in thickness with a normal layering pattern. The pyloric outflow tract is patent. The small intestinal lumen is not dilated. The small intestinal wall thickness is normal with a normal layering pattern and appropriate mural detail. Discreet masses are not identified. The colonic wall is normal. No obstructive disease is noted.

### ***Pancreas***

The region of the pancreas is isoechoic relative to surrounding omental fat. No obvious parenchymal abnormalities are observed. There is no evidence of regional inflammation or effusion.

### ***Free Abdomen***

The peritoneal cavity is normal. There is no evidence of inflammation or effusion. The abdominal lymph nodes are normal/not visible.

### ***Other***

A brief echocardiogram reveals no evidence of pericardial effusion or obvious right atrial/auricular mass.

## **ULTRASONOGRAPHIC FINDINGS**

### **Primary Findings:**

- The splenic nodule could be consistent with an early neoplastic process. Alternatively, a benign focus of extramedullary hematopoiesis, lymphoid hyperplasia or splenitis is also possible.
- The diffuse hepatic changes are non-specific and could be consistent with vacuolar hepatopathy, regenerative nodular hyperplasia, and/or age-related remodeling. Inflammatory and infiltrative disease are considered less likely.
- Gallbladder debris/sludge, non-mucocele.

### **Secondary Findings:**

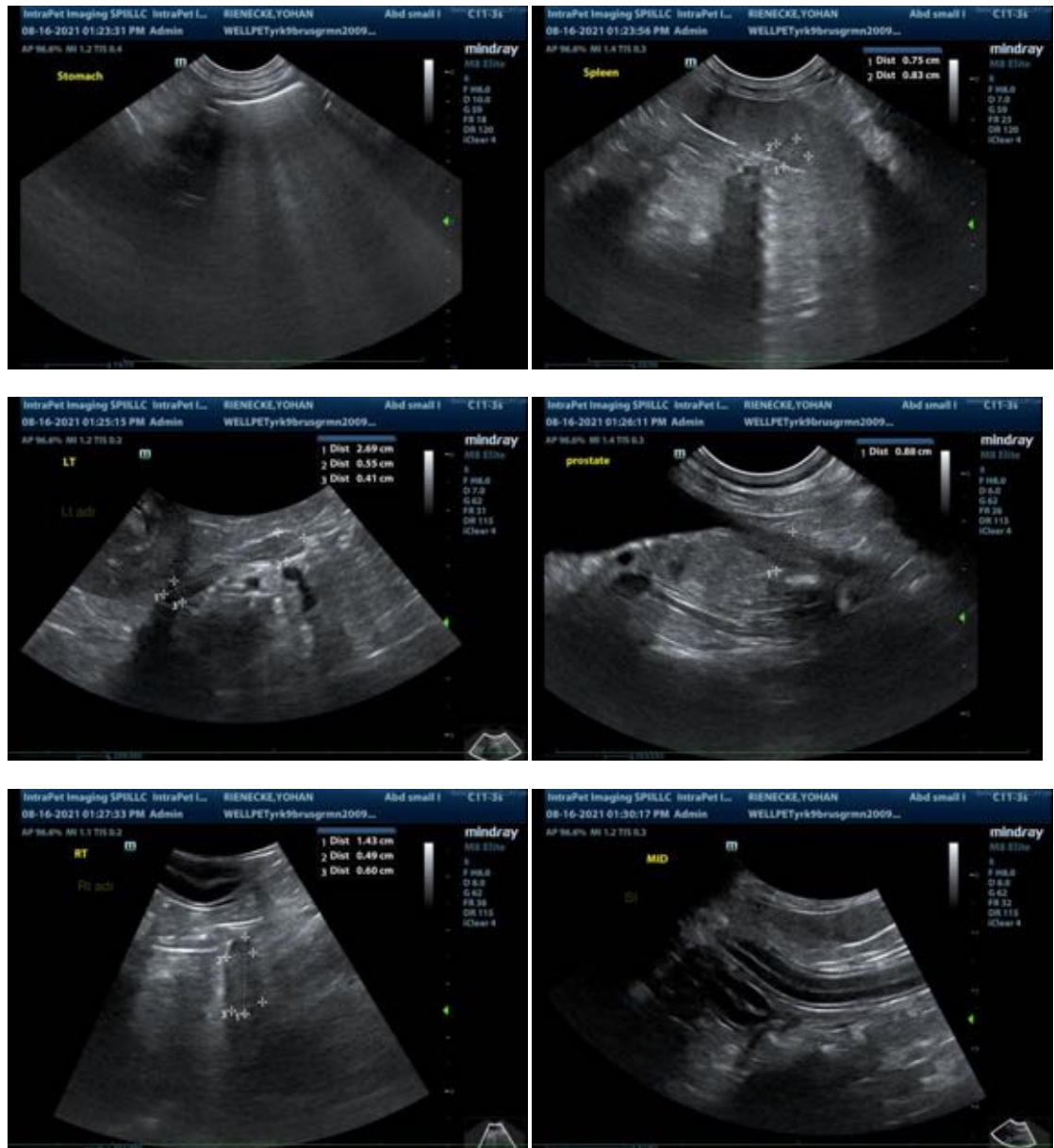
- Minor age-related renal pathology.

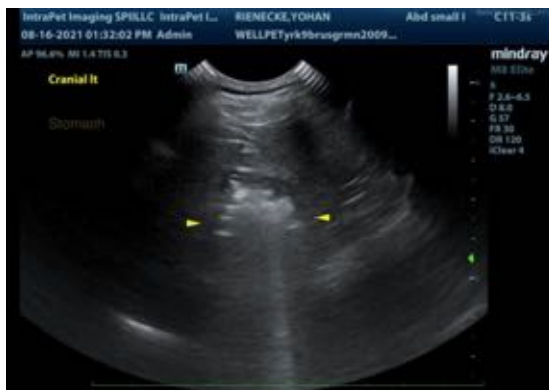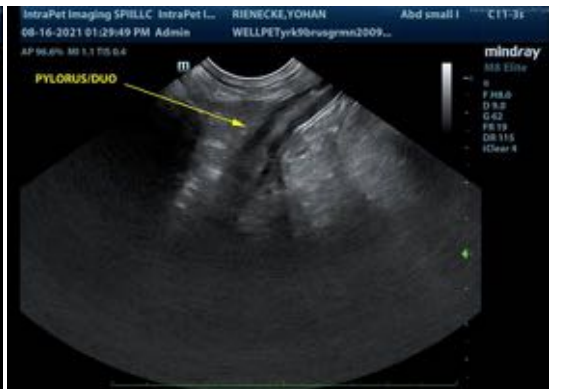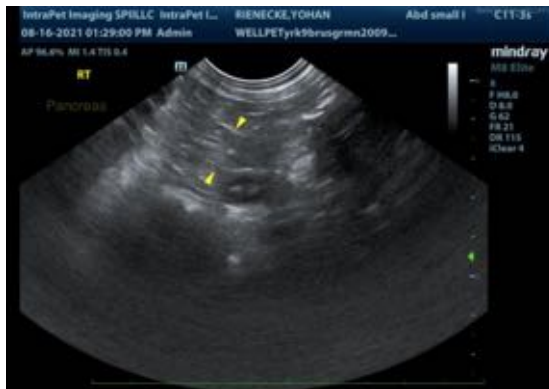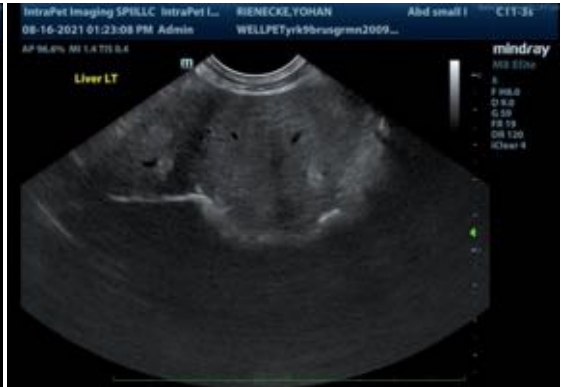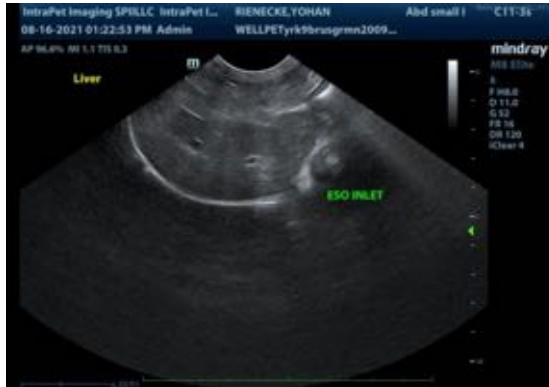\*An obvious cause for the patient's clinical signs is not identified in this study. Differentials include primary gastrointestinal disease (i.e., gastroesophageal reflux, helicobacter infection, other), primary respiratory disease (i.e., tracheal collapse, lower airway disease), other.

## **INTERPRETATION OF THE FINDINGS & FURTHER RECOMMENDATIONS**

- Consider switching from Famotidine to a proton pump inhibitor as empirical treatment for gastroesophageal reflux.
- Also consider transitioning to a hypoallergenic diet to assess for underlying food allergies.
- If a more aggressive approach is desired, consider referral for a bronchoscopy and upper GI endoscopy to assess both the respiratory and gastrointestinal tracts respectively.

- Serial sonography can monitoring (i.e. every 4-6 weeks) of the splenic nodule is recommended. If the nodule increases in size, ultrasound-guided aspiration or splenectomy with histopathology can be considered.





The information and recommendations provided are based on the images presented by the referring veterinarian. No evaluation can be communicated regarding pathology that was not visible in the image/video clips provided.

Thank you for this referral. If the clinical or image interpretation does not parallel your findings or if I can be of any further assistance please contact me.

Andrea Nicastro, DVM, Diplomate ACVIM (*Small Animal Internal Medicine*)  
 Andrea.nicastro@sonopath.com