

**DATE PRESENTING CLINICAL SIGNS**

8/16/21 History: Hepatopathy. No other history provided by the veterinarian.

**PATIENT** Current Medications: Not provided by the veterinarian.

Frank Pham Lab Results: Not provided by the veterinarian.

**SPECIES** Radiographs: Not provided by the veterinarian.

Canine Date of Previous IntraPet Ultrasound: No previous IntraPet scans.

**BREED** Sedation: Sedation not required for scan.

Irish Terrier Stat Report: STAT report not requested by the veterinarian.

**SEX ULTRASONOGRAPHIC EXAMINATION OF THE ABDOMEN**

Male Neutered

**Urinary System**

The urinary bladder is mildly to moderately distended. The wall is moderately distended. The wall is slightly thickened (up to 0.54 cm) with an irregular mucosal surface. A small amount of echogenic debris is suspended within the lumen. No cystic calculi are observed. The region of the trigone and the visible portion of the proximal urethra are normal.

**AGE**

9/6/06

**WEIGHT**

13.1 kg.

The prostate is normal in size (1.23 cm in width) and shape. Parenchyma is homogenous. The prostatic urethra appears normal without evidence of dilation or obstruction.

The left kidney is normal size (5.30 cm in length) with a normal shape, smooth peripheral margins, and normal internal architecture. There is mild loss of corticomedullary distinction. One to two small cortical cysts are visualized. Several hyperechoic shadowing diverticular foci are observed. There is no evidence of pyelectasia, infarcts or hydronephrosis. Renal vasculature is normal.

**INTERPRETED BY**

Andrea Nicastro, DVM,  
Diplomate ACVIM  
(Small Animal Internal  
Medicine)

Three still images of the right kidney are available for interpretation. The right kidney is normal size (5.41 cm in length) with a normal shape, smooth peripheral margins, and normal internal architecture. There is mild loss of corticomedullary distinction. Several hyperechoic shadowing diverticular foci are observed. There is no evidence of pyelectasia, infarcts or hydronephrosis. Renal vasculature is normal.

**HOSPITAL NAME**

Banfield Pet Hospital  
of Towson

**Adrenal Glands**

The left adrenal gland is normal size (0.48 cm at cranial pole) (0.49 cm at caudal pole) (1.72 cm in length); normal shape; homogenous parenchyma. The glandular echogenicity and detail are unremarkable. Capsule, cortex, and medullary definition are normal. The phrenicoabdominal vein and surrounding vasculature are normal.

**REFERRING VET**

Dr. Washington

The right adrenal gland is normal size (0.66 cm at cranial pole) (0.56 cm at caudal pole) (2.32 cm in length); normal shape; homogenous parenchyma. The glandular echogenicity and detail are unremarkable. Capsule, cortex, and medullary definition are normal. The phrenicoabdominal vein and surrounding vasculature are normal.

**INVOICE**

11648kk

**Spleen**

The spleen is normal in size (1.76 cm in width at the level of the hilus) with a normal capsular contour. There is appropriate echogenicity and echotexture. Several, irregular, hyperechoic nodules/areas are observed throughout the organ, particularly in the region of the hilus. Splenic vasculature is normal.

### ***Liver***

The liver is subjectively enlarged with swollen/rounded peripheral contours. The parenchyma is isoechoic relative to the spleen and exhibits subtle heterogeneity. A 4.11 x 2.27 cm isoechoic to slightly heterogeneous mass is observed on the left. Hepatic vasculature and intrahepatic biliary tracts are of normal volume with no evidence of congestion. The gall bladder lumen is moderately distended. The wall is thin and smooth. A small to moderate amount of aggregated, echogenic, partially dependent, stranding debris is observed within the lumen. The cystic and common bile ducts are normal/not seen.

### ***Gastrointestinal***

The gastric lumen is moderately distended with ingesta. The gastric wall and pylorus are normal in thickness with a normal layering pattern. The pyloric outflow tract is patent. The small intestinal lumen is not dilated. The small intestinal wall thickness is normal with a normal layering pattern and appropriate mural detail. Discreet masses are not identified. The colonic wall is normal. No obstructive disease is noted.

### ***Pancreas***

The right limb of the pancreas is prominent in size with irregular peripheral contours. The parenchyma is hypoechoic relative to surrounding omental fat and mildly heterogeneous in appearance. A 0.80 cm cystic lesion is observed in this region. The pancreatic duct is not overtly dilated. The mesentery effacing the serosal surface is mildly hyperechoic.

### ***Free Abdomen***

There is no evidence of free fluid. The abdominal lymph nodes are normal/not visible.

## **ULTRASONOGRAPHIC FINDINGS**

### **Primary Findings:**

- Left hepatic mass. Neoplasia (i.e., adenoma, adenocarcinoma) is considered likely. However, benign pathology (i.e., regenerative nodular hyperplasia) cannot be completely excluded. The diffuse hepatic parenchymal changes are non-specific and could be secondary to vacuolar hepatopathy, regenerative nodular hyperplasia, age-related remodeling, inflammatory/immune-mediated disease and less likely, infiltrative neoplasia or other hepatopathy.
- Gall bladder debris, non-mucocele.

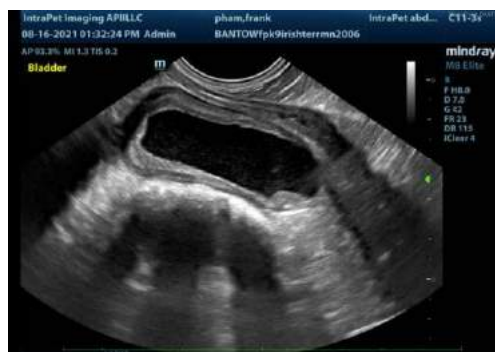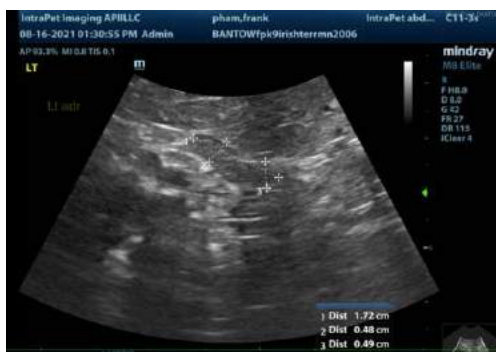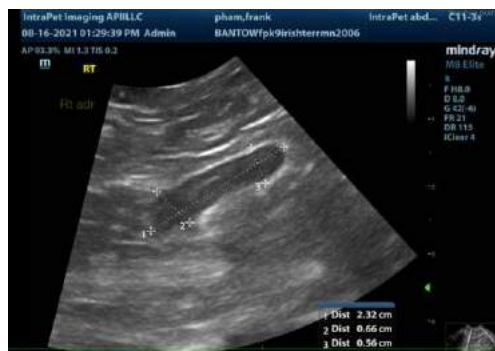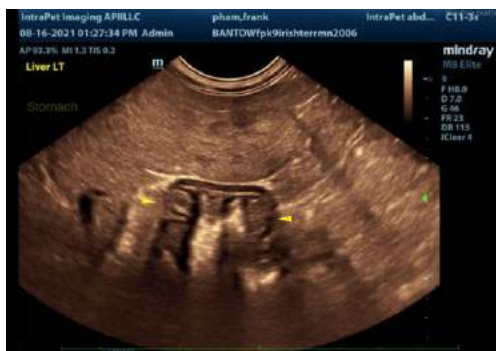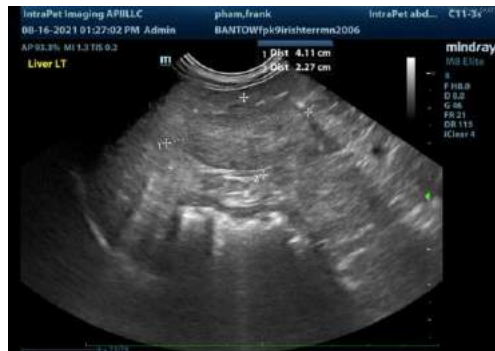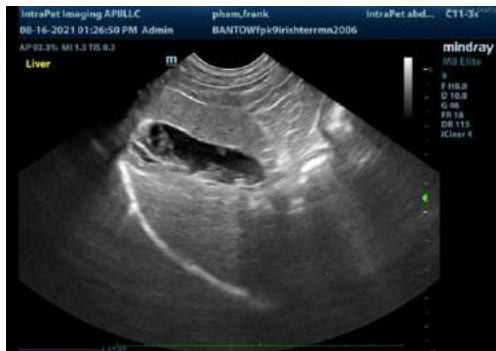### **Secondary Findings:**

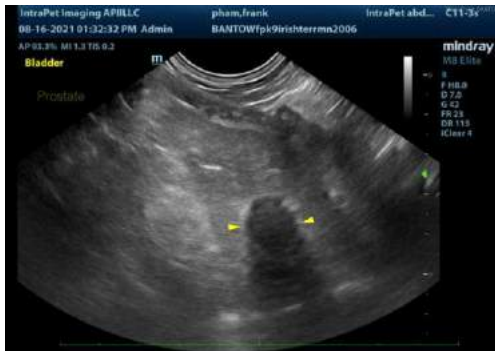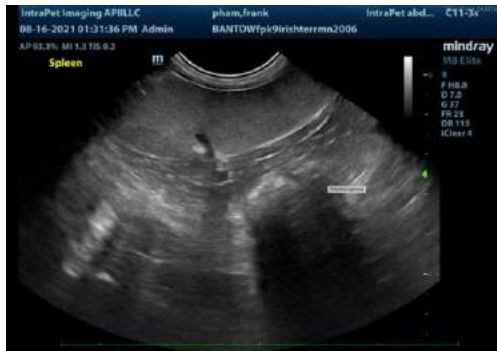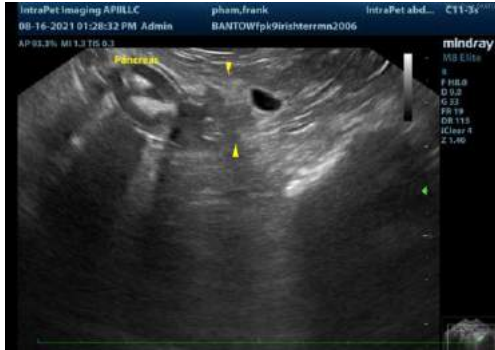
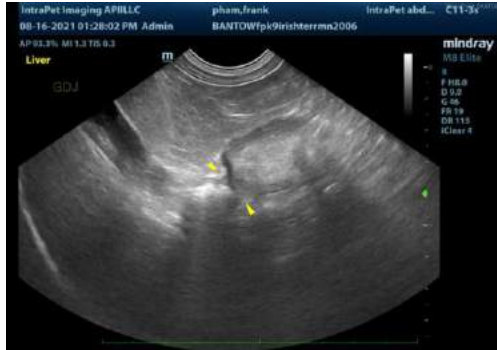
- The pancreatic changes are most consistent with chronic, active pancreatitis with a parenchymal cyst.
- Bilateral age-related renal changes with dystrophic mineralization.
- The urinary bladder wall changes could be consistent with cystitis and/or artifactual due to lack of full repletion. Correlation with clinical findings is recommended.
- The hyperechoic lesions adjacent to the splenic vessels are most consistent with myelolipomas. Although a neoplastic process within the spleen cannot be excluded, it is considered unlikely in this patient.

## **INTERPRETATION OF THE FINDINGS & FURTHER RECOMMENDATIONS**

1. Three-view thoracic radiographs are recommended to assess for pulmonary metastases.

- If there is no evidence of pulmonary metastatic disease, consider hepatic mass removal with biopsy of the other lobes.
- Baseline lab work including a CBC chemistry panel, urinalysis, and T4 +/- urine culture and sensitivity is recommended prior to anesthesia.
- Depending on the patient's clinical signs, a PLI +/- full malabsorption panel should also be considered.





The information and recommendations provided are based on the images presented by the referring veterinarian. No evaluation can be communicated regarding pathology that was not visible in the image/video clips provided.

Thank you for this referral. If the clinical or image interpretation does not parallel your findings or if I can be of any further assistance, please contact me.

Andrea Nicastro, DVM, Diplomate ACVIM (*Small Animal Internal Medicine*)  
Andrea.nicastro@sonopath.com