



## PATIENT

Frank Animals Live,  
Let These

## SPECIES

Feline

## BREED

DSH

## SEX

Neutered Male

## AGE

1 year

## WEIGHT

10.18 lbs

## INTERPRETED BY

Andrea Nicastro,  
DVM, Diplomate  
ACVIM (*Small Animal  
Internal Medicine*)

## IMAGING PERFORMED BY

Adrienne Waffle

## HOSPITAL NAME

Torch Lake VC

## REFERRING VET

Adrienne Waffle

## INVOICE

11412

## DATE

8.15.22

## PRESENTING CLINICAL SIGNS

History: Hx of vomiting hairball on Friday night. Presented to us on Saturday morning for 12 hours of anorexia. Owner was concerned about obstruction. She was unsure of urination/defecation as she has 7 other cats. He was started on cerenia and convenia. Owner started mirtazepine yesterday.

Abnormal PE/Chem/CBC/UA Results: Saturday: T- 100.9 MM -pink<2 Attitude QAR Bloodwork unremarkable Abdominal rads showed no dilation of GI suggestive of FB Today: T - 102.9; QAR; 120 HR; Has had 50 mg gabapentin for ultrasound

## ULTRASONOGRAPHIC EXAMINATION OF THE ABDOMEN

### Urinary System

The **urinary bladder** wall is normal in thickness and the mucosal surface is smooth. The bladder lumen is moderately distended with anechoic urine. No masses, inflammatory changes or calculi are observed. The region of the trigone is normal.

The **left kidney** is normal size (3.49 cm in length); normal shape and architecture with smooth peripheral margins. There is a normal 1:3 cortex to medulla ratio with normal corticomedullary distinction. There is no evidence of pyelectasia, nephroliths, infarcts or hydroureter.

The **right kidney** is normal size (3.65 cm in length); normal shape and architecture with smooth peripheral margins. There is a normal 1:3 cortex to medulla ratio with normal corticomedullary distinction. There is no evidence of pyelectasia, nephroliths, infarcts or hydroureter. Renal vasculature is normal.

### Adrenal Glands

The **left adrenal gland** is normal size (0.46 cm width). Normal shape and glandular echogenicity. The phrenicoabdominal vein and surrounding vasculature are normal.

The **right adrenal gland** is normal size (0.42 cm width). Normal shape and glandular echogenicity. The phrenicoabdominal vein and surrounding vasculature are normal.

### Spleen

The **spleen** is prominent in size (1.03 cm in width at the level of the hilus) with normal curvilinear peripheral contours. There is appropriate echogenicity and echotexture. No focal lesions are observed. Splenic vasculature is normal.

### Liver

The **liver** is subjectively normal in size with normal contours and structure. There is appropriate echogenicity and echotexture. No overt structural evidence of inflammatory, infiltrative, or regenerative pathology is evident. Vascular and biliary tracts are of normal volume with no evidence of congestion. No pathological hepatic lymphadenopathy observed.

The **gall bladder** lumen is moderately distended. The wall is thin and smooth. Luminal contents are anechoic. The cystic and common bile ducts are normal/not seen.

### Gastrointestinal

The **gastric lumen** is not distended. The gastric wall is normal in thickness with a normal layering pattern. The small intestinal lumen is not dilated. The small intestinal wall thickness is normal with a normal layering pattern and appropriate mural detail. Discreet masses are not identified. The colonic wall is normal. There is no evidence of an obstructive pattern.

### ***Pancreas***

The left limb of the **pancreas** is visible with normal curvilinear peripheral contours. The parenchyma is slightly hypoechoic relative to surrounding omental fat. No distinct focal lesions are observed. The pancreatic duct is not overtly dilated.

### ***Free Abdomen***

A small amount of anechoic free fluid is present. The abdominal **lymph nodes** are normal/not visible.

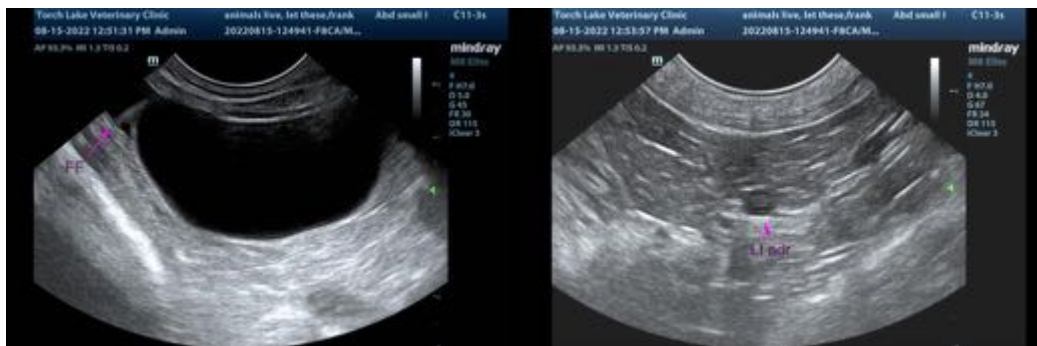
## **ULTRASONOGRAPHIC FINDINGS**

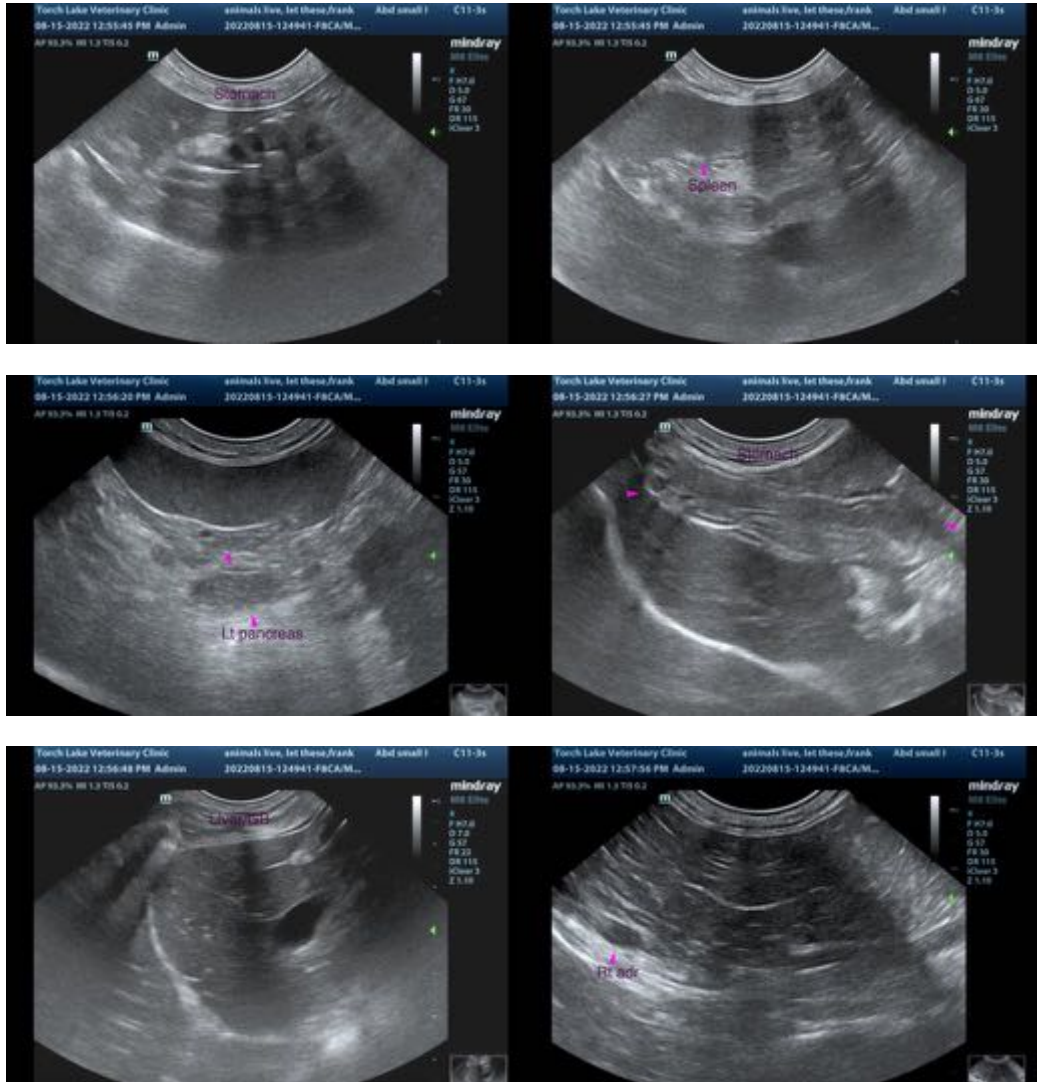
### **Primary Findings**

- The mild splenomegaly may be a normal variant for this patient or may be secondary to antigenic stimulation, splenitis, lymphoid hyperplasia, extramedullary hematopoiesis or infiltrative neoplasia (i.e., round cell tumor).
- The ascites may be secondary to increased vascular permeability, low oncotic pressure, or increased hydrostatic pressure (i.e., due to congestive heart failure, fluid overload).
- The pancreatic changes may be a normal variant for this patient or could be consistent with mild, chronic pancreatitis. Correlation with clinical findings is recommended.

## **INTERPRETATION OF THE FINDINGS & FURTHER RECOMMENDATIONS**

- Three-view thoracic radiographs are recommended to assess cardiopulmonary status, particularly in light of the ascites.
- Consider a fine-needle aspirate of the spleen if clotting status is appropriate. A 25-gauge needle should be used. If accessible, fluid analysis and cytology on the free abdominal fluid is also recommended.
- Consider an fPLI to assess further assess for pancreatitis.
- Feline Leukemia and FIV testing should also be considered, if not already performed.





The information and recommendations provided are based on the images presented by the referring veterinarian/sonographer. No evaluation can be communicated regarding pathology that was not visible in the image/video clips provided.

Thank you for this referral. If the clinical or image interpretation does not parallel your findings or if I can be of any further assistance, please contact me.

**Andrea Nicastro, MPH, DVM, Diplomate DACVIM (Small Animal Internal Medicine)**  
[info@SonoPath.com](mailto:info@SonoPath.com)