

**DATE PRESENTING CLINICAL SIGNS**

8/14/21

Known diabetic. Wednesday PM, ADR. Started vomiting Thursday morning and has not been eating, has been very lethargic. Now he is getting weaker and is unsteady on his feet. Saw RDVM this morning and diagnosed with pancreatitis. Abdominal pain, vomiting, hypoxemia.

PATIENT

Nate Park

Date of Previous IntraPet Ultrasound: No previous.

SPECIES

Canine

Sedation: No sedation necessary.

Stat Report: Stat report not indicated.

BREED

Miniature Schnauzer

ULTRASONOGRAPHIC EXAMINATION OF THE ABDOMEN**Urinary System**

The urinary bladder is mildly distended. The wall is of appropriate thickness for the level of repletion. The mucosal surface is slightly irregular. A scant amount of echogenic debris is suspended within the lumen. No cystic calculi are observed. The region of the trigone is normal.

SEX

Male Neutered

The prostate is normal in size (1.14 cm in width) and shape. Parenchyma is homogenous. The prostatic urethra appears normal without evidence of dilation or obstruction.

AGE

8/14/08

The left kidney is normal size (5.32 cm in length); normal shape and architecture with smooth peripheral margins. There is a normal 1:3 cortex to medulla ratio with moderate loss of corticomedullary distinction. There is no evidence of pyelectasia, nephroliths, infarcts or hydroureter.

WEIGHT

14.6 lbs.

The right kidney is normal size (6.31 cm in length) with a normal shape, smooth peripheral margins, and normal internal architecture. There is moderate loss of corticomedullary distinction. Several hyperechoic shadowing diverticular foci are observed. There is no evidence of pyelectasia, infarcts or hydronephrosis.

INTERPRETED BY

Andrea Nicastro, DVM,
 Diplomate ACVIM
 (Small Animal Internal
 Medicine)

Adrenal Glands

The left adrenal gland is mildly enlarged (0.73 cm at cranial pole) (0.74 cm at caudal pole) (1.84 cm in length); normal shape; homogenous parenchyma. The glandular echogenicity and detail are unremarkable. Capsule, cortex, and medullary definition are normal. The phrenicoabdominal vein and surrounding vasculature are normal.

HOSPITAL NAME

Animal Emergency
 Hospital

The right adrenal gland is mildly enlarged (0.54 cm at cranial pole) (0.67 cm at caudal pole) (2.00 cm in length); normal shape; homogenous parenchyma. The glandular echogenicity and detail are unremarkable. Capsule, cortex, and medullary definition are normal. The phrenicoabdominal vein and surrounding vasculature are normal.

REFERRING VET

Dr. Goessling

Spleen

The spleen is normal in size (1.25 cm in width at the level of the hilus) with a normal capsular contour. There is appropriate echogenicity and echotexture. No focal lesions are observed. Splenic vasculature is normal.

INVOICE

11646kk

Liver

The liver is subjectively prominent in size with slightly swollen peripheral contours. The parenchyma is isoechoic relative to the spleen. A 1.78 cm hyperechoic area is observed in the deep left liver. Hepatic vasculature and intrahepatic biliary tracts are of normal volume with no evidence of congestion. The gall bladder is distended. The wall is normal in thickness. A large amount of aggregated, echogenic, suspended sludge in a partially stellate pattern is observed within the lumen. The cystic and common bile ducts are normal.

Gastrointestinal

The stomach and intestine are free of stasis and exhibit normal peristaltic activity. The gastric lumen is not distended. The gastric wall and pylorus are normal in thickness with a normal layering pattern. The pyloric outflow tract is patent. The small intestinal lumen is not dilated. The small intestinal wall thickness is normal with a normal layering pattern and appropriate mural detail. Discreet masses are not identified. The colonic wall is diffusely and mildly thickened (up to 0.47 cm) with retention of the normal layering pattern. There is no evidence of obstruction.

Pancreas

The right limb of the pancreas is enlarged with minimal deviation from the normal peripheral contours. The parenchyma is hypoechoic relative to surrounding omental fat and diffusely mottled in appearance. No distinct focal lesions are observed. The pancreatic duct is not overtly dilated. The mesentery effacing the serosal surface is slightly hyperechoic.

Free Abdomen

There is no evidence of free fluid. A few prominent lymph nodes are observed in the cranial abdomen.

ULTRASONOGRAPHIC FINDINGS

Primary Findings:

- Fully developed gall bladder mucocele.
- The diffuse hepatic changes are non-specific and could be consistent with vacuolar hepatopathy, regenerative nodular hyperplasia, and/or age-related remodeling. Inflammatory and infiltrative disease are considered less likely. However, correlation with the patient's liver values is recommended.
- The pancreatic changes are suggestive of chronic active pancreatitis.
- The cranial abdominal lymphadenopathy could be consistent with lymphoid hyperplasia, reactive lymphadenitis, or less likely, infiltrative neoplasia.

Secondary Findings:

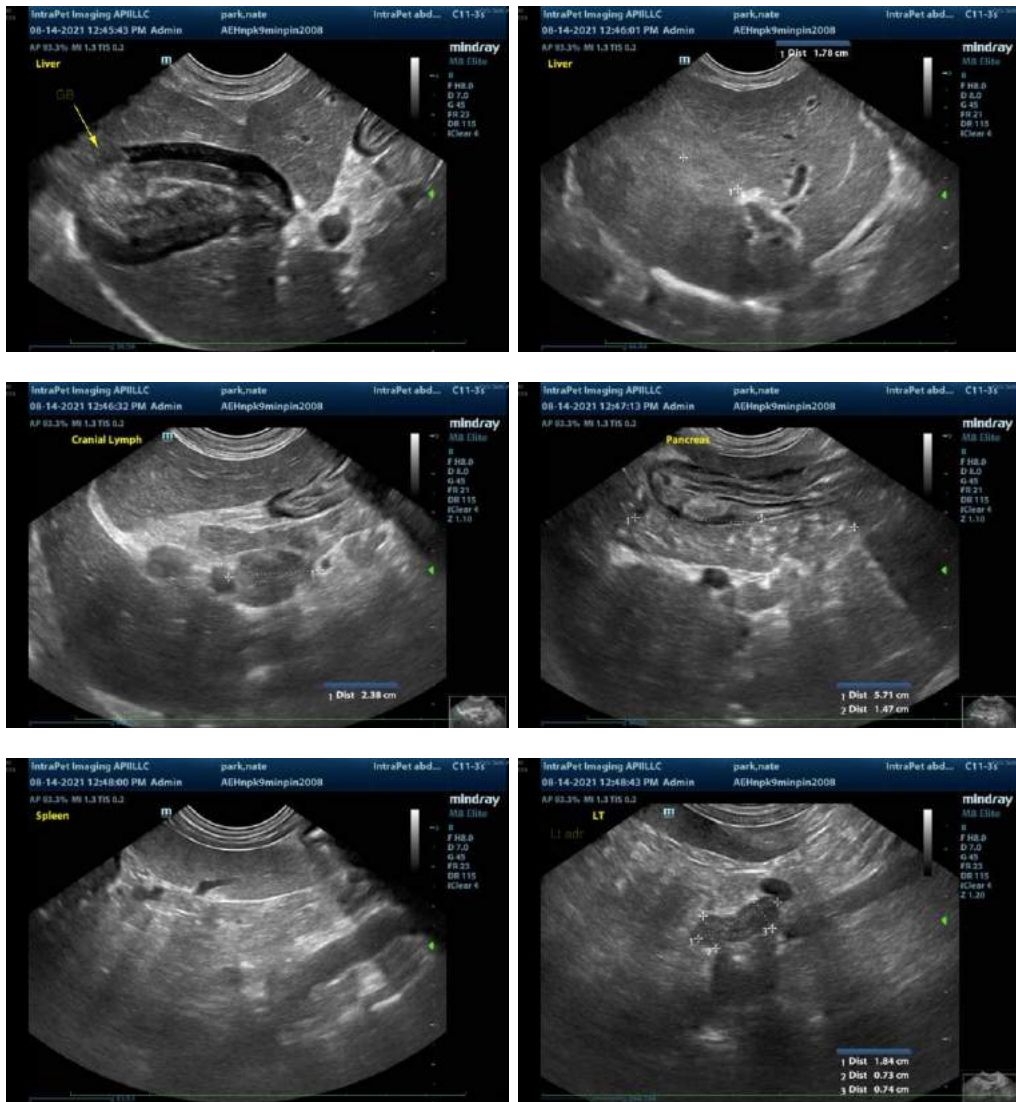
- Mild bilateral adrenomegaly.
- Bilateral, age-related renal changes with right dystrophic mineralization.
- The colonic wall changes are most consistent with an inflammatory process with a lower possibility of emerging neoplasia.

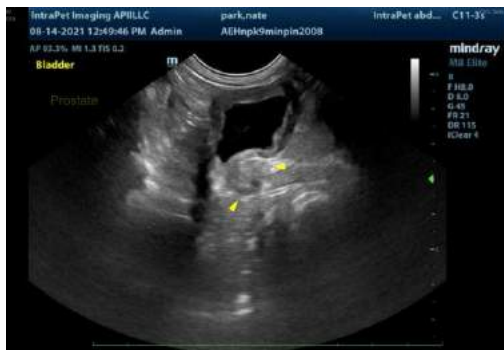
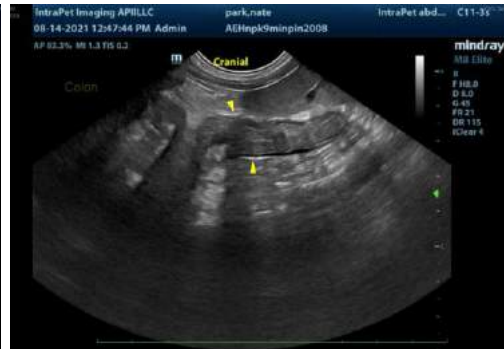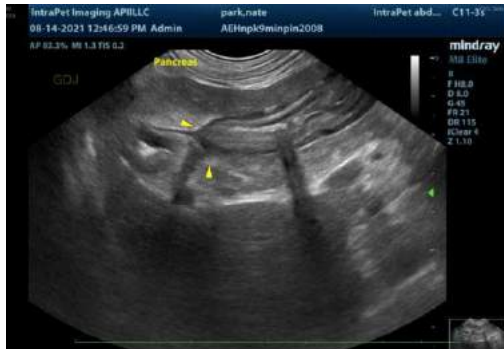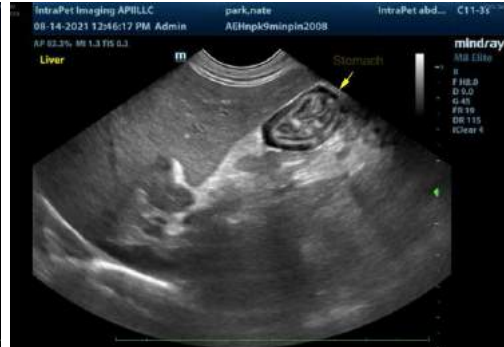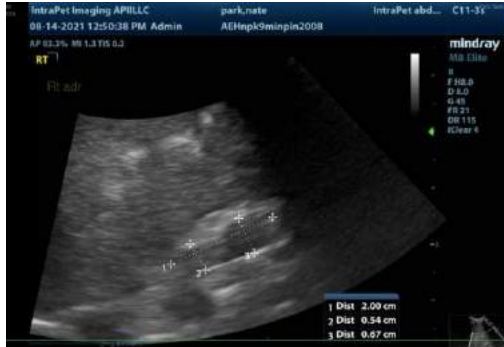**It is unclear whether the patient's clinical signs are related to pancreatitis, cholecystitis secondary to the gall bladder mucocele, concurrent disease, or a combination thereof.

INTERPRETATION OF THE FINDINGS & FURTHER RECOMMENDATIONS

1. Three-view thoracic radiographs are recommended to assess cardiopulmonary status.
2. Consider supportive care for pancreatitis/cholecystitis with IV fluid therapy, gastroprotectants, antiemetics, pain medication, and broad-spectrum antibiotic therapy.

3. Initiation of Ursodiol is also recommended for the mucocele. Once the patient is stabilized, a prophylactic cholecystectomy can be considered, as gall bladder mucoceles have the potential to rupture leading to bile/septic peritonitis. If surgery is pursued, referral to a board-certified veterinary surgeon is recommended due to the potential for perioperative complications. If a more conservative approach is desired, Ursodiol therapy can be continued with serial sonographic monitoring (i.e., every 4 weeks) of the gall bladder to assess for progression.
4. Also consider a malabsorption panel including serum cobalamin, folate, PLI and TLI.





The information and recommendations provided are based on the images presented by the referring veterinarian. No evaluation can be communicated regarding pathology that was not visible in the image/video clips provided.

Thank you for this referral. If the clinical or image interpretation does not parallel your findings or if I can be of any further assistance, please contact me.

Andrea Nicastro, DVM, Diplomate ACVIM (*Small Animal Internal Medicine*)
 Andrea.nicastro@sonopath.com