**PATIENT**

Oscar Ziegler 276951

SPECIES

Canine

BREED

Boxer

SEX

Neutered Male

AGE

7 years, 6 mos

WEIGHT

30.5 kg

INTERPRETED BY

Andrea Nicastro, DVM,
Diplomate ACVIM
(Small Animal Internal
Medicine)

IMAGING PERFORMED BY

Tom McNeill

HOSPITAL NAME

SVS Imaging CT

REFERRING VET

WVRC- Dr. Mallo

INVOICE

11395

DATE

8.12.22

PRESENTING CLINICAL SIGNS

History: Oscar has had chronic V/D, anorexia, weight loss over the past ~4 months. In April 2022, when signs started, owners also noticed a mass present on the ventral neck. Sampling has not been performed. Seen more recently at rDVM (08/04/2022) for persistent signs. ABXR, CXR = WNL. CBC, Chem/lytes = WNL (per owner). Recommended advanced imaging as next step. Seen at Racine WVRC 08/11/2022 for these signs (as he had not eaten for 2-3 days). Recommended AUS as next step. At Racine visit, AIVR was noted (HR 120-150, but brief periods where HR would climb to 170 bpm). No treatments performed. No current medications, but has been on maropitant, metronidazole, and omeprazole in these past few months.

Abnormal PE/Chem/CBC/UA Results:

ULTRASONOGRAPHIC EXAMINATION OF THE ABDOMEN**Urinary System**

The **urinary bladder** is normal in thickness and the mucosal surface is smooth. The bladder lumen is moderately distended with anechoic urine. No masses, inflammatory changes or calculi are observed. The region of the trigone is normal.

The **prostate** is difficult to visualize due to its pelvic location. In one still image, the prostate appears normal in size (1.40 cm in width) with a normal shape and homogenous parenchyma. The prostatic urethra does not appear to be overtly dilated.

The **left kidney** is normal size (7.02 cm in length); normal shape and architecture with smooth peripheral margins. There is a normal 1:3 cortex to medulla ratio with minimal loss of corticomedullary distinction. There is no evidence of pyelectasia, nephroliths, infarcts or hydroureter.

The **right kidney** is normal size (7.54 cm in length); normal shape and architecture with smooth peripheral margins. There is a normal 1:3 cortex to medulla ratio with minimal loss of corticomedullary distinction. There is no evidence of pyelectasia, nephroliths, infarcts or hydroureter.

Adrenal Glands

The **left adrenal gland** is normal size (0.55 cm at cranial pole) (0.69 cm at caudal pole); normal shape; homogenous parenchyma. The glandular echogenicity and detail are unremarkable. Capsule, cortex, and medullary definition are normal. The phrenicoabdominal vein and surrounding vasculature are normal.


In one still image, the **right adrenal gland** appears normal size (0.66 cm at cranial pole) (0.77 cm at caudal pole); normal shape; homogenous parenchyma. The glandular echogenicity and detail are unremarkable. Capsule, cortex, and medullary definition are normal. The phrenicoabdominal vein and surrounding vasculature are normal.

Spleen

The **spleen** is normal in size (1.46 cm in width at the level of the hilus) with a normal capsular contour. There is appropriate echogenicity and echotexture. No focal lesions are observed. Splenic vasculature is normal.

Liver

The **liver** is subjectively normal in size with normal contours and structure. There is appropriate echogenicity and echotexture. No overt structural evidence of inflammatory, infiltrative, or regenerative pathology is evident. Vascular and biliary tracts are of normal volume with no evidence of congestion. No pathological hepatic lymphadenopathy observed.

**PATIENT**

Oscar Ziegler 276951

The **gall bladder** is moderately distended. The wall is mildly thickened (up to 0.25 cm) and edematous with a “double-walled” effect. Luminal contents are mostly anechoic. The cystic and common bile ducts are normal/not seen.

SPECIES

Canine

Gastrointestinal

The **gastric lumen** is not distended. The gastric wall and pylorus are normal in thickness with a normal layering pattern. The pyloric outflow tract is patent. The small intestinal lumen is not dilated. Several jejunal masses are visualized, the largest measuring approximately 4.00 cm in length. Within these regions, the wall is severely thickened (up to 1.39 cm) with loss of the normal layering pattern. At least one 5.00 cm ileal mass effect is also seen. The wall in this region is severely thickened (up to 1.13 cm) with loss of the normal layering pattern. The mesentery effacing the serosal surface of the small intestinal masses is hyperechoic. In the remaining small intestinal segments, the wall is diffusely thickened (up to 0.56 cm) with retention of the normal layering pattern. There is disruption in the normal 1:3 muscularis: mucosal ratio. The ileocecolic junction and colonic wall are normal. There is no evidence of an obstructive pattern.

BREED

Boxer

SEX

Neutered Male

Pancreas

The region of the **pancreas** is isoechoic relative to surrounding omental fat. No obvious parenchymal abnormalities are observed. There is no evidence of regional inflammation or effusion.

AGE

7 years, 6 mos

Free Abdomen

Trace ascites is observed. The mesenteric **lymph nodes** are severely enlarged (up to 3.96 cm), rounded and hypoechoic. Surrounding mesentery is hyperechoic.

WEIGHT

30.5 kg

ULTRASONOGRAPHIC FINDINGS**Primary Findings**

- Multiple small intestinal masses. Neoplasia (i.e., lymphoma, malignant histiocytosis, other round cell neoplasia) is considered likely with a lower possibility of a benign process (i.e., multifocal inflammatory disease). Regional peritonitis is present.
- The mesentery lymphadenopathy is most consistent with infiltrative neoplasia, with a lower possibility of benign change (i.e., pyogranulomatous lymphadenitis, lymphoid hyperplasia)
- The trace ascites is likely secondary to bowel and lymph node pathology.

Secondary Findings

- The gall bladder wall edema could be consistent with cholecystitis, increased hydrostatic pressure, low oncotic pressure, immune-mediated disease, anaphylaxis, other.

INTERPRETATION OF THE FINDINGS & FURTHER RECOMMENDATIONS

- Fine-needle aspirates of the bowel masses and enlarged mesenteric lymph nodes are recommended if clotting status is appropriate.
- Thoracic radiographs are also recommended to assess for neoplasia in the chest.
- Consultation with a board-certified oncologist should also be considered.

INTERPRETED BY

Andrea Nicastro, DVM,
Diplomate ACVIM
(Small Animal Internal
Medicine)

IMAGING PERFORMED BY

Tom McNeill

HOSPITAL NAME

SVS Imaging CT

REFERRING VET

WVRC- Dr. Mallo

INVOICE

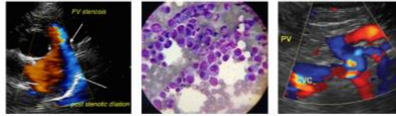
11395

DATE

8.12.22

IMAGING PERFORMED BY

svsimagingqc.net 309-737-3070



Clinical Sonography & Telecytology

EDUCATIONAL TELECONSULTATION SERVICES™

1-800-838-4268 info@sonopath.com SonoPath.com

PATIENT

Oscar Ziegler 276951

SPECIES

Canine

BREED

Boxer

SEX

Neutered Male

AGE

7 years, 6 mos

WEIGHT

30.5 kg

INTERPRETED BY

Andrea Nicastro, DVM,
Diplomate ACVIM
(Small Animal Internal
Medicine)

IMAGING PERFORMED BY

Tom McNeill

HOSPITAL NAME

SVS Imaging CT

REFERRING VET

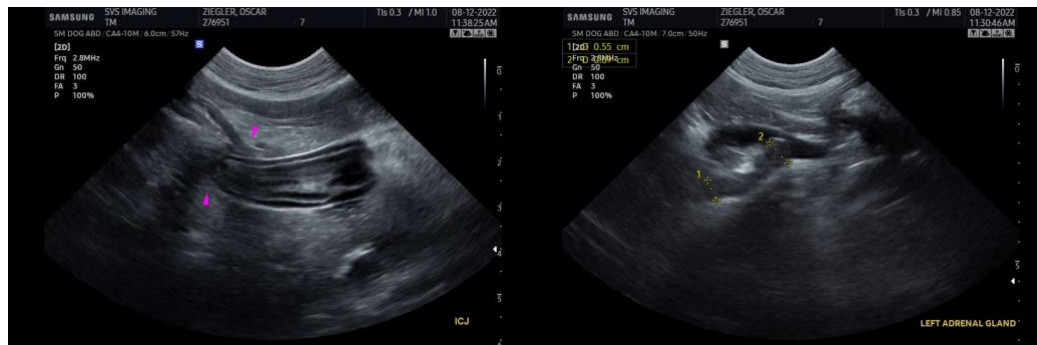
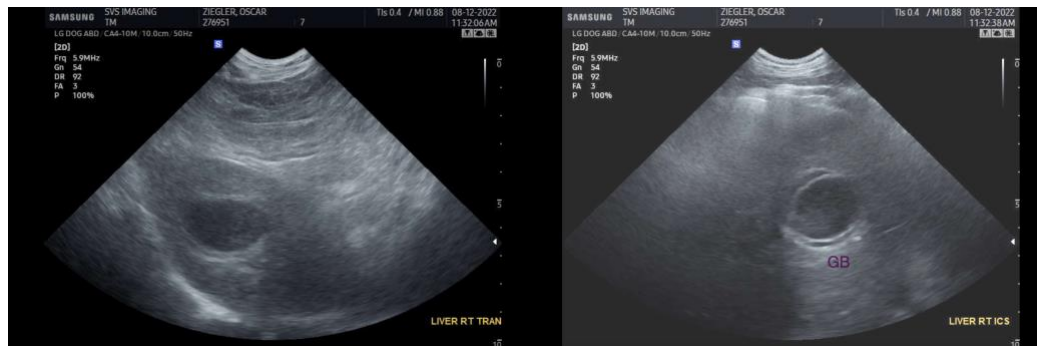
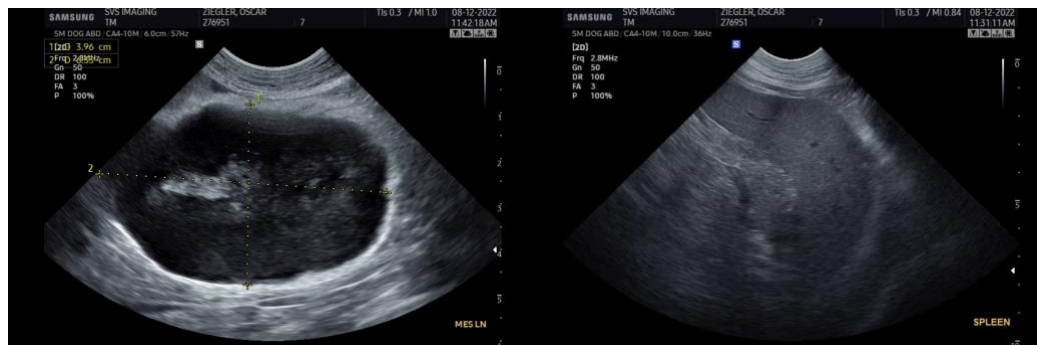
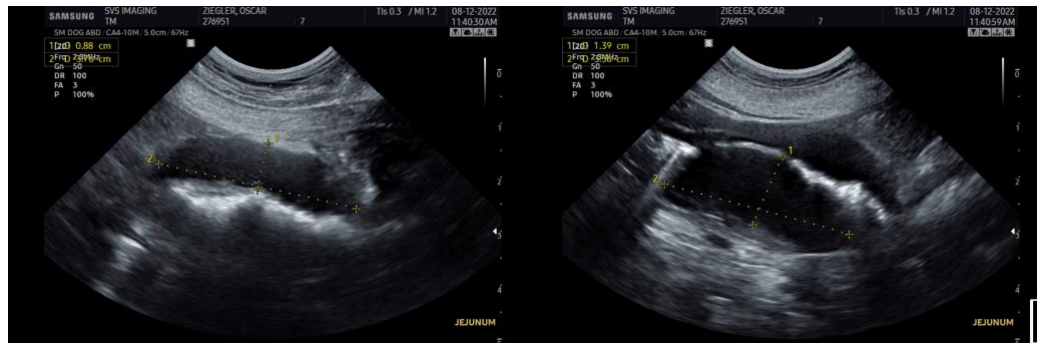WVRC- Dr. Mallo

INVOICE

11395

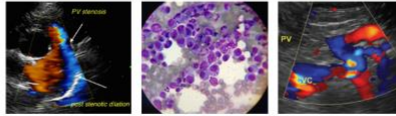
DATE

8.12.22



IMAGING PERFORMED BY

svsimagingqc.net 309-737-3070



Clinical Sonography & Telecytology

EDUCATIONAL TELECONSULTATION SERVICES™

1-800-838-4268 info@sonopath.com SonoPath.com

PATIENT

Oscar Ziegler 276951

SPECIES

Canine

BREED

Boxer

SEX

Neutered Male

AGE

7 years, 6 mos

WEIGHT

30.5 kg

INTERPRETED BY

Andrea Nicastro, DVM,
Diplomate ACVIM
(Small Animal Internal
Medicine)

IMAGING PERFORMED BY

Tom McNeill

HOSPITAL NAME

SVS Imaging CT

REFERRING VET

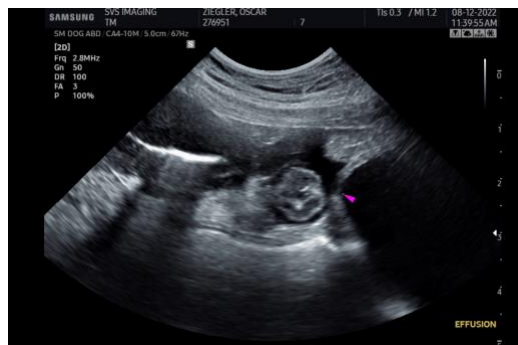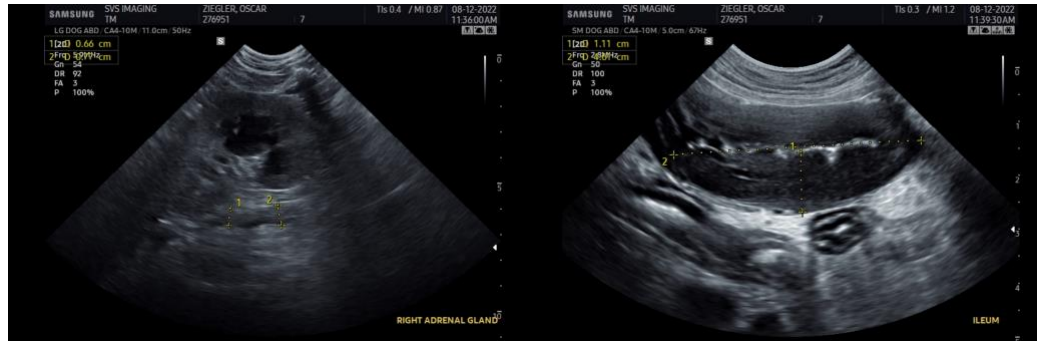
WVRC- Dr. Mallo

INVOICE

11395

DATE

8.12.22



The information and recommendations provided are based on the images presented by the referring veterinarian/sonographer. No evaluation can be communicated regarding pathology that was not visible in the image/video clips provided.

Thank you for this referral. If the clinical or image interpretation does not parallel your findings or if I can be of any further assistance, please contact me.

Andrea Nicastro, MPH, DVM, Diplomate DACVIM (Small Animal Internal Medicine)
info@SonoPath.com