

PATIENT

Sylphie Sayers

SPECIES

Canine

BREED

KCC Spaniel

SEX

Female Spayed

AGE

13 years

WEIGHT

8.7 lbs

INTERPRETED BY

Andrea Nicastro,
DVM, Diplomate
ACVIM (Small Animal
Internal Medicine)

**IMAGING
PERFORMED BY**

Dr. Isermann

HOSPITAL NAME

Animal EHV

REFERRING VET

Dr. Isermann

INVOICE

14031

DATE

8.11.23

PRESENTING CLINICAL SIGNS

History: Patient is presenting for diarrhea, which started 2 days ago. Pt got some bananas and rotisserie chicken as a treat, O thinks she gave her too much but she seemed very hungry. O states pt has a Royal canine GI Low Fat diet she is supposed to be on. O has been giving Pepto since she gave the banana/chicken treat to pt because it happened the last time she gave it a treat. The diarrhea improved, but then this morning at 3am, she started having diarrhea again. Patient has had possible pancreatitis in the past. 4/6 L Systolic heart murmur noted on exam. Previously diagnosed at rDVM, not currently on medications for it. Current medications: Pepto 1/2T

Abnormal PE/Chem/CBC/UA Results: CPL: abnormal BUN: 34.4 ALP: 225 IP: 5.4 GLOB: 4.2 Lact: 3.47

ULTRASONOGRAPHIC EXAMINATION OF THE ABDOMEN

Urinary System

The urinary bladder wall is normal in thickness and the mucosal surface is smooth. The bladder is moderately distended. Luminal contents are anechoic. No cystic calculi are observed. The region of the trigone is normal.

The left kidney is normal in size (4.73 cm in length) with a normal shape, architecture and smooth peripheral margins. The cortex is isoechoic relative to the spleen. There is a normal 1:3 cortex to medulla ratio with minimal to mild loss of corticomedullary distinction. There is no evidence of pyelectasia, nephroliths, infarcts or hydroureter.

The right kidney is normal in size (5.19 cm in length) with a normal shape, architecture and smooth peripheral margins. There is a normal 1:3 cortex to medulla ratio with normal corticomedullary distinction. There is no evidence of pyelectasia, nephroliths, infarcts or hydroureter. Renal vasculature is normal.

Adrenal Glands

The left adrenal gland is borderline enlarged (0.50 cm at cranial pole) (0.55 cm at caudal pole) with a normal shape and homogenous parenchyma. The glandular echogenicity and detail are unremarkable. Capsule, cortex, and medullary definition are normal. The phrenicoabdominal vein and surrounding vasculature are normal.

The right adrenal gland is borderline enlarged (0.49 cm at cranial pole) (0.54 cm at caudal pole) with a normal shape and homogenous parenchyma. The glandular echogenicity and detail are unremarkable. Capsule, cortex, and medullary definition are normal. The phrenicoabdominal vein and surrounding vasculature are normal.

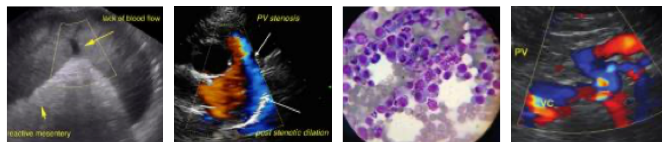
Spleen

The spleen is normal in size (1.69 cm in width at the level of the hilus) with a normal capsular contour. The parenchyma is subtly mottled in appearance. No focal lesions are observed. Splenic vasculature is normal.

Liver

The liver is subjectively normal in size with normal curvilinear peripheral contours. The parenchyma is hypoechoic relative to the spleen with minor changes consistent with age-related remodeling. No focal lesions are observed. Hepatic vasculature and biliary tracts are of normal volume with no evidence of congestion.

The gall bladder is of normal contours and contains some dependent echogenic debris. The wall is normal in thickness. No choleliths are observed. The cystic and common bile ducts are normal/not seen.



PATIENT

Sylphie Sayers

SPECIES

Canine

BREED

KCC Spaniel

SEX

Female Spayed

AGE

13 years

WEIGHT

8.7 lbs

INTERPRETED BY

Andrea Nicastro,
DVM, Diplomate
ACVIM (*Small Animal
Internal Medicine*)

IMAGING PERFORMED BY

Dr. Isermann

HOSPITAL NAME

Animal EHV

REFERRING VET

Dr. Isermann

INVOICE

14031

DATE

8.11.23

Gastrointestinal

The stomach and intestine are free of stasis and exhibit normal peristaltic activity. The gastric lumen is not distended. The gastric wall and pylorus are normal in thickness with a normal layering pattern. The pyloric outflow tract is patent. The small intestinal lumen is not dilated. The small intestinal wall is normal in thickness with a normal layering pattern and appropriate mural detail. Discreet masses are not identified. The wall of the descending colon is borderline thickened (up to 0.35 cm). The descending colonic lumen is mildly fluid-distended. There is no obvious evidence of an obstructive pattern.

Pancreas

The base/right limb of the pancreas are visible with normal curvilinear peripheral contours. The parenchyma is largely isoechoic relative to surrounding omental fat and slightly mottled in appearance. The pancreatic duct is visible but not overtly dilated. There is no evidence of peripancreatic inflammation or effusion.

Free Abdomen

The peritoneal cavity is normal. There is no evidence of inflammation or effusion. The abdominal lymph nodes are normal/not visible.

ULTRASONOGRAPHIC FINDINGS

Primary Findings

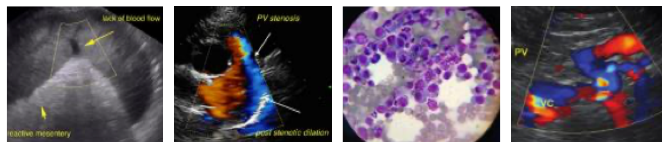
- An obvious cause for the patient's clinical signs is not definitively identified in this study. Considerations include microscopic gastrointestinal disease (i.e., food allergy/intolerance, dietary indiscretion, infectious/parasitic disease, inflammatory bowel disease), underlying metabolic issue, other.

Secondary Findings

- Minor age-related renal and hepatic changes
- Borderline bilateral adrenomegaly
- The pancreatic changes are most consistent with age-related parenchymal remodeling, potentially secondary to a prior inflammatory episode, early fibrosis or chronic pancreatitis.
- The splenic parenchymal changes are most consistent with a benign process such as lymphoid hyperplasia, extramedullary hematopoiesis, splenitis or antigenic stimulation with a low possibility of infiltrative neoplasia (i.e., lymphoma, mast cell neoplasia).

INTERPRETATION OF THE FINDINGS & FURTHER RECOMMENDATIONS

- Given the GI signs, consider the following:
 - Fecal evaluation for internal parasites
 - Prophylactic deworming with Fenbendazole
 - Initiation of a probiotic +/- fiber supplement (i.e., psyllium)
 - If the patient does not respond to medical management, a more advanced GI work-up (i.e., Texas GI panel including serum cobalamin and folate, TLI, PLI and resting cortisol level, hypoallergenic diet trial, +/- GI biopsies) may be warranted.



PATIENT

Sylphie Sayers

SPECIES

Canine

BREED

KCC Spaniel

SEX

Female Spayed

AGE

13 years

WEIGHT

8.7 lbs

INTERPRETED BY

Andrea Nicastro,
DVM, Diplomate
ACVIM (Small Animal
Internal Medicine)

IMAGING PERFORMED BY

Dr. Isermann

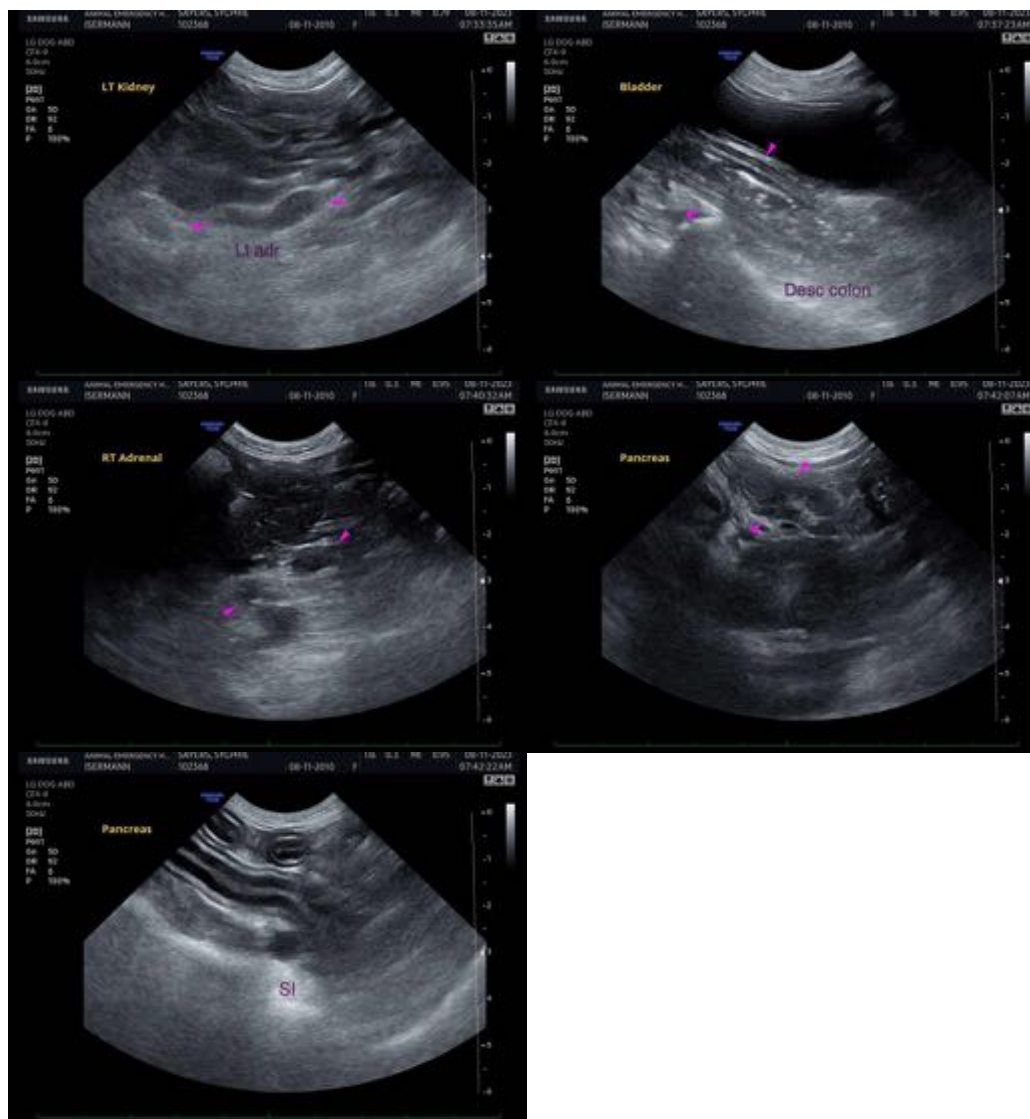
HOSPITAL NAME

Animal EHV

REFERRING VET

Dr. Isermann

- Serial monitoring (i.e., every 3-4 months) of the patient's liver values is recommended. If values continue to increase, a repeat abdomen ultrasound +/- a more advanced hepatic work-up (i.e., tissue sampling) may be warranted.



INVOICE

14031

DATE

8.11.23

The information and recommendations provided are based on the images presented by the referring veterinarian/sonographer. No evaluation can be communicated regarding pathology that was not visible in the image/video clips provided.

Thank you for this referral. If the clinical or image interpretation does not parallel your findings or if I can be of any further assistance, please contact me.

Andrea Nicastro, MPH, DVM, Diplomate DACVIM (Small Animal Internal Medicine)
info@SonoPath.com