

**DATE PRESENTING CLINICAL SIGNS**

8.11.23 Not eating and vomiting.

PATIENT

Current Medications: None listed.
 Date of Previous IntraPet Ultrasound: No previous.
 Sedation: Not required to complete full diagnostic ultrasound.
 Stat Report: STAT requested.
 Imaging Performed By: Rachel Brillhart, RDMS.

SPECIES

Canine

BREED

Labrador Retr Mix

SEX

Neutered Male

AGE

5/16/2016

WEIGHT

116 lbs

INTERPRETED BY

Andrea Nicastro, DMV,
 Diplomate DACVIM
 (Small Animal
 Internal Medicine)

HOSPITAL NAME

Animal MC of Bel Air

REFERRING VET

Dr. Chaudhry

INVOICE

14032

ULTRASONOGRAPHIC EXAMINATION OF THE ABDOMEN**Urinary System**

The urinary bladder and visible portion of the pelvic urethra are normal for the degree of luminal distension. The urine is anechoic with no evidence of debris. Cystic calculi and discrete masses are not observed. The region of the trigone is normal.

The region of the prostate is not visualized due to its pelvic location.

The left kidney is normal in size (7.03 cm in length) with a normal shape, architecture and smooth peripheral margins. The cortex is isoechoic relative to the spleen. There is a normal 1:3 cortex to medulla ratio with mild loss of corticomedullary distinction. There is no evidence of pyelectasia, nephroliths, infarcts or hydronephrosis. Renal vasculature is normal.

The right kidney is normal in size (6.65 cm in length) with a normal shape, architecture and smooth peripheral margins. The cortex is isoechoic relative to the spleen. There is a normal 1:3 cortex to medulla ratio with mild loss of corticomedullary distinction. There is no evidence of pyelectasia, nephroliths, infarcts or hydronephrosis. Renal vasculature is normal.

Adrenal Glands

The left adrenal gland is normal in size (0.89 cm at cranial pole) (0.77 cm at caudal pole) (2.79 cm in length) with a normal shape and homogenous parenchyma. The glandular echogenicity and detail are unremarkable. Capsule, cortex, and medullary definition are normal. The phrenicoabdominal vein and surrounding vasculature are normal.

The right adrenal gland is in normal size (1.02 cm at cranial pole) (0.77 cm at caudal pole) (2.91 cm in length) with a normal shape and homogenous parenchyma. The glandular echogenicity and detail are unremarkable. Capsule, cortex, and medullary definition are normal. The phrenicoabdominal vein and surrounding vasculature are normal.

Spleen

The spleen is normal in size (1.49 cm in width at the level of the hilus) with a normal capsular contour. There is appropriate echogenicity and echotexture. A 0.61 cm hyperechoic nodule is observed just distal to the hilus. Splenic vasculature is normal.

Liver

The liver is subjectively normal in size with normal curvilinear peripheral contours. The parenchyma is hypoechoic relative to the spleen and homogenous in appearance. There is an increase in portal markings. Hepatic vasculature and intrahepatic biliary tracts are of normal volume with no evidence of congestion.

The gall bladder is moderately distended. The wall is diffusely thickened (up to 0.51 cm) and hypoechoic with a "double-walled" effect. A moderate amount of aggregated, echogenic, partially dependent, stranding debris/sludge is observed within the lumen. The cystic and common bile ducts are normal/not seen.

Gastrointestinal

The gastric lumen is not distended. The gastric wall is diffusely thickened (up to 2.30 cm), irregular, and hypoechoic with a loss of the normal layering pattern. The pyloric outflow tract is patent. The small intestinal lumen is not dilated. The small intestinal wall is normal in thickness with a normal layering pattern and appropriate mural detail. The colonic wall is normal. There is no evidence of an obstructive pattern.

Pancreas

The pancreas is normal in size with normal peripheral contours. The pancreatic duct is normal. The base and limbs of the pancreas are isoechoic to surrounding omental fat. No focal lesions are observed. There is no evidence of peripancreatic inflammation or effusion.

Free Abdomen

The mesentery in the cranial abdomen is hyperechoic. There is no obvious evidence of free fluid. The abdominal lymph nodes are normal/not visible.

ULTRASONOGRAPHIC FINDINGS

Primary Findings

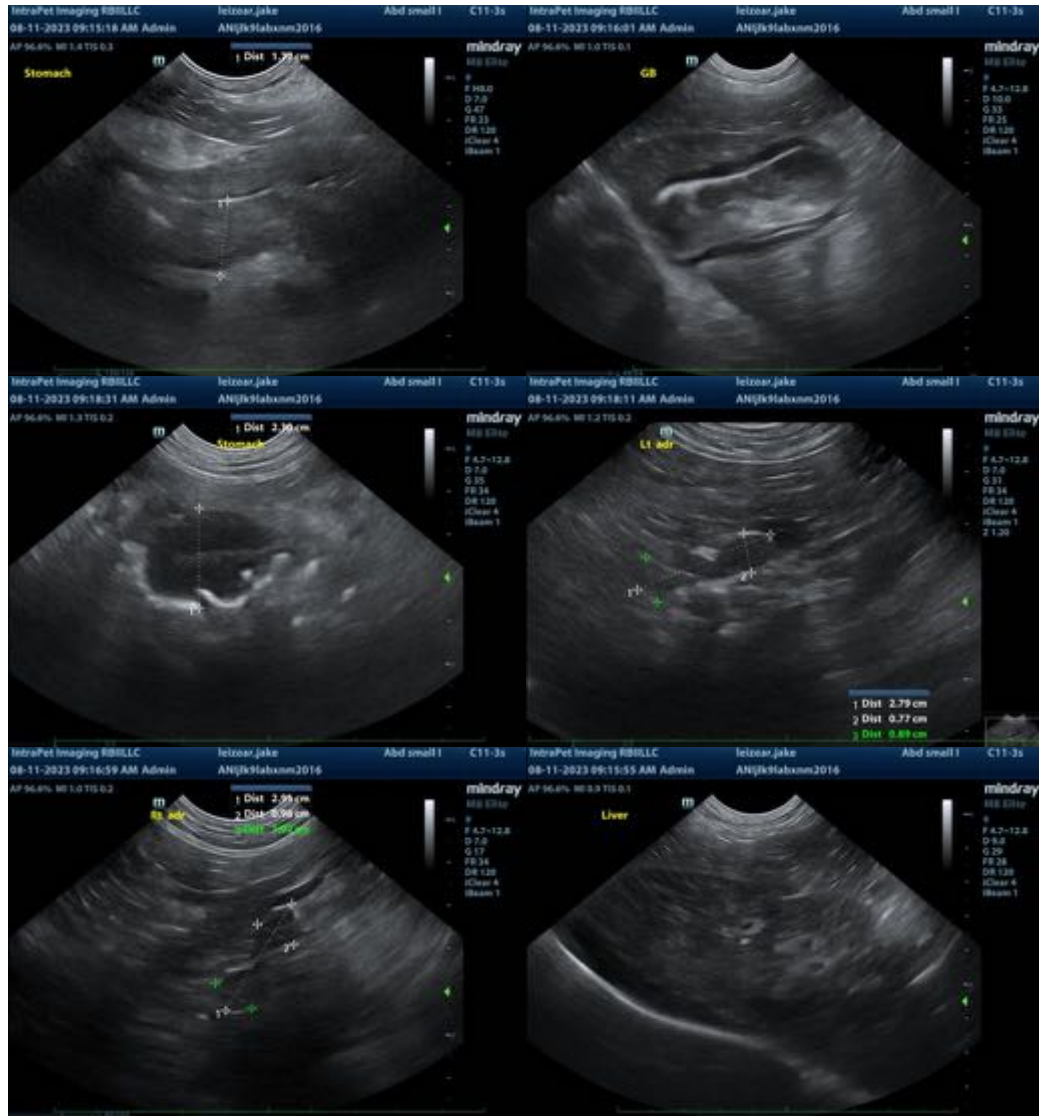
- The gastric wall changes are most consistent with infiltrative neoplasia (i.e., lymphoma, adenocarcinoma). However, severe inflammatory process cannot be completely excluded. Regional peritonitis is present.
- The gallbladder changes could be consistent with cholecystitis with concurrent cholestasis. Other differentials include increased hydrostatic pressure, low oncotic pressure, anaphylaxis, immune-mediated hemolytic anemia or infiltrative neoplasia.

Secondary Findings

- The increase in hepatic portal markings is suggestive of an inflammatory hepatopathy. However, correlation with the patient's liver values is recommended.

INTERPRETATION OF THE FINDINGS & FURTHER RECOMMENDATIONS

- Baseline lab work, including a CBC, chemistry panel, urinalysis and T4 is recommended (if not already performed).
- Three-view thoracic radiographs are recommended to assess for pulmonary metastases.
- Consider fine-needle aspiration of the gastric wall (if clotting status is appropriate). A 25-gauge needle should be used. If the cytology results are inconclusive, endoscopic or surgical GI biopsies may be necessary to get a definitive diagnosis.
- While awaiting test results, symptomatic care for gastritis and cholecystitis is recommended, including gastric protectants, broad-spectrum antibiotics, Ursodiol therapy and other supportive measures.



The information and recommendations provided are based on the images presented by the referring veterinarian/sonographer. No evaluation can be communicated regarding pathology that was not visible in the image/video clips provided.

Thank you for this referral. If the clinical or image interpretation does not parallel your findings or if I can be of any further assistance, please contact me.

Andrea Nicastro, MPH, DVM, Diplomate DACVIM (Small Animal Internal Medicine)
info@SonoPath.com