

**DATE PRESENTING CLINICAL SIGNS**

8/11/21

History: Elevated liver enzymes without symptoms. Murmur reported for a couple of years. Mild bowel issue but no obvious symptoms of liver disease. The patient is also having an echocardiogram performed today.

PATIENT

Current Medications: No current medications.

Hunter Hill

Lab Results: CBC is unremarkable. Chemistry panel: ALP is 299, ALT is 297, total bilirubin is normal, 4dX is negative.

SPECIES

Canine

Radiographs: Radiology(thorax) - subjectively enlarged cardiac silhouette. mildly increased interstitial pattern on lungs. no obvious mass observed on thorax. severely distended colon and rectum with fecal material. empty stomach and small intestinal loops. loss of serosal detail due to fecal material in colon. enlarged liver. no other significant abnormalities observed.

BREED

Cockapoo

Date of Previous IntraPet Ultrasound: No previous IntraPet scans.

SEX

Male Neutered

Sedation: Sedation not required for scan.

Stat Report: STAT report not requested by the veterinarian.

AGE

11/21/09

ULTRASONOGRAPHIC EXAMINATION OF THE ABDOMEN**Urinary System**

The urinary bladder, trigone, and pelvic urethra are normal in thickness and the mucosal surface is smooth.

WEIGHT

32 lbs.

The bladder lumen is moderately distended with mostly anechoic urine. No masses, inflammatory changes or calculi are observed. Ureteral papillae and visualized portion of the proximal urethra, visible to a depth of 2 cm, are normal.

INTERPRETED BY

Andrea Nicastro, DVM,
Diplomate ACVIM
(Small Animal Internal
Medicine)

The prostate is normal in size (1.02 cm in width) and shape. Parenchyma is homogenous. The prostatic urethra appears normal without evidence of dilation or obstruction.

HOSPITAL NAME

Banfield Pet Hospital
of Columbia

The left kidney is normal size (4.87 cm in length) with a normal shape, smooth peripheral margins, and normal internal architecture. There is mild loss of corticomedullary distinction. Several hyperechoic shadowing diverticular foci are observed. There is no evidence of pyelectasia, infarcts or hydronephrosis.

The right kidney is normal size (4.79 cm in length) with a normal shape, smooth peripheral margins, and normal internal architecture. There is mild loss of corticomedullary distinction. Several hyperechoic shadowing diverticular foci are observed. There is no evidence of pyelectasia, infarcts or hydronephrosis. Renal vasculature is normal.

REFERRING VET

Dr. Lee

Adrenal Glands

The left adrenal gland is normal size (0.68 cm at cranial pole) (0.61 cm at caudal pole) (1.91 cm in length); normal shape; homogenous parenchyma. The glandular echogenicity and detail are unremarkable. Capsule, cortex, and medullary definition are normal. The phrenicoabdominal vein and surrounding vasculature are normal.

INVOICE

11620kk

The right adrenal gland is normal size (0.47 cm at cranial pole) (0.67 cm at caudal pole) (1.95 cm in length); normal shape; homogenous parenchyma. The glandular echogenicity and detail are unremarkable. Capsule, cortex, and medullary definition are normal. The phrenicoabdominal vein and surrounding vasculature are normal.

Spleen

The spleen is normal in size (1.48 cm in width at the level of the hilus) with a normal capsular contour. There

is appropriate echogenicity and echotexture. No focal lesions are observed. Splenic vasculature is normal.

Liver

The liver is subjectively enlarged with rounded peripheral contours. The parenchyma is hypoechoic relative to the spleen and heterogeneous in appearance. A 6.76 x 4.71 cm isoechoic swelling/mass is observed deep on the right side. Hepatic vasculature and intrahepatic biliary tracts are of normal volume with no evidence of congestion. The gall bladder is distended. The wall is normal in thickness. A moderate to large amount of aggregated echogenic to mineralized debris/sludge, some of which is adhered and some of which is partially dependent is observed within the lumen. The cystic and common bile ducts are normal/not seen.

Gastrointestinal

The stomach and intestine are free of stasis and exhibit normal peristaltic activity. The gastric lumen is not distended. The gastric wall and pylorus are normal in thickness with a normal layering pattern. The pyloric outflow tract is patent. The small intestinal lumen is not dilated. The small intestinal wall thickness is normal with a normal layering pattern and appropriate mural detail. Discreet masses are not identified. The colonic wall is normal. No obstructive disease is noted.

Pancreas

The region of the pancreas is isoechoic relative to surrounding omental fat. No obvious parenchymal abnormalities are observed. There is no evidence of regional inflammation or effusion.

Free Abdomen

A focus of reactive mesentery is observed in the mid-abdominal cavity. No free fluid is observed. The abdominal lymph nodes are normal/not visible.

ULTRASONOGRAPHIC FINDINGS

Primary Findings:

- Large right hepatic swelling/mass. Neoplasia is the top differential with benign pathology (i.e., regenerative nodular hyperplasia) as a lower possibility. The diffuse hepatic parenchymal changes are non-specific and could be secondary to regenerative nodular hyperplasia, age-related remodeling, vacuolar hepatopathy, inflammatory disease, infiltrative neoplasia or other hepatopathy.
- The excessive gall bladder sludge could be consistent with cholestasis, fasting, or early mucocele formation.

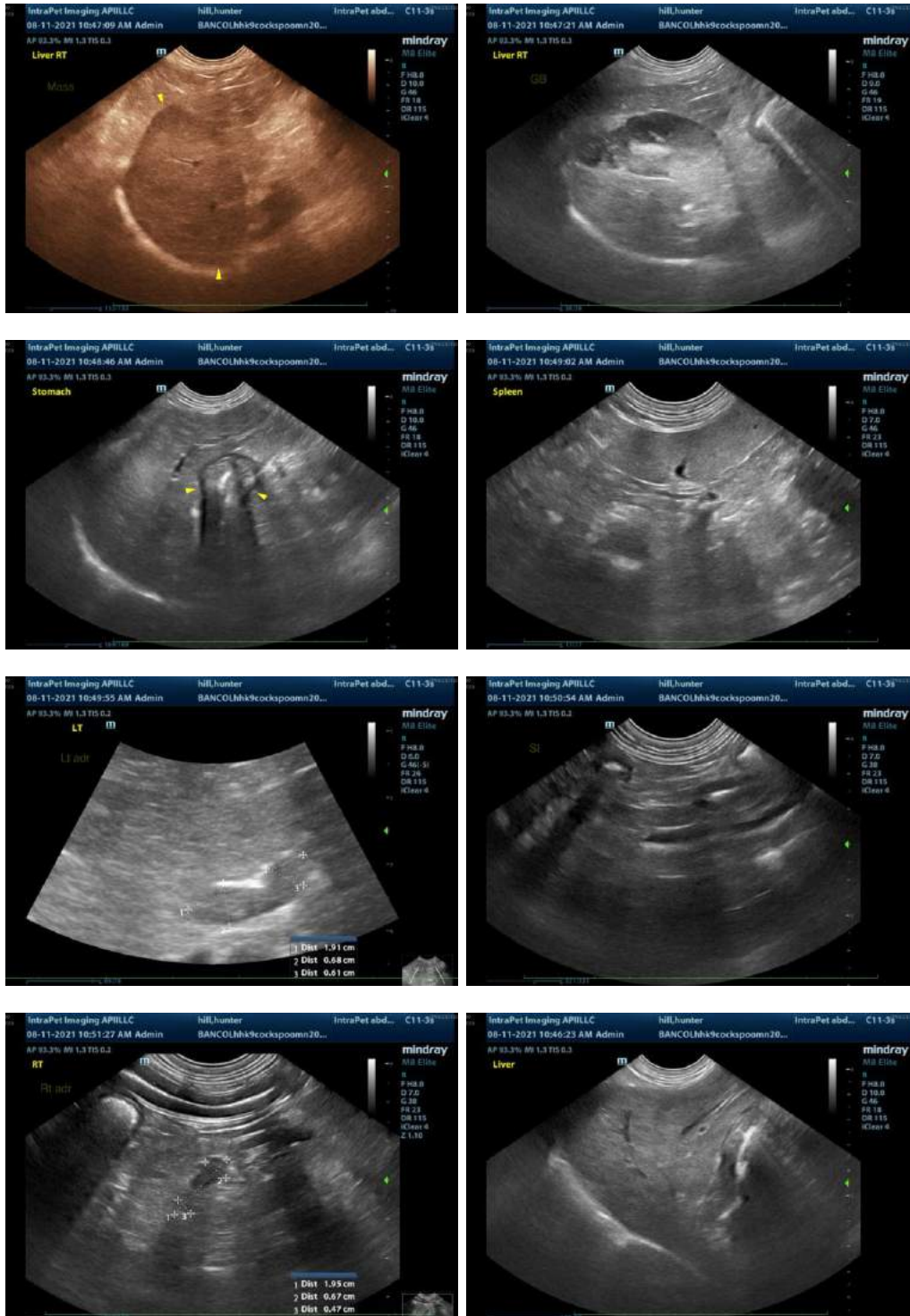
Secondary Findings:

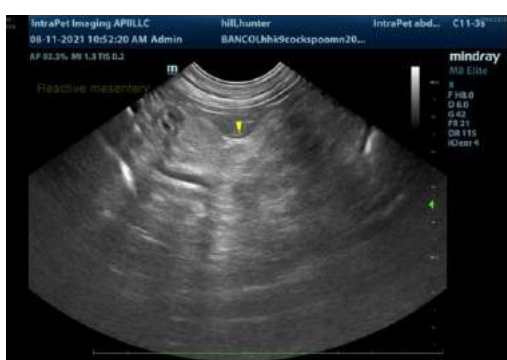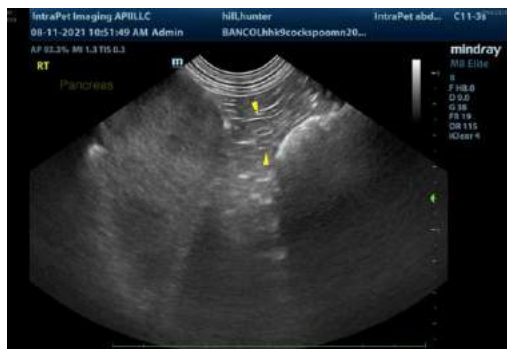
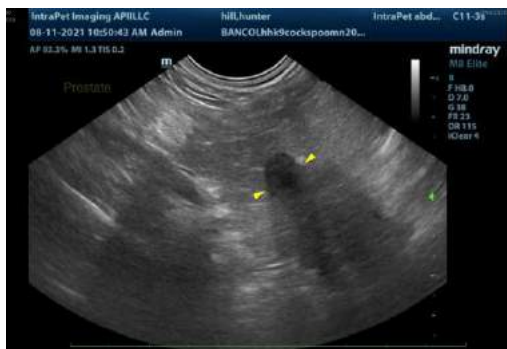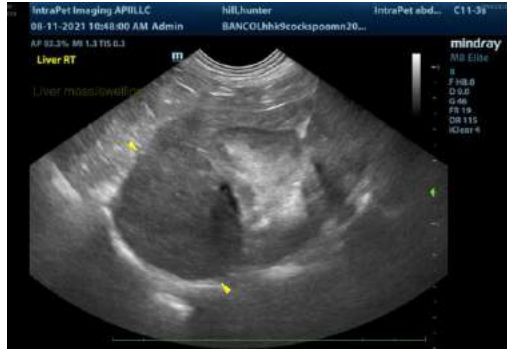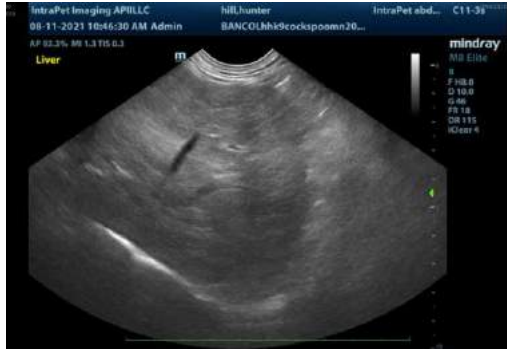- Bilateral, age-related renal pathology with dystrophic mineralization.
- The significance of the reactive mesentery in the mid-abdominal cavity is unclear but may be secondary to resolving gastrointestinal issue.

INTERPRETATION OF THE FINDINGS & FURTHER RECOMMENDATIONS

1. Three-view thoracic radiographs are recommended to assess for pulmonary metastases.
2. If accessible, a fine needle aspirate of the hepatic swelling/mass can be considered (if clotting status is appropriate). A 25-gauge needle should be used. Alternatively, surgical biopsy or removal/debulking can be considered. If surgery is pursued, referral to a board-certified surgeon is

recommended. An abdominal CT scan would be useful in -pre-surgical planning. If surgery is performed, the gallbladder should also be assessed for mucocele formation.





The information and recommendations provided are based on the images presented by the referring veterinarian. No evaluation can be communicated regarding pathology that was not visible in the image/video clips provided.

Thank you for this referral. If the clinical or image interpretation does not parallel your findings or if I can be of any further assistance, please contact me.

Andrea Nicastro, DVM, Diplomate ACVIM (*Small Animal Internal Medicine*)
Andrea.nicastro@sonopath.com