



PATIENT PRESENTING CLINICAL SIGNS

Scotty Sealand History: geriatric work up in cat w/ CKD; clinically doing well see general lab results below on hills k/d diet

SPECIES Abnormal PE/Chem/CBC/UA Results: compared to 5/2023 Chemistry SDMA 15 (0-14); was 25
 Creatinine 2 (0.9-2.3); was 2.3 BUN 20 (16-37); was 22 Triglyceride 92 (20-90) CBC Rbc 11.5 (7.12-11.46)
 Feline Retic HGB 14.4 (15.3-22.9) Platelet 82 (155-641) **moderately decreased Lymphocytes 6318 (850-5850)
BREED UA USG 1.025; was 1.030 pH 6.5 glucose, bilirubin, ketones, bacteria, crystals negative 1+ protein; was 1+
 trace blood 1+ granular casts fPL 3.1 (0-4.4) BP 90, 100, 94, 88 UPC today: <0.1

DLH

SEX

Neutered Male

AGE

13.5 years

WEIGHT

11 lbs

ULTRASONOGRAPHIC EXAMINATION OF THE ABDOMEN

Urinary System

The urinary bladder wall is normal in thickness and the mucosal surface is smooth. The bladder is mildly to moderately distended. A small amount of suspended echogenic debris is observed within the lumen. No cystic calculi are observed. The region of the trigone and visible portion of the proximal urethra are normal.

The left kidney is borderline small in size (3.18 cm in length) with a normal shape, and smooth peripheral contours. The cortex is isoechoic relative to the spleen and mildly thickened with moderate loss corticomedullary distinction. A hyperechoic medullary band is observed at the corticomedullary junction. There is no evidence of pyelectasia, nephroliths, infarcts or hydroureter.

INTERPRETED BY

Andrea Nicastro, DVM,
Diplomate ACVIM (*Small Animal Internal Medicine*)

The right kidney is borderline small in size (3.13 cm in length) with a normal shape, and smooth peripheral contours. The cortex is isoechoic relative to the spleen and mildly thickened with moderate loss corticomedullary distinction. A hyperechoic medullary band is observed at the corticomedullary junction. There is no evidence of pyelectasia, nephroliths, infarcts or hydroureter.

IMAGING PERFORMED BY

Christina Sitton

Adrenal Glands

The left adrenal gland is normal in size (0.31 cm width). Normal shape and glandular echogenicity. The phrenicoabdominal vein and surrounding vasculature appear normal.

The region of the right adrenal gland is evaluated. No obvious pathology is observed.

HOSPITAL NAME

Sherwood Family PC

Spleen

The spleen is normal in size (0.73 cm in width at the level of the hilus) with a normal capsular contour. There is appropriate echogenicity and echotexture. No focal lesions are observed. Splenic vasculature appears normal.

REFERRING VET

Christina Sitton

Liver

The liver is subjectively normal in size with normal curvilinear peripheral contours. The parenchyma is hyperechoic relative to the spleen and diffusely homogeneous in appearance. No distinct focal lesions are observed. Vascular and biliary tracts are of normal volume with no evidence of congestion.

INVOICE

14026

The gall bladder lumen is moderately distended. The wall is thin and smooth. Luminal contents are anechoic. The cystic and common bile ducts are normal/not seen.

DATE

8.10.23

Gastrointestinal

The stomach and intestine are free of stasis and exhibit normal peristaltic activity. The gastric lumen is not distended. The gastric wall and pylorus are normal in thickness with a normal layering pattern. The pyloric outflow tract is patent. The small intestinal lumen is not dilated. The small intestinal wall is normal in thickness with a normal layering pattern and appropriate mural detail. Discreet masses are not identified. The colonic wall is normal. There is no evidence of an obstructive pattern.



PATIENT *Pancreas*

Scotty Sealand The region of the pancreas is isoechoic relative to surrounding omental fat. No obvious parenchymal abnormalities are observed. There is no evidence of regional inflammation or effusion.

SPECIES *Free Abdomen*

Feline The peritoneal cavity is normal. There is no evidence of inflammation or effusion. The abdominal lymph nodes are normal/not visible.

BREED

DLH

SEX

Neutered Male

AGE

13.5 years

WEIGHT

11 lbs

INTERPRETED BY

Andrea Nicastro, DVM,
Diplomate ACVIM (*Small Animal Internal Medicine*)

IMAGING PERFORMED BY

Christina Sitton

HOSPITAL NAME

Sherwood Family PC

REFERRING VET

Christina Sitton

INVOICE

14026

DATE

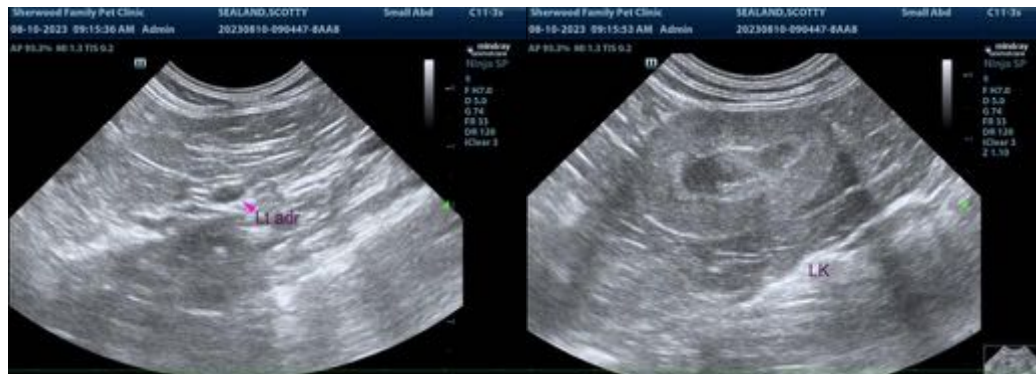8.10.23

ULTRASONOGRAPHIC FINDINGS

- Bilateral chronic nonspecific age-related renal changes

INTERPRETATION OF THE FINDINGS & FURTHER RECOMMENDATIONS

- Given the renal changes, consider the following:
 1. Urine culture and sensitivity
 2. Baseline blood pressure measurement
 3. Transitioning to a prescription renal diet ((if the patient will tolerate it))
 4. Serial monitoring (i.e., every 3-4 months) of the patient's kidney values to assess for further increases
- Regarding the lymphocytosis, consider the following:
 1. Feline leukemia and FIV testing
 2. Clinical pathology review of the CBC
 3. Three-view thoracic radiographs to assess for lymphadenopathy in the chest





PATIENT

Scotty Sealand

SPECIES

Feline

BREED

DLH

SEX

Neutered Male

AGE

13.5 years

WEIGHT

11 lbs

INTERPRETED BY

Andrea Nicastro, DVM,
Diplomate ACVIM (*Small Animal Internal Medicine*)

IMAGING PERFORMED BY

Christina Sitton

HOSPITAL NAME

Sherwood Family PC

REFERRING VET

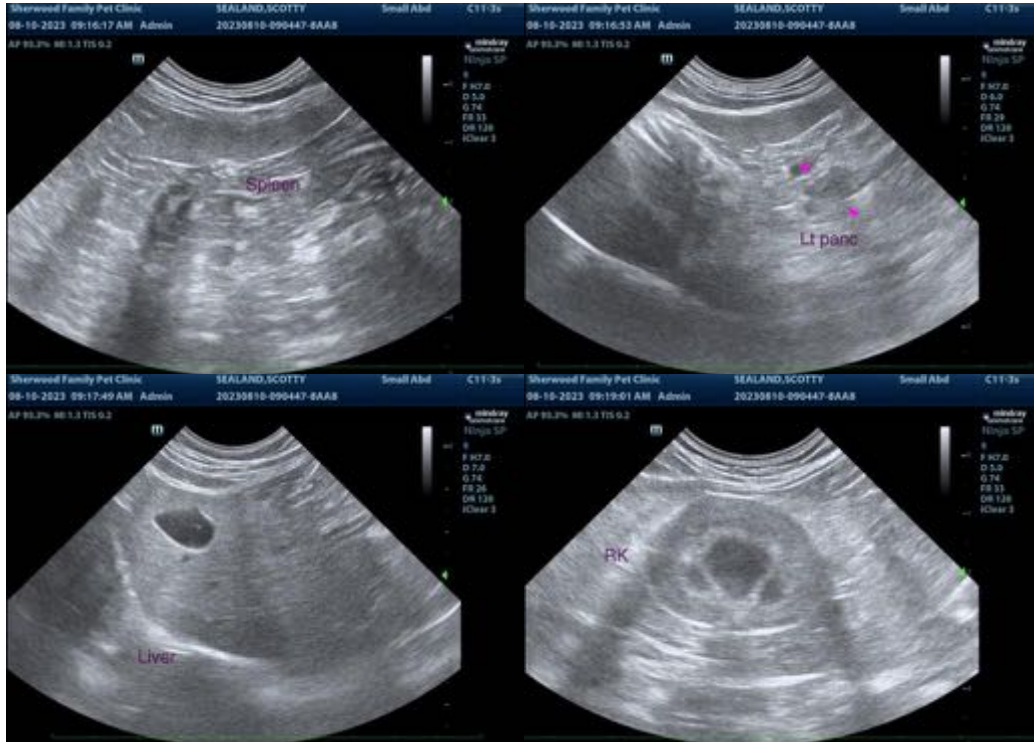
Christina Sitton

INVOICE

14026

DATE

8.10.23



The information and recommendations provided are based on the images presented by the referring veterinarian/sonographer. No evaluation can be communicated regarding pathology that was not visible in the image/video clips provided.

Thank you for this referral. If the clinical or image interpretation does not parallel your findings or if I can be of any further assistance, please contact me.

Andrea Nicastro, MPH, DVM, Diplomate DACVIM (Small Animal Internal Medicine)
info@SonoPath.com